

# Ultrasonographic Imaging to Monitor Early Pregnancy in the Camel (*Camelus dromedarius*)

Sumant Vyas<sup>1\*</sup> G.N. Purohit<sup>2</sup>  
P.K. Pareek<sup>2</sup> M.S. Sahani<sup>1</sup>

## Key words

*Camelus dromedarius* – Bikaneri dromedary – Echography – Fetus – Pregnancy diagnosis – Reproduction – India.

## Summary

Six female one-humped camels of Bikaneri breed were mated with virile studs when follicles equal to or larger than 9 mm in diameter could be observed ultrasonographically. Real time B-mode ultrasound was used to detect and monitor the early conceptus, its growth and anatomical features between days 18 and 40 postmating. The embryonic vesicle and embryo proper within the vesicle were first visible on days 18 and 23 postmating, respectively. The heartbeat of the embryo proper could be detected on day 30. The allantois and amnion were first identified on day 40. The optic area was first identified on day 40 postmating. The ultrasonography method can help to identify pregnant or nonpregnant she-camels as early as day 20 of pregnancy, the results being available instantaneously.

## INTRODUCTION

One of the main problems for the improvement of one-humped camel production is the low reproductive efficiency of the species. Among factors influencing the reproductive performance are seasonal breeding, late maturity and long intercalving periods (10, 30).

The breeding season of female camels in India is of short duration (three months, December to February) (15) and therefore necessitates the identification of nonpregnant females in order to rebreed them with least possible delay. Non-return to estrus as well as reproductive tract palpation have been the common methods employed by skilled veterinarians and practitioners for pregnancy diagnosis in cattle and buffalo. However, returns to service are difficult to detect in camels due to their induced ovulatory nature and absence of true estrus, and the delay of 60 to 70 days for detection of pregnancy by rectal palpation (19) are the major disadvantages of using these two methods in the camel.

Accurate detection and monitoring of pregnancy status is important for successful management of fertility on the farm. Plasma progesterone assay is often the method of choice for early detection of pregnancy, but it requires radioimmunoassay laboratory or ELISA equipment, sampling at a given time, and the

results are not available instantaneously (8, 29). Real-time B-mode ultrasonography has been used recently to detect pregnancy in cattle (8, 9), mare (13) and buffalo (21). More work has been carried out in South American Camelidae, like llama and alpaca (1, 5, 11, 18, 20), than in the dromedary (one-humped) camel (22, 25). The objective of the present experiment was to assess the use of linear array real time B-mode ultrasound for the detection of early pregnancy in the one-humped camel.

## MATERIALS AND METHODS

### Experimental animals

Six adult one-humped female camels of Bikaneri breed that belonged to the herd of the National Research Centre on Camels, Bikaner, and calved at least once were used in the study. The camels were clinically healthy and were provided with adequate nutrition in accordance with standard farm practices. The mean ( $\pm$  SE) weight of camels at the beginning of the experiment was  $526.3 \pm 19.1$  kg and the mean height at withers was  $196 \pm 1.6$  cm. The experimental female camels were kept in loose but under intensive management conditions during the experiment period. They were confined in a camel yard, were offered ration once daily and were taken out once daily for watering. Female camels were mated with virile studs when follicles equal to or larger than 9 mm in diameter were observed ultrasonographically (23).

### Ultrasound examination

The ultrasound scanner used for the study was Scanner-200 Vet (Pie-Medicals Equipment BV, Phillips G 2227 AJ, Maastricht, The Netherlands). As per instructions of the manufacturer, contrasts

1. National Research Centre on Camel, PB 07, Bikaner 334001, India  
2. Department of Animal Reproduction, Gynecology and Obstetrics, College of Veterinary and Animal Science, Bikaner 334001, India  
\* Corresponding Author  
Tel.: 91 151 231944; fax: 91 151 230183; e-mail: sumantv@scientist.com

and gains were adjusted to obtain a clear image with good resolution. The machine was placed on a movable trolley at appropriate level for easy visibility of the operator and to make controls of machine approachable to the operator during scanning.

Ultrasound examination of internal genitalia was attempted in sitting position as described previously (28). The she-camel was restrained in sternal recumbent posture on ground with all four legs tightly fastened using ropes. Injectable Xylazine (xylazine, Indian Immunologicals, India), 80-120 mg was administered intravenously which induced sufficient sedation for examination within 5 min and the effect lasted for 30 min. The rectum was evacuated of all feces before insertion of the transducer. The active surface of the transducer (where piezoelectric crystals are located) was lubricated with gel and inserted by a cupped, lubricated hand through anal opening, before progressing cranially along the rectal floor to overlie the reproductive tract. The lubricated face of the transducer was pressed firmly towards the ventral rectal wall to ensure the transmission of ultrasound waves through rectal mucosa into pelvic and abdominal viscera. The urinary bladder was recognized immediately as homogenous anechoic, i.e. completely black and taken as landmark for genital tract ultrasonography. As the transducer face was moved cranially along the rectal floor, beyond the urinary bladder, the uterus was imaged, as it lies ventrally to the rectum. When the transducer was moved laterally and slightly downward by changing its angle in the rectum, the uterine horns appeared in cross-section to oblique section.

The female camels were scanned ultrasonographically on days 18, 20, 23, 30 (six camels) and 40 (three camels) postmating. The observations were recorded on a videocassette recorder interfaced with the scanner. The first detection of the embryonic vesicle, embryo proper, heartbeats, allantois and amnion were recorded.

■ RESULTS

The conceptus was recognized at day 18 postmating as a typical “black hole” type of fluid accumulation in the lumen of the left uterine horn depending upon the angle of contact of the ultrasound curtain with the uterus. It appeared as discrete and roughly spherical in cross-section (Figure 1), and it was irregular and elongated when the ultrasound beam transected the uterine horn tangentially. In one she-camel, the examination was done on day 20. The conceptus was found to be considerably elongated and appeared as a discrete and easily recognized accumulation of conceptus fluids (Figure 2). Its diameter and outline varied appreciably in different parts of the uterine horn. These changes were caused mainly by endometrial folds indenting the conceptus at odd places and by fluid movement within the conceptus while carrying out the examination.

At day 23 postmating the diameter of the nonechogenic conceptus fluid accumulation in the left uterine horn was found to be increased to 2.9 cm (Figure 3) and the diameter became more uniform along the length of the horn. The embryo itself was first recognizable at this stage as a small echogenic “blob” inside the conceptus, which was apparently attached closely to the endometrium in the ventral region of the uterus.

At day 30 postmating, the overall diameter of the conceptus increased more rapidly due to accumulation of fetal fluids. The echoic embryo was imaged lying slightly ventrally within the anechoic luminal center of the echoic uterine cross-sectional image. As pregnancy advanced the echogenic embryo within the fluid became more prominent as it enlarged steadily and it appeared to detach itself progressively from the uterine wall (Figure 4).

By day 40 postmating the endometrium was found raised in irregular manner (folds) throughout its length. A division was observed occasionally between the amniotic fluid surrounding the fetus and the much larger volume of allantoic fluid external to this. The amniotic fluid seemed to contain echogenic debris, whereas the allantoic fluid was much cleaner and anechoic (Figure 5).

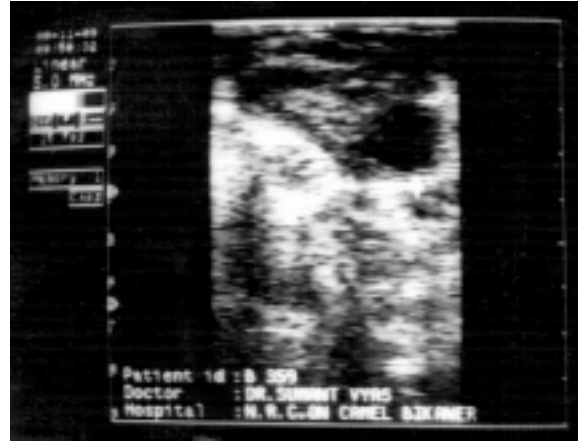

Figure 1: Ultrasonogram of uterus showing anechoic embryonic vesicle (day 18 postmating); cross-sectional view.

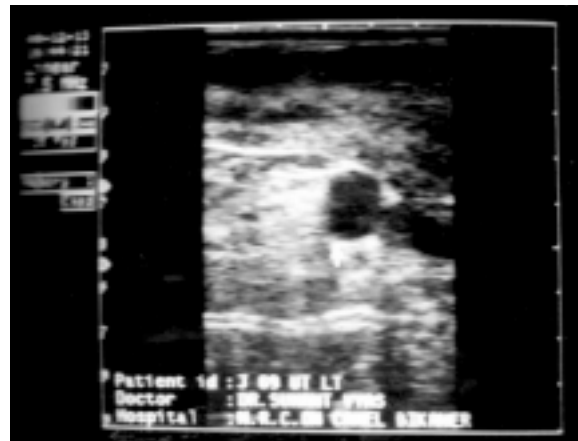

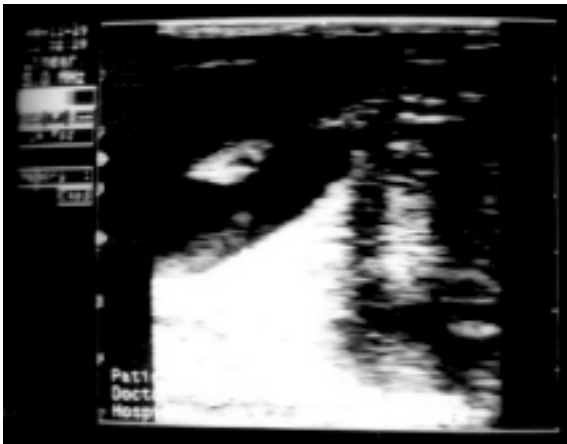
Figure 2: Ultrasonogram of uterus showing elongated embryonic vesicle (day 20 postmating); cross-sectional view.

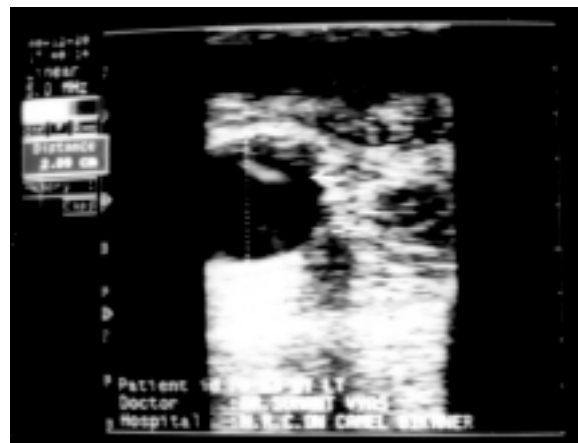

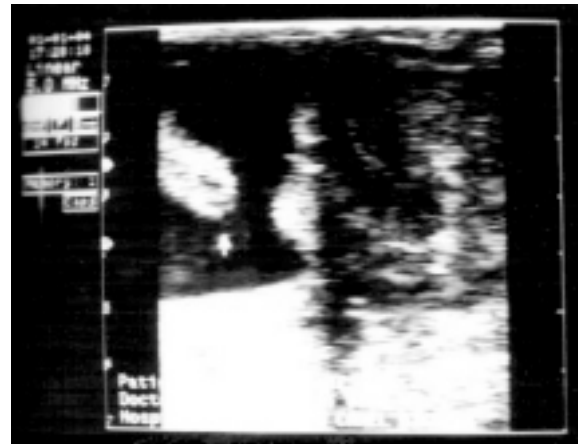
Figure 3: Ultrasonogram of uterus showing large embryonic vesicle (2.89 cm, day 23 postmating), embryo proper visible; transducer was placed on ventro-lateral aspect of left horn.

The fetus was easily recognizable as having identifiable features by day 40 postmating. The head, trunk and limb regions were clearly visible (Figure 6). The optic area was imaged as a nonechogenic or anechoic spot in the head region (Figure 7). The ultrasonographic appearance of the fetus and fetal parts depended greatly on the orientation of the fetus and that of the transducer. Figures 5 to 9 depict

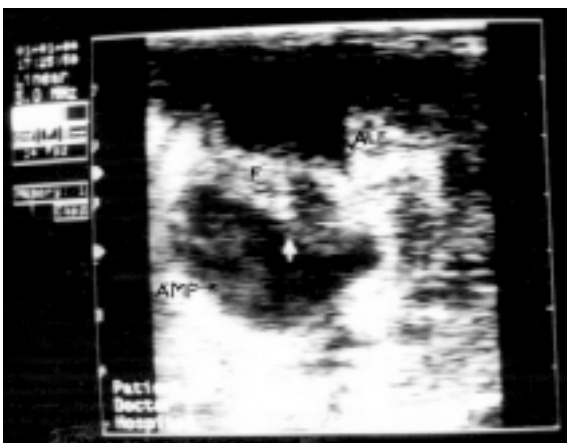the ultrasonographic images from the same uterine horn of a she-camel being examined on day 40 postmating. This clearly indicated that at day 40 postmating, accuracy of fetal parts identification and measurement was difficult and influenced by the animal movement, uterine horn, conceptus fluid, positioning of the transducer and the plane of the ultrasound wave cutting across the uterus.



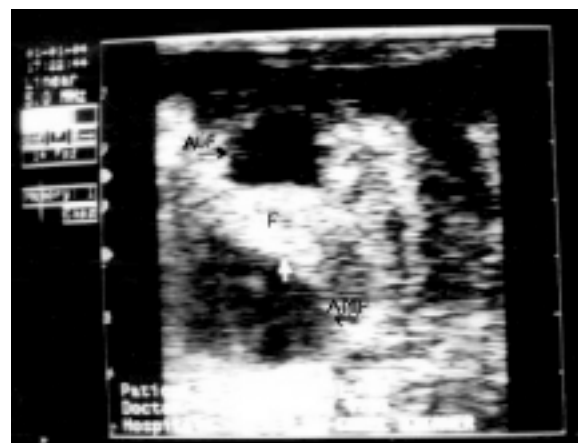**Figure 4:** Ultrasonogram of uterine horn (day 30 postmating) showing suspended embryo, cardiac region (black, anechoic spot) within the embryo proper is visible.



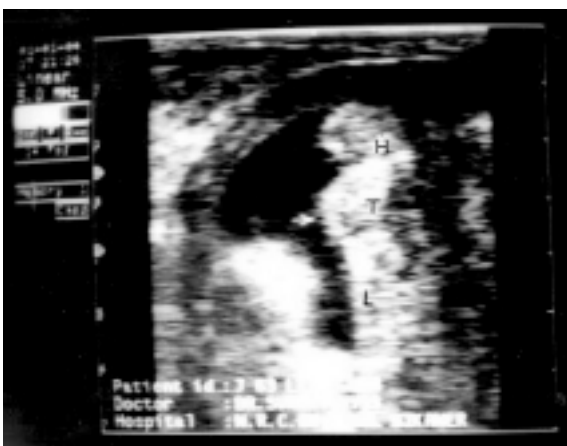**Figure 7:** Ultrasonogram of day 40 postmating showing optic area (anechoic spot in head region) of fetus.



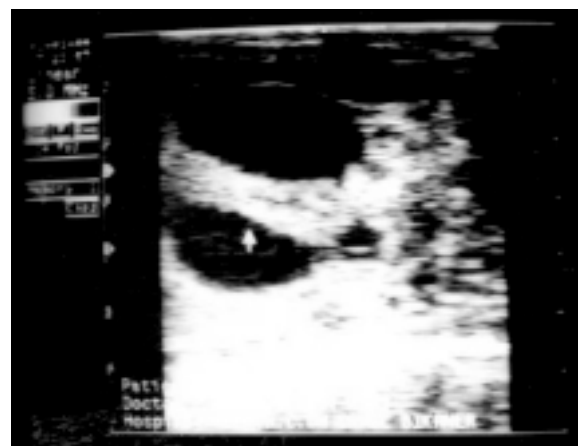**Figure 5:** Ultrasonogram of day 40 postmating showing amniotic fluid (AMF, slightly echogenic), allantoic fluid (ALF, anechoic) and cardiac region (anechoic spot in echogenic fetus, F).



**Figure 8:** Ultrasonogram of day 40 postmating showing fetus (F), amniotic fluid (AMF, slightly echogenic) and allantoic fluid (ALF, clear anechoic).



**Figure 6:** Ultrasonogram of day 40 postmating showing three distinct fetal parts (H = head, T = trunk, L = limb region) and optic area (anechoic spot in head region).



**Figure 9:** Ultrasonogram of day 40 postmating showing echogenic fetus.

The small hypoechoic dot within the embryo's image observed on day 30 postmating was the region of the embryonic heart (Figure 4). At day 30 postmating the embryonic heartbeat was discernible in real time as a rapid rhythmical fluttering movement in the cardiac region located in the center of the echogenic embryo. In the present study, the heartbeat was counted for 15 s and then multiplied by 4 to take the values of beats per minute. The heartbeat mean values on days 30 and 40 were  $202.7 \pm 3.5$  and  $174.7 \pm 3.5$  beats/min, respectively.

The corpus luteum is the major source of progesterone during pregnancy in one-humped camels and its presence is required throughout the gestation period. Therefore, in the present study, ultrasonographic visualization of the corpus luteum was also taken, which added to the accuracy of the early pregnancy diagnosis. The corpus luteum of pregnancy was observed to be larger in diameter, and it was observed to have a central hypoechoic or nonechoic fluid filled area on days 20, 30 and 40 postmating.

The ultrasonographic examination on days 20, 30 and 40 postmating for early pregnancy diagnosis revealed pregnancy in three out of six females that were mated with virile studs. In all three cases conceptus was found in the left horn.

## ■ DISCUSSION

Ultrasonography is a noninvasive powerful tool for early pregnancy diagnosis, fetal heart rate and placental development in the human (4), as well as in domestic animals like cattle (8, 9), mares (13), goats (29), sheep (12), pigs (17), llamas and alpacas (11, 18, 20).

Ultrasound technology can also prove to be a reliable tool for detecting a conceptus as early as day 20 postmating in the camel, since return to service is difficult to detect in the camel, due to lack of definite estrous cycle and less obvious external signs of estrus. Some information is available in the literature regarding the early detection of camel embryo and fetal cardiac activity (24). The present study was therefore carried out to detect early pregnancy and cardiac activity of one-humped camel conceptus.

It was shown in the present investigation that ultrasonographic examination allowed accurate diagnosis of pregnancy in the dromedary camel at a much earlier stage of gestation than was possible by palpation alone. The first discrete accumulation of fetal fluids in the uterine lumen was visible by day 18 postmating. Observations by real time ultrasound of the pregnant she-camel allowed for the visualization of the embryonic vesicle on day 18. The vesicle was first spherical and became elongated and irregular in shape after day 23. However, when the transducer was placed on ventro-lateral aspect of the horn, the embryonic vesicle was visible as spherical. Definite diagnosis of pregnancy could be made based on the accumulated fetal fluids and echogenic embryo with its pulsatile heart by day 30 postmating. Similar results but with early diagnosis of fetus on day 20 postovulation (25, 26) and day 23 postovulation (23) were reported earlier. The time elapsed between mating and ovulation in camel is 24 to 36 h (16). Therefore, there was not much difference in days of first detection of the embryo proper in the present study compared to earlier reports. However, this was at least 30 days before pregnancy in she-camel can be diagnosed confidently by rectal palpation (3, 19).

The fetal heart and heart rates were observed on day 30. The estimated fetal heart rate was  $202.6 \pm 3.5$  beats/min on the day of first detection (day 30 postmating). This was similar to the heart rate measured in buffalo (203 beats/min; 21), but faster than the ultrasonically measured heart rate in the bovine

embryo (188 beats/min; 14). The heart rate decreased to  $174.7 \pm 3.5$  beats/min on day 40, which was similar to the decrease found in the fetal heart rate measured in the mare (7) and the cow (9).

In the present investigation, the amniotic fluid owing to presence of slightly echogenic debris could be discerned easily from the allantoic fluid, which was very clear, larger in volume and completely nonechoic. But the echogenic amniotic band surrounding the fetus, which is characteristic of bovine (6) and buffalo fetuses (21) throughout the gestation, was not observed in the present study. However the present findings were similar to earlier reports (22, 24, 26) that did not mention an echogenic amniotic ring or band around camel conceptus.

On day 40 postmating, the fetal head, trunk and limbs were easily discernible. The optic area was a nonechogenic spherical structure and was observed on day 40 postmating. This area was surrounded by an echogenic bony socket. The nonechogenic structure might perhaps have been due to the presence of the optic lens. Similar observations were also reported in cattle (27) and buffalo (21).

Although both ovaries function almost equally, it was revealed by ultrasonographic examination in the present study that all pregnancies were located in the left horn. Embryonic migration from the right to the left uterine horn in she-camel is common and always seems to occur when the right ovary ovulates and the left ovary does not (2).

## ■ CONCLUSION

Early detection of embryo plays an important role in camel breeding because return to service are difficult to detect due to lack of definite estrous cycle and less obvious external signs of estrus. Therefore, a noninvasive method of early pregnancy diagnosis with ultrasound would greatly help to identify nonpregnant she-camels as early as day 20.

## REFERENCES

1. ALARCON V., SUMAR J., RIERA G.S., FOOTE W.C., 1990. Comparison of three methods of pregnancy diagnosis in Alpacas and Llamas. *Theriogenology*, **34**: 1119-1127.
2. ARTHUR G.H., 1992. An overview of reproduction in the camelids. In: Allen W.R. *et al.* Eds, Proc. First int. Camel Conf., Dubai, United Arab Emirates, 2-6 February 1982. Newmarket, UK, R. & W. Publications, p. 109-113.
3. BANERJEE S.P., VYAS K.K., PAREEK P.K., DEORA K.S., VYAS U.K., 1981. Note on clinical diagnosis of early pregnancy in camel. *Indian J. Anim. Sci.*, **51**: 909-910.
4. BIRNHOLZ J.C., FARREL E.E., 1984. Ultrasound images of human fetal development. *Am. Sci.*, **72**: 608-613.
5. BOURKE D.A., ADAM C.L., KYLE C.E., 1992. Ultrasonography as an aid to controlled breeding in the llama (*Lama glama*). *Vet. Rec.*, **130**: 424-428.
6. BOYD J.S., 1995. Real-time diagnostic ultrasound in bovine reproduction. In: Goddard P.J. Ed., Veterinary ultrasonography. Wallingford, UK, CAB International, p. 233-257.
7. CURRAN S., GINTHER O.J., 1995. M-mode ultrasonic assessment of equine fetal heart rate. *Theriogenology*, **44**: 609-617.
8. CURRAN S., PIERSON R.A., GINTHER O.J., 1986. Ultrasonographic appearance of the bovine conceptus from days 10 through 20. *J. Am. vet. Med. Assoc.*, **189**: 1289-1292.
9. CURRAN S., PIERSON R.A., GINTHER O.J., 1986. Ultrasonographic appearance of the bovine conceptus from days 20 through 60. *J. Am. vet. Med. Assoc.*, **189**: 1295-1302.

10. DJELLOULI M.S., SAINT-MARTIN G., 1992. Productivity and economy of camel breeding in Tunisia. In: Allen W.R. et al. Eds, Proc. First int. Camel Conf., Dubai, United Arab Emirates, 2-6 February 1982. Newmarket, UK, R. & W. Publications, p. 209-212.
11. GAZITUA F.J., CORRADINI C., FERRANDO G., RAGGI L.A., VICTOR H.P., 2001. Prediction of gestational age by ultrasonic fetometry in llama (*Lama glama*) and alpacas (*Lama pacos*). *Anim. Reprod. Sci.*, **66**: 81-92.
12. FOWLER D.G., WILKINS J.C., 1984. Diagnosis of pregnancy and number of fetuses in sheep by real-time ultrasound imaging. I. Effect of number of fetuses, stage of gestation, operator and breed of ewes on accuracy of diagnosis. *Livest. Prod. Sci.*, **11**: 437-450.
13. GINTHER O.J., 1983. Mobility of the early equine conceptus. *Theriogenology*, **19**: 603-609.
14. KASTELIC J.P., CURRAN S., PIERSON R.A., GINTHER O.J., 1988. Ultrasonic evaluation of the bovine conceptus. *Theriogenology*, **29**: 39-54.
15. KHANNA N.D., TANDON S.N., RAI A.K., 1990. Breeding parameters of Indian camels. *Indian J. Anim. Sci.*, **60**: 1347-1354.
16. MARIE M., ANOUASSI A., 1986. Mating induced luteinizing hormone surge and ovulation in the she-camel (*Camelus dromedarius*). *Biol. Reprod.*, **35**: 792-798.
17. MARTINAT-BOTTE F., RENAUD G., MADEC F., COSTIOU P., TERQUI M., 1998. Echographie et reproduction chez la truie. Paris, France, Inra/Hoechst Vet, p. 104.
18. MIALOT J.P., VILLEMAIN L., 1994. Ultrasonic diagnosis of gestation in the llama and alpaca. *Recl Méd. vét.*, **170**: 23-27.
19. MUSA B.E., ABUSINEINA M.E., 1978. Clinical pregnancy diagnosis in the camel and a comparison with bovine pregnancy. *Vet. Rec.*, **102**: 7-10.
20. PARRAGUEZ V.H., CORTEZ S., GAZITUA F.J., FERRANDO G., MACNICEN V., RAGGI L.A., 1997. Early pregnancy diagnosis in alpaca (*Lama pacos*) and llama (*Lama glama*) by ultrasound. *Anim. Reprod. Sci.*, **47**: 113-121.
21. PAWSHE C.H., APPARAO K.B.C., TOTEY S.M., 1994. Ultrasonographic imaging to monitor early pregnancy and embryonic development in buffalo (*Bubalus bubalis*). *Theriogenology*, **41**: 697-709.
22. SKIDMORE J.A., BILLAH M., ALLEN W.R., 1992. Ultrasonographic and video-endoscopic monitoring of early fetal development in the dromedary camel. In: Allen W.R. et al. Eds, Proc. First int. Camel Conf., Dubai, United Arab Emirates, 2-6 February 1982. Newmarket, UK, R. & W. Publications, p. 193-201.
23. SKIDMORE J.A., BILLAH M., ALLEN W.R., 1996. The ovarian follicular wave pattern and induction of ovulation in the mated and non-mated one-humped camel (*Camelus dromedarius*). *J. Reprod. Fertil.*, **106**: 185-192.
24. TIBARY A., ANOUASSI A., 1996. Ultrasonographic changes of the reproductive tract in the female camel (*Camelus dromedarius*) during the follicular cycle and pregnancy. *J. Camel Prac. Res.*, **3**: 71-90.
25. TIBARY A., ANOUASSI A., 1997. Theriogenology in Camelidae: anatomy, physiology, pathology and artificial breeding, 1st Edn. Dubai, United Arab Emirates, Ministry of Culture and Information, p. 281-286.
26. TINSON A.H., MCKINNON A.O., 1992. Ultrasonography of the reproductive tract of the female dromedary camel. In: Allen W.R. et al. Eds, Proc. First int. Camel Conf., Dubai, United Arab Emirates, 2-6 February 1982. Newmarket, UK, R. & W. Publications, p. 129-135.
27. TOTEY S.M., SINGH G., TANEJA M., TALWAR G.P., 1991. Ultrasonography for detection of early pregnancy following embryo transfer in unknown breed of Bos indicus cow. *Theriogenology*, **35**: 487-497.
28. VYAS S., SAHANI M.S., 2000. Real time ultrasonography of ovaries and breeding of the one-humped camel (*Camelus dromedarius*) during the early postpartum period. *Anim. Reprod. Sci.*, **59**: 179-184.
29. WANI G.M., 1987. Ultrasonographic pregnancy diagnosis in sheep and goats. *World Rev. Anim. Prod.*, **23**: 43-48.
30. WILSON R.T., 1989. Reproductive performance of the one humped camel. The empirical base. *Revue Elev. Méd. vét. Pays trop.*, **42**: 117-125.

Accepté le 19.09.2003

## Résumé

**Sumant Vyas, Purohit G.N., Pareek P.K., Sahani M.S.** Imagerie ultrasonographique pour le suivi du stade précoce de gestation chez le dromadaire (*Camelus dromedarius*)

Six femelles dromadaires de race Bikaneri ont été saillies par des mâles reproducteurs lorsque des follicules de dimension égales ou supérieures à 9 mm ont pu être observés par échographie. L'échographie en mode B et en temps réel a été utilisée pour détecter le très jeune embryon et assurer le suivi de son développement, de sa croissance et de ses caractéristiques anatomiques entre les 18<sup>e</sup> et 40<sup>e</sup> jours après la monte. La vésicule embryonnaire et l'embryon proprement dit à l'intérieur de la vésicule ont été visibles respectivement aux 18<sup>e</sup> et 23<sup>e</sup> jours après la monte. Les pulsations cardiaques de l'embryon lui-même ont pu être détectées au 30<sup>e</sup> jour. L'allantoïde et l'amnios ont été identifiés pour la première fois au 40<sup>e</sup> jour. La zone optique a également été identifiée pour la première fois au 40<sup>e</sup> jour après la monte. La méthode ultrasonographique peut permettre d'identifier l'état gravide ou non gravide des femelles dromadaires dès le 20<sup>e</sup> jour de gestation et les résultats obtenus par cette méthode sont connus dans l'instant même.

**Mots-clés :** *Camelus dromedarius* – Dromadaire Bikaneri – Echographie – Foetus – Diagnostic de gestation – Reproduction – Inde.

## Resumen

**Sumant Vyas, Purohit G.N., Pareek P.K., Sahani M.S.** Imágenes ultrasonográficas para el monitoreo de la preñez precoz en el dromedario (*Camelus dromedarius*)

Seis hembras dromedarias (de una giba) de la raza Bikaneri se reprodujeron con machos viriles, al observar, mediante ultrasonografía, folículos iguales o mayores a 9 mm de diámetro. Se utilizó un ultrasonido de tiempo real de modo B para detectar y monitorear el concepto temprano, su crecimiento y características anatómicas, entre los días 18 y 40 post copulación. La vesícula embrionaria y el embrión en sí dentro de la vesícula, fueron visibles por primera vez al día 18 y 23 post copulación respectivamente. Las palpaciones del embrión fueron detectadas al día 30. El alantoides y el amnios fueron identificados por primera vez al día 40. El área óptica se identificó primero al día 40 post copulación. El método de ultrasonografía puede ayudar a identificar dromedarias preñadas o no a partir del día 20 de gestación, con resultados accesibles instantáneamente.

**Palabras clave:** *Camelus dromedarius* – Dromedario Bikaneri – Ecografía – Feto – Diagnóstico de la gestación – Reproducción – India.