

Bacteriological and Pathological Study on Pneumonia in the One-Humped Camel (*Camelus dromedarius*) in Jordan

Y.H. Al-Tarazi¹

Key words

Camelus dromedarius - Pneumonia - Gram-positive bacteria - Gram-negative bacteria - Histopathology - Jordan.

Summary

In general, literature about camel pneumonia is scarce. In this study, 284 lungs of slaughtered camels (6 months to 10 years of age) from northern Jordan were examined. Pneumonia prevalence was 10.2%. Pathological lesions of pneumonic lungs showed the presence of chronic proliferative bronchopneumonia, chronic pleuropneumonia and interstitial pneumonia. Lung abscesses were also recorded. Chronic proliferative bronchopneumonia (20.69%) and chronic pleuropneumonia (6.9%) were more frequent in older camels (about 10 years of age), while interstitial pneumonia (58.6%) and lung abscesses (10.34%) were more frequent in young camels (6 months to 4 years of age). *Mannheimia haemolytica* and *Pseudomonas aeruginosa* were the most frequent isolates from cases of chronic proliferative bronchopneumonia and chronic pleuropneumonia, while *Escherichia coli* and *Klebsiella* spp. were the most frequent isolates from cases of interstitial pneumonia. *Staphylococcus aureus*, *Actinomyces pyogenes* and hemolytic streptococci were the most frequent isolates from lung abscess cases. A total of 75 bacterial isolates were collected from the 29 pneumonic lungs. The most frequent were *E. coli* (26.66%), *Klebsiella* spp. (14.66%), *Pseudomonas aeruginosa* (12%), *Staphylococcus aureus* (10.66%), *Mannheimia haemolytica* (6.66%) and *Actinomyces pyogenes* (6.66%). *Klebsiella ozaenae* was the most frequent among the *Klebsiella* species identified.

■ INTRODUCTION

The one-humped camel is widely distributed in the Horn of Africa, North African countries, the Arab peninsula and some countries of Asia. In Jordan, the population of dromedary camels is around 18,000. Bedouin use them as a means of transportation in the desert; they can also be used for tourism or reared for production of meat, milk, hair or hide (16).

Lung infections, especially pneumonia, are major diseases of domestic animals. Outbreaks occur in camel, cattle, buffaloes and small ruminants in various countries (13, 25, 26). Pneumonia may be caused by bacteria, mycoplasmas, viruses, parasites and fungi (5, 25).

Rearing systems, stress factors, climatic changes, unhygienic conditions, sudden changes in feed and a low level herd health status were stated as predisposing factors to bacterial and viral

pneumonia. In camels, pneumonia outbreaks are usually observed during the change from the dry to the rainy season (5, 17, 19, 25, 27). Only few studies were found in the available literature on pathological and bacteriological affections of pneumonic lungs in camels. Most of the studies on camels were about parasitic infections (7, 12, 22). In Jordan, only one study on camel diseases was available (6). Therefore, the objective of this work was to study the etiology (bacterial) as well as histopathological findings of pneumonia in camels in the northern part of Jordan.

■ MATERIALS AND METHODS

From July 2000 to February 2001 (summer and winter), 284 lungs of one-humped camels (6 months to 10 years old) slaughtered at Ramtha abattoir (75 km north of Amman) were grossly examined for the presence of pneumonic lesions. Tissues from apparently affected lungs were collected and divided into two portions. One portion (7 x 10 x 10 mm) was fixed in 10% neutral buffered formalin for histopathological examination. Tissue blocks were processed using standard procedures. Sections 5- μ m thick were stained with hematoxylin-eosin and examined microscopically (9). The other portion was placed in sterile plastic bags, kept in an icebox and subjected to bacteriological examination within two hours of collection. Ten apparently healthy lungs were also

1. Department of Basic Veterinary Medical Sciences, Faculty of Veterinary Medicine, Jordan University of Science and Technology, PO Box 3030, Irbid, Jordan
Tel: +962 2 720 10 00; Fax: +962 2 709 51 23; E-mail: tarazi@just.edu.jo

bacteriologically examined. The lung specimens were immersed in alcohol and flamed. A sharp incision was made in the lesion with a sterile blade. A full loop was taken from the lesion and inoculated on 5% sheep blood agar (DIFCO) and MacConkey agar (DIFCO). The inoculated plates were incubated at 37°C for 24-48 hrs. Growing colonies were picked up, inoculated on nutrient broth and then subcultured on Tryptic Soy agar (DIFCO). The isolates were identified according to the colony morphology, pigment production, Gram's stain and Albert stain morphology, as well as biochemical characters. The bacterial isolates were classified by species according to Barrow and Feltham (10) and Bergey's Manual of Systemic Bacteriology (11).

■ RESULTS

Histopathological pictures

Out of 284 lungs examined, 29 (10.2%) lungs had gross lesions. These lesions were found in lungs of various camel age groups. The chronic proliferative bronchopneumonia and chronic pleuropneumonia were observed more frequently in older animals, while interstitial pneumonia and lung abscesses were more common in younger animals (Table I).

Histopathological changes showed chronic proliferative bronchopneumonia in six lungs and chronic pleuropneumonia in two lungs (Table I). The chronic proliferative bronchopneumonia was characterized by a "hepatized" texture of the affected tissue and a mosaic appearance (Figure 1). Under a microscope, the lesions were characterized by severe mononuclear infiltration and fibrous proliferation. The alveoli were either filled with inflammatory cells or totally damaged with giant cell formation (Figure 2). The bronchi were filled with inflammatory cells and congested blood vessels. In chronic pleuropneumonia, there was also expansion and congestion of the pleura and caudal lobe (phringe-extensions) and infiltration of inflammatory cells (macrophages and polymorphs) (Figure 3). In only one lung, pleuritis was diagnosed with pulmonary edema, which was characterized by dilated lymph vessels, congestion of blood vessels, moderate infiltration of inflammatory cells with proteinaceous materials and thickening of the alveolar wall. Interstitial pneumonia was observed in 17 lungs and was characterized by thickening of alveolar wall and presence of inflammatory cells in moderate numbers (Figure 4). Lung abscesses were found in three lungs and were characterized by the presence of several abscesses (1-2 cm in diameter) close to each other and filled with cheese-like viscid pus.

Table I

Pathological findings, frequency, distribution according to age and most frequent isolates of 29 pneumonic camel lungs in northern Jordan

Type of lung lesion	Prevalence of lung lesions (%)	Animal age	Most frequent bacterial isolates
Chronic proliferative bronchopneumonia	6 (20.69)	1-10 years	<i>Pasteurella haemolytica</i> , <i>Pseudomonas aeruginosa</i> , <i>E. coli</i> , <i>Klebsiella</i> spp.
Chronic pleuropneumonia	2 (6.9)	10 years	<i>Pasteurella haemolytica</i> , <i>Pseudomonas aeruginosa</i>
Pleuritis with pulmonary edema	1 (3.45)	2 years	<i>Staphylococcus aureus</i>
Interstitial pneumonia	17 (58.6)	6 months to 4 years	<i>E. coli</i> , <i>Klebsiella</i> spp., <i>Pseudomonas aeruginosa</i> , <i>Staphylococcus</i> spp.
Lung abscess	3 (10.34)	1-2 years	<i>Staphylococcus</i> spp., hemolytic streptococci, <i>Actinomyces pyogenes</i> , <i>E. coli</i>

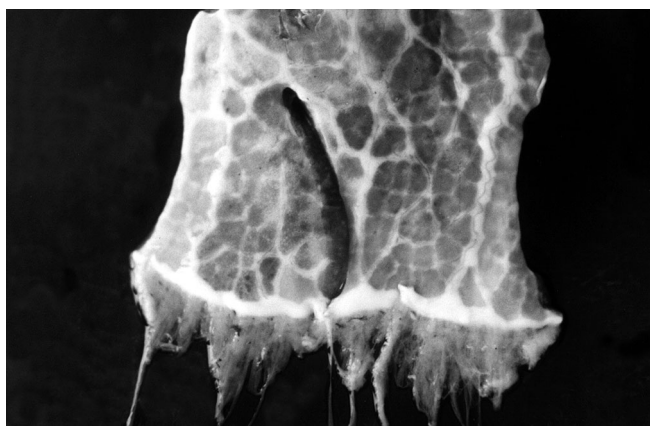

Figure 1: Chronic proliferative bronchopneumonia of a ten-year-old camel. The affected part shown is the caudal lobe of the lung. Notice the mosaic appearance, the fibrosis on the right side and the phringes.

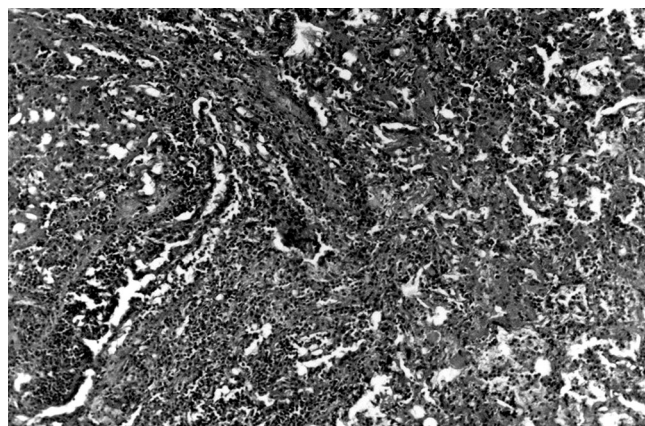


Figure 2: Microscopic appearance of chronic proliferative bronchopneumonia characterized by severe mononuclear infiltration; the alveoli are damaged and filled with inflammatory cells (H & E; x 200).

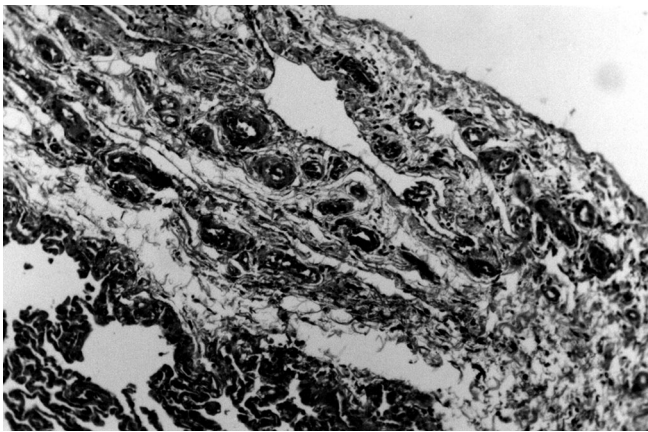


Figure 3: Microscopic appearance of chronic pleuropneumonia in which the pleura is invaded by inflammatory cells and the blood vessels are congested (H & E; x 800).

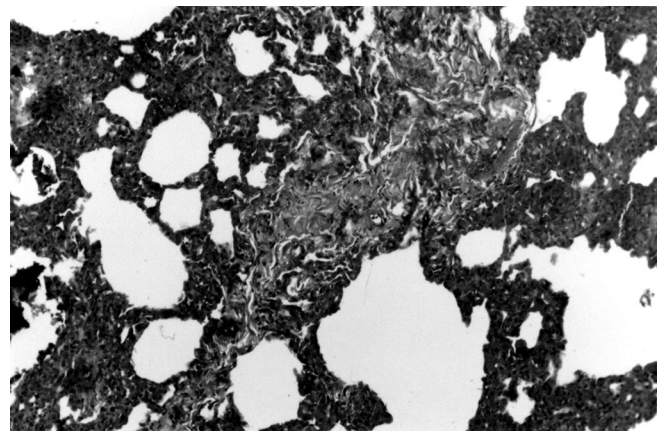


Figure 4: Interstitial pneumonia in a camel. Notice the thickening of the alveolar wall and presence of a moderate number of inflammatory cells (H & E; x 200).

Bacterial isolates

A total of 75 bacterial isolates were collected from the 29 pneumonic lungs cultured. More than one bacterial species were isolated from 24 pneumonic lungs, one species from three lungs and no bacterial growth was obtained from two lungs. The ten apparently healthy lungs examined did not reveal any bacterial growth. There were 47 Gram-negative bacterial isolates that were or could be pathogenic: *Escherichia coli*, *Klebsiella* spp., *Pseudomonas aeruginosa*, *Mannheimia haemolytica* (previously *Pasteurella haemolytica*) and *Citrobacter* spp. And there were 20 Gram-positive isolates: *Staphylococcus aureus*, *Staphylococcus* spp., *Actinomyces pyogenes* and hemolytic streptococci. Other bacterial species (eight isolates) were also collected: *Bacillus* spp., *Proteus* spp. and *Enterobacter aerogenes* (Table II). The species of *Klebsiella* were identified and *Klebsiella ozaenae* was the most frequent (Table III). The results showed that *E. coli* and *Klebsiella* spp. were the most frequent isolates from cases of interstitial pneumonia, in addition to *Pseudomonas aeruginosa* and *Staphylococcus* spp. On the other hand, *Mannheimia haemolytica* and *Pseudomonas aeruginosa* were the most frequent isolates from cases of chronic proliferative bronchopneumonia and chronic pleuropneumonia, in addition to *E. coli* and *Klebsiella* spp. From cases of lung abscesses, *Staphylococcus aureus*, other *Staphylococcus* species, hemolytic streptococci, *Actinomyces pyogenes* and *E. coli* were isolated (Table I).

DISCUSSION

In this study, pathological examination of 284 slaughtered camel lungs showed occurrence of pneumonia in 29 (10.2%) lungs. This agrees with the results of other studies conducted in Jordan and Egypt, where the infection rates of the lungs examined were 10 and 12%, respectively (6, 18).

The results of this work show that chronic proliferative bronchopneumonia and chronic pleuropneumonia were found mainly in old camels. They were found in six (20.69%) and two (6.9%), respectively, out of 29 pneumonic lungs, from which *Mannheimia haemolytica* (8), *Pseudomonas aeruginosa*, *E. coli* and *Klebsiella* spp. were isolated. In Egypt, it was reported that out of 23 camel lungs examined, only three (13%) showed "hepatization", and *Staphylococcus aureus*, *Streptococcus pyogenes*, *Klebsiella* and *Citrobacter* were isolated (18). In Iraq,

Table II
Identification of 75 bacterial isolates from 29 pneumonic lungs of camels in northern Jordan

	Num. of isolates	%
<i>Escherichia coli</i>	20	26.66
<i>Klebsiella</i> spp.	11	14.66
<i>Staphylococcus aureus</i>	8	10.66
Other <i>Staphylococcus</i> spp.	3	4.00
<i>Pseudomonas aeruginosa</i>	9	12.00
<i>Actinomyces pyogenes</i>	5	6.66
<i>Pasteurella haemolytica</i>	5	6.66
Hemolytic streptococci	4	5.33
<i>Citrobacter</i> spp.	2	2.66
<i>Enterobacter aerogenes</i>	2	2.66
<i>Proteus</i> spp.	2	2.66
<i>Bacillus</i> spp.	4	5.33

Table III
Klebsiella species isolated from 11 pneumonic lungs of camels in northern Jordan

	Num. of isolates
<i>Klebsiella ozaenae</i>	5
<i>Klebsiella pneumoniae</i>	3
<i>Klebsiella oxytoca</i>	2
<i>Klebsiella rhinoscleromatis</i>	1

another study showed that 56% of 150 camel lungs were pneumonic and *Pasteurella multocida*, *Mannheimia haemolytica*, *E. coli*, *Pseudomonas aeruginosa* and *Actinomyces pyogenes* were isolated (3). In this study, *M. haemolytica*, and *Pseudomonas aeruginosa* were the most prominent in the cultures and they might have been the main cause of chronic bronchopneumonia in camels, while *E. coli* and *Klebsiella* spp. were less prominent and might be considered as secondary invaders.

The results of this study show that interstitial pneumonia was more frequent in young camels than in older ones. It was diagnosed in

17 (58.6%) of the 29 pneumonic lungs, from which *E. coli* and *Klebsiella* spp. were the most predominant isolates mixed with *Pseudomonas aeruginosa* or *Staphylococcus aureus* or with other *Staphylococcus* species. Similarly, these types of pneumonia were reported to occur in free-range animals (12).

In this study, a relatively high number of bacterial isolates (75) were collected from 29 pneumonic lungs, of which 24 revealed more than one bacterial species. The bacterial species isolated and identified from the affected lungs included *E. coli*, *Klebsiella* spp., *S. aureus*, *P. aeruginosa*, *A. pyogenes*, *M. haemolytica*, *Streptococcus* spp., *Citrobacter*, *E. aerogenes*, *Proteus* and *Bacillus*. The ten apparently healthy lungs examined and considered as negative control revealed no bacterial growth. These results agree with other studies conducted in Pakistan (4) and Egypt (18), where the authors conclude that the etiology of pneumonia in camels is multifactorial. The results of this study also agree with those reported in Sudan, where *S. aureus* (34.6%), *Klebsiella* spp. (26.4%), *A. pyogenes* (22.4%) and *S. pyogenes* (16.8%) were isolated from 96 pneumonic lungs among 125 camel examined (20), and those reported in Iraq, where *P. multocida*, *M. haemolytica*, *E. coli*, *Pseudomonas aeruginosa* and *A. pyogenes* were isolated in 56% of 150 camel lungs (3).

Three lungs showed multiple abscesses (1-2 cm in diameter), from which *S. aureus*, hemolytic streptococci and *A. pyogenes* were isolated. Such types of abscesses in camel lungs were reported in Iraq, where five camels showed small localized abscesses in the lungs and *A. ovis* was isolated (3). These results agree with what was mentioned in the literature about causative agents of abscesses (13, 23, 24).

The isolation of *M. haemolytica* from "hepatized" camel lungs agrees with results from other studies conducted in Jordan (6), Iraq (3) and Sudan (20). In contrast, it differs from reports in Egypt, where no *M. haemolytica* was isolated from any pathological lesions of six pneumonic lungs (18).

In this study, *K. ozaenae*, *K. pneumoniae*, *K. oxytoca* and *K. rhinoscleromatis* were isolated from pneumonic lungs of camels, whereas in most previous studies on camel pneumonia *Klebsiella* is mentioned at the genus level only. Finally, *Bacillus*, *Proteus* and *E. aerogenes* isolates were collected from mixed cultures of pneumonic lungs. Such isolates were previously mentioned by others and are considered less pathogenic (4, 21).

■ CONCLUSION

Camels in Jordan were found to be affected with bacterial pneumonia. Their prevalence rate in the present study was 10.2%. Bacterial pneumonia could be classified into three groups: chronic proliferative bronchopneumonia, chronic pleuropneumonia and interstitial pneumonia. Chronic pneumonia that affected older camels was mainly caused by *M. haemolytica* and *Pseudomonas aeruginosa*, whereas interstitial pneumonia that affected young camels was caused by *Klebsiella* spp. and *E. coli*. Lung abscesses were caused by pyogenic organisms. The majority of bacterial pneumonia cases had multifactorial causes.

Acknowledgments

The author wishes to thank the Faculty of Scientific Research at Jordan University of Science and Technology (JUST) for funding this research (project No. 145/99).

REFERENCES

1. ABDEL-HAFEZ S.K., AL-YAMAN F.M., SAID I.M., 1986. Further studies on prevalence of hydatidosis in slaughtered animals from north Jordan. *J. Parasitkde*, **72**: 89-96.
2. AL-ALLAWY T.A., MOTTELIB T.A., NASHED S., SALEM H., 1979. A study of pneumonia in buffalo calves in Egypt. *J. Egypt vet. Med. Assoc.*, **39**: 23-28.
3. AL-ANI F.K., 1990. Common respiratory diseases of Iraqi camels. In: Proc. Symposium on Camel Breeding, Diseases and their Control, Arab Organization for Agricultural Development (AOAD), Alger, Algeria, 24-26 March 1990, p. 283-287.
4. AL-DOUGHAYM A.M., MUSTAFA K.M., MOHAMED G.E., 1999. Aetiological study on pneumonia in camel (*Camelus dromedarius*) and *in vitro* anti-bacterial sensitivity pattern of the isolates. *Pak. J. Biol. Sci.*, **2**: 1102-1105.
5. ALLEY M.R., 1991. In: Grunsell C.S.G., Raw M.E., Eds, The veterinary annual. Pneumonia in sheep. Oxford, UK, Blackwell Scientific, p. 51-58.
6. AL-RAWASHDEH O.F., AL-ANI F.K., SHARRIF L.A., AL-QUDAH K.M., AL-HAMI Y., FRANK I., 2000. A survey of camel (*Camelus dromedarius*) diseases in Jordan. *J. Zoo Wildl. Med.*, **31**: 335-338.
7. AL-RAWASHDEH O.F., SHARIF L.A., AL-QUDAH K., AL-ANI F.K., 1999. *Trypanosoma evansi* infection in camels in Jordan. *Revue Elev. Méd. vét. Pays trop.*, **52**: 233-237.
8. ANGEN O., MUTTERS R., CAUGANT D.A., OLSEN J.E., BISGAARD M., 1999. Taxonomic relationships of the (*Pasteurella*) *haemolytica* complex as evaluated by DNA-DNA hybridizations and 16S rRNA sequencing with proposal of *Mannheimia haemolytica* gen. Nov., comb. Nov., *Mannheimia granulomatis* comb. Nov., *Mannheimia glucosida* spp. Nov., *Mannheimia ruminalis* spp. Nov. and *Mannheimia varigena* spp. Nov. *Int. J. Syst. Bact.*, **1**: 67-86.
9. BANCROFT J.D., STEVENS A., 1990. Theory and practice of histological techniques, 3rd Ed. Edinburgh, UK, Churchill Livingstone, p. 21-118.
10. BARROW G.I., FELTHAM R.K.A., 1993. In: Cowan and Steel's Manual for identification of medical bacteria, 3rd Ed. Cambridge, UK, Cambridge University Press, p. 50-150.
11. BERGEY'S MANUAL OF SYSTEMIC BACTERIOLOGY, 1984. Volume 1. Baltimore, MD, USA, William & Wilkins, p. 409-570.
12. BLOOD D.C., RADOSTITS O.M., 1990. Veterinary medicine, 7th Ed. London, UK, Bailliere Tindall, p. 1427-1433.
13. COSTA L.R.R., SPIER S.J., HIRSH D.C., 1998. Comparative molecular characterization of *Corynebacterium pseudotuberculosis* of different origins. *Vet. Microbiol.*, **62**: 135-143.
14. DUNGWORTH D.L., 1993. The respiratory system, inflammation of the lungs. In: Jubb K.V.F., Kennedy P.C., Palmer N., Eds, Pathology of domestic animals, 4th Ed., Vol. 2. New York, NY, USA, Academic Press, p. 591-608.
15. EL-MAGAWRY S., OKELA M., EZZAT M., EL-ATTAR H.M., 1986. Etiological study on respiratory affection in camels and its relation to hematological and biochemical changes. *Assiut vet. Med. J.*, **17**: 97-103.
16. FAO, 1995. Production yearbook. The Middle East and North Africa, 41st Edn. London, UK, Europe Publications, p. 593.
17. KIRTON A.H., O'HARA P.J., SHORTRIDGE E.H., CORDES D.O., 1976. Seasonal incidence of enzootic pneumonia and its effect on the growth of lambs. *N. Z. vet. J.*, **24**: 59-64.

18. MAHMOUD A.Z., SABAH I.M., EL-YAS A.H., 1988. A study on lung affections of camels (*Camelus dromedarius*) in Assiut governerate. *Assiut vet. Med. J.*, **20**: 93-99.
19. MCLEROY S.G., GOODALL E.A., MCCRACKEN R.M., STEWART D.A., 1989. Rain and windchill as factors in the occurrence of pneumonia in sheep. *Vet. Rec.*, **125**: 79-82.
20. MOHAMED G.E., ABU-SAMRA M.T., MUSA B.E., 1990. The status of camel diseases in the Sudan and future out load. In: Proc. Symposium on Camel Breeding, Diseases and their Control, Arab Organization for Agricultural Development (AOAD), Alger, Algeria, 24-26 March 1990, p. 251-269.
21. MOHAMED B.A., FARAH I.O., 1994. Isolation of aerobic bacterial species from the dromedary camel. *Sud. J. vet. Anim. Husb.*, **33**: 58-64.
22. MUSA M.T., HARRISON M., IBRAHIM A.M., TAHA T.O., 1989. Observations on Sudanese camel nasal myiasis caused by the larvae of *Cephalopina titillator*. *Revue Elev. Méd. vét. Pays trop.*, **42**: 27-31.
23. NOBLE W.C., 1998. Staphylococcal diseases. In: William J., Hausler Jr., Sussman M., Eds, Topley and Wilson's Microbiology and microbial infections, 9th Edn, Vol. 3, Bacterial infections. London, UK, Arnold, p. 231-255.
24. RUOFF K.L., 1998. Streptococcal diseases. In: William J., Hausler Jr., Sussman M., Eds, Topley and Wilson's Microbiology and microbial infections, 9th Edn, Vol. 3, Bacterial infections. London, UK, Arnold, p. 257-275.
25. SCHWARTZ H.J., DIOLI M., Eds, 1992. The one-humped camel (*Camelus dromedarius*) in Eastern Africa; A pictorial guide to diseases, health care and management. Weikersheim, Germany, Verlag Josef Margraf, p.199-203.
26. SELMAN I.E., WISEMAN A., 1983. A study of respiratory disease of adult cattle in Britain, problems affecting individual animals. *Ir. vet. J.*, **37**: 28-34.
27. WEBSTER A.J.F., 1981. Weather and infectious disease in cattle. *Vet. Rec.*, **108**: 183-187.

Reçu le 13.09.2001, accepté le 26.02.2002

Resumé

Al-Tarazi Y.H. Etude bactériologique et pathologique de la pneumonie chez le dromadaire (*Camelus dromedarius*) en Jordanie

Les publications concernant la pneumonie chez le dromadaire sont en général rares. Dans cette étude, 284 poumons de dromadaires, abattus entre 6 mois et 10 ans d'âge et provenant du nord de la Jordanie, ont été examinés. La prévalence de la pneumonie a été de 10,2 p. 100. Les lésions pathologiques des poumons atteints de pneumonie ont été classées selon qu'elles indiquaient la présence de la broncho-pneumonie proliférative chronique, de la pleuropneumonie chronique ou de la pneumonie interstitielle. Les abcès du poumon ont aussi été enregistrés. La broncho-pneumonie proliférative chronique (20,69 p. 100) et la pleuropneumonie chronique (6,9 p. 100) ont été plus fréquentes chez les dromadaires âgés (10 ans environ), alors que la pneumonie interstitielle (58,6 p. 100) et les abcès du poumon (10,34 p. 100) ont été plus fréquents chez les jeunes dromadaires (âgés de 6 mois à 4 ans). *Mannheimia haemolytica* et *Pseudomonas aeruginosa* ont été les espèces les plus fréquemment isolées dans le cas de broncho-pneumonie proliférative chronique et de pleuropneumonie chronique, alors que, dans les cas de pneumonie interstitielle, c'étaient *Escherichia coli* et *Klebsiella* spp. qui l'ont été le plus. Dans les cas d'abcès du poumon c'étaient *Staphylococcus aureus*, *Actinomyces pyogenes* et des streptocoques hémolytiques qui ont été le plus fréquemment observés. Au total, 75 espèces bactériennes ont été isolées de 29 poumons. Les plus fréquentes ont été *E. coli* (26,66 p. 100), *Klebsiella* spp. (14,66 p. 100), *Pseudomonas aeruginosa* (12 p. 100), *Staphylococcus aureus* (10,66 p. 100), *Mannheimia haemolytica* (6,66 p. 100) et *Actinomyces pyogenes* (6,66 p. 100). L'espèce la plus souvent observée parmi les *Klebsiella* identifiées a été *Klebsiella ozaenae*.

Mots-clés : *Camelus dromedarius* - Pneumonie - Bactérie Gram positif - Bactérie Gram négatif - Histopathologie - Jordanie.

Resumen

Al-Tarazi Y.H. Estudio bacteriológico y patológico sobre la neumonía en dromedarios (*Camelus dromedarius*) en Jordania

La literatura sobre camellos es, en general, rara. En el presente estudio, se examinaron 284 pulmones de camellos sacrificados (de 6 meses a 10 años de edad) en Jordania del norte. La prevalencia de neumonía fue de 10,2%. Las lesiones patológicas de los pulmones con neumonía fueron clasificadas como bronconeumonía crónica proliferativa, pleuroneumonía crónica y neumonía intersticial. Se encontraron también abscesos pulmonares. La bronconeumonía crónica proliferativa (20,69%) y la pleuroneumonía crónica (6,9%) fueron más frecuentes en camellos viejos (aproximadamente 10 años de edad). Por otro lado, la neumonía intersticial (58,6%) y los abscesos pulmonares (10,34%) fueron más frecuentes en camellos jóvenes (6 meses a 4 años de edad). Los aislamientos más frecuentes en casos de bronconeumonía crónica proliferativa y pleuroneumonía crónica fueron *Mannheimia haemolytica* y *Pseudomonas aeruginosa*, mientras que *Escherichia coli* y *Klebsiella* spp. fueron los más frecuentes en los aislamientos en caso de neumonía intersticial. *Staphylococcus aureus*, *Actinomyces pyogenes* y estreptococos hemolíticos fueron los aislamientos más frecuentes en casos de abscesos pulmonares. Se recolectaron un total de 75 aislamientos bacterianos, a partir de 29 pulmones neumónicos. Los más frecuentes fueron: *E. coli* (26,66%), *Klebsiella* spp. (14,66%), *Pseudomonas aeruginosa* (12%), *Staphylococcus aureus* (10,66%), *Mannheimia haemolytica* (6,66%) y *Actinomyces pyogenes* (6,66%). *Klebsiella ozaenae* fue la más frecuente de las especies de *Klebsiella* identificadas.

Palabras clave: *Camelus dromedarius* - Neumonía - Bacteria gram positiva - Bacteria gram negativa - Histopatología - Jordania.