

# Prevalence of *Eimeria stiedai* infection in outbred domestic rabbits (*Oryctolagus cuniculus*) in Eastern Nigeria

G.A. Musongong<sup>1\*</sup> B.B. Fakae<sup>1</sup>

## Key words

*Oryctolagus cuniculus* - Rabbit - *Eimeria stiedai* - Coccidiosis - Liver - Morbidity - Nigeria.

## Summary

Examination of livers of 131 (103 young and 28 adult) rabbits purchased directly from local keepers and village markets in Eastern Nigeria revealed that hepatic coccidiosis due to *Eimeria stiedai* is endemic in this region. Forty-one (37.4%) of them were infected. The liver-to-body weight ratio, which was used as an index of gross pathology in infected rabbits, was significantly higher ( $P < 0.05$ ) in the latter than in noninfected rabbits. Hepatic coccidiosis was prevalent in rabbits from all the sites studied. Further research on this aspect of rabbit health is recommended in order to promote successful rabbit production in village communities in Eastern Nigeria.

## INTRODUCTION

Coccidiosis caused by *Eimeria* species in general is a serious problem interfering with rabbit production (1, 6). Liver coccidiosis caused by *E. stiedai* is one of the major forms of the disease that causes high mortality in young rabbits (5). Apart from resulting in economic loss, infections with *Eimeria* species are important in concurrent experimental infections with other parasite species, for example gastrointestinal nematodes (3), since they may influence the normal course of infection with the nematode. Furthermore, rabbit keeping has become a lucrative enterprise among rural communities in Nigeria and rabbit meat serves as a good alternative source of protein in family diets (4). Unfortunately, information about the prevalence of *Eimeria* species infection in domestic rabbits in Nigeria is not readily available. This paper reports for the first time on the prevalence of natural *E. stiedai* infections in an outbred strain of domestic rabbits in Eastern Nigeria in order to stimulate further research on this aspect of rabbit health in Nigeria.

1. Department of Veterinary Parasitology and Entomology, University of Nigeria, Nsukka, Nigeria

\* Corresponding author's present address: IRAD, Regional Centre of Wakwa, PO Box 65, Ngaoundere, Cameroon

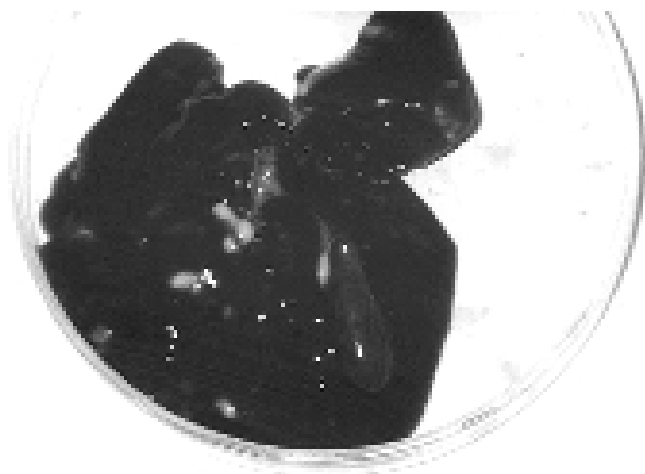
Fax: +237 25 15 57; E-mail: vtanya@syfed.cm.refer.org

## MATERIALS AND METHODS

A total of 131 (28 adult and 103 young) outbred domestic rabbits were sampled from lots purchased from village markets (Ibagwa, Orba, Obollo, Nsukka, and Ovoko) in Nsukka Local Government Area of Eastern Nigeria, between December 1992 and November 1995. At necropsy, each liver was removed and inspected for nodules typical of infection with *E. stiedai* (2). When nodules were present, smears from such nodules and sediments of bile from the infected livers were examined under a x10 objective of a microscope for *E. stiedai* oocysts. Both infected and uninfected livers were weighed and the liver-to-body weight ratio (%) calculated for comparison.

## RESULTS

The smears from liver nodules and bile sediments from infected livers showed oocysts characteristic of *E. stiedai*. Nine (32.14%) adult rabbits and 40 (38.80%) young rabbits were infected with *E. stiedai*. All the studied sites had infected rabbits. Most of the livers were heavily infected (figure 1) and some nodules were already coalescent. The liver-to-body weight ratio ranged from 2 to 9% in infected rabbits and from 2 to 5% in uninfected rabbits.



**Figure 1:** Liver of rabbit naturally infected with *Eimeria stiedai*. White spots indicate distended bile ducts.

## ■ DISCUSSION

These results indicate that coccidiosis due to *E. stiedai* was endemic in domestic rabbits in this part of Nigeria. In addition, the infection prevalence was high in both young and adult rabbits of this outbred strain. Further studies on this infection are necessary because it may be one of the undiagnosed causes of mortality and reduced productivity of local rabbits in Eastern Nigeria. There seems to be a general lack of awareness about coccidiosis in domestic rabbits in Nigeria. In addition, oocysts of *E. stiedai* may not be easily observed in mixed infections with other *Eimeria* species since most of them tend to be trapped in biliary ducts of the liver (2) making thus a precise diagnosis difficult. The degree

of damage that may be caused by the parasite is reflected in the changes in the liver of infected rabbits. A higher mean liver-to-body weight ratio of infected rabbits compared to that of uninfected rabbits is evidence of impairment of the liver function (5). The factors influencing the endemicity of this infection in local rabbitries in Eastern Nigeria are not very clear and should be studied.

## Acknowledgments

We are grateful to the Department of Veterinary Parasitology and Entomology, University of Nigeria, Nsukka, for providing the facilities to perform this work.

## REFERENCES

1. ARRINGTON L.R., KELLEY K.C., 1976. Domestic rabbit biology and production. Gainesville, FL, USA, The University Presses of Florida, 230 p.
2. COUDERT P., LICOIS D., DROUET-VIARD F., 1995. *Eimeria* species and strains of rabbits. In: Eckert J., Braun R., Shirley M.W., Coudert P., Eds., Biotechnology - Guidelines on techniques in coccidiosis research. Brussels, Belgium, European Commission, p. 52-73.
3. DAVIS L.R., HERLICH H., BOWMAN G.W., 1960. Studies on concurrent experimental infections of dairy calves with coccidia and nematodes. III. *Eimeria* spp. and the thread worm *Strongyloides papillosus*. *Am. J. vet. Res.*, **21**: 181-187.
4. FIELDING D., 1991. The tropical agriculturalist. Rabbits. London, Basingstoke, UK, CTA Macmillan, 106 p.
5. LEVINE N.D., 1985. Veterinary protozoology. Ames, IA, USA, Iowa State University Press, 414 p.
6. WOOD C., 1978. The pet rabbit - Veterinary problems. *Vet. Rec.*, **102**: 304-308.

Reçu le 13.8.97, accepté le 11.8.99

## Résumé

**Musongong G.A., Fakae B.B.** Prévalence de la coccidiose hépatique causée par *Eimeria stiedai* chez des lapins domestiques au Nigeria oriental

L'examen de foies de 131 lapins (103 jeunes et 28 adultes) achetés directement auprès d'éleveurs locaux et dans des marchés ruraux du Nigeria oriental a montré que la coccidiose hépatique causée par *Eimeria stiedai* est endémique dans cette région. Quarante et un de ces lapins (37,4 p. 100) étaient infectés. Le rapport entre le foie et le poids corporel, utilisé ici comme indice de la pathologie générale des lapins infectés, a été significativement plus élevé ( $P < 0,05$ ) chez ces derniers que chez les lapins non-infectés. La coccidiose hépatique a été prévalente chez les lapins dans tous les sites étudiés. D'autres études sur cet aspect de la santé des lapins sont recommandées pour assurer le succès de la production de lapins dans les communautés villageoises du Nigeria oriental.

**Mots-clés :** *Oryctolagus cuniculus* - Lapin - *Eimeria stiedai* - Coccidiose - Foie - Morbidité - Nigeria.

## Resumen

**Musongong G.A., Fakae B.B.** Prevalencia de la infección por *Eimeria stiedai* en conejos domésticos (*Oryctolagus cuniculus*) en el este de Nigeria

El examen de los hígados de 131 conejos (103 jóvenes y 28 adultos), comprados directamente a criadores locales y en mercados de pueblo en el este de Nigeria, revelará que la coccidiosis hepática por *Eimeria stiedai* es endémica en esta región. Cuarenta y uno (37,4%) de éstos estuvieron infectados. La relación de peso hígado/cuerpo, la cual se utilizó como índice de patología en general en los conejos infectados, fue significativamente más elevado ( $p < 0,05$ ) en los últimos que en los conejos no infectados. La coccidiosis hepática fue prevalente en los conejos de todos los sitios estudiados. Se recomienda una mayor investigación en este aspecto de la salud del conejo, con el fin de promover una producción de conejos exitosa en los pueblos del este de Nigeria.

**Palabras clave:** *Oryctolagus cuniculus* - Conejo - *Eimeria stiedai* - Coccidiosis - Hígado - Morbosidad - Nigeria.