

Sheep pulmonary adenomatosis (Jaagsiekte) in Libya: gross and histopathological evidence

O.A. Ali¹ E.B. Abdelsalam²

Key words

Sheep - Pulmonary adenomatosis - Lung - Carcinoma - Libyan Arab Jamahiriya.

Summary

Gross and histopathological features indicative of sheep pulmonary adenomatosis (SPA) were detected in the right lung of an old female Beriberi sheep suffering from persistent respiratory distress. These were mainly dominated by multifocal papillomatous proliferation of the alveolar epithelium associated with abundant alveolar macrophage infiltrates. Four similar cases were further spotted in a ten-year histopathological survey of the disease in Tripoli area.

■ INTRODUCTION

Sheep pulmonary adenomatosis (SPA), currently known as sheep pulmonary carcinomatosis (Jaagsiekte), is a chronically progressing pulmonary disease of adult sheep. It was initially recognized in South Africa and has now a worldwide geographic distribution with a serious impact on sheep population in affected areas (1, 4, 16, 21). The disease is characterized by broncho-alveolar carcinoma with occasional metastasis to the regional lymph nodes (8, 14). The precise aetiology of SPA has long been a controversial issue (3, 10, 17) but further morphological, biochemical and immunological advances incriminate a type D related retrovirus (11, 22, 23). This virus (Jaagsiekte sheep retrovirus, JSRV) was consistently detected in the neoplastic pulmonary epithelium of naturally and experimentally infected sheep (12, 13). The aim of this communication is to report and provide a concise pathological account of SPA in Libya. The study was conducted on a recent clinical case and retrospective material from ovine lung tissues previously submitted to the Department of Veterinary Pathology (Al-Fateh University) for routine diagnosis.

■ MATERIALS AND METHODS

The material of this investigation was composed of two parts. The first part consisted of a female fat-tailed Beriberi sheep (native Libyan breed). It was originally purchased from a local market for

teaching purposes and kept in the animal facility of the Veterinary College, Tripoli. The animal was about four years of age, in poor health and suffering from persistent respiratory distress accompanied by intermittent cough and nasal discharges. The ewe was slaughtered due to advanced emaciation and lack of responsiveness to different therapeutic agents. Post-mortem examination was immediately carried out and representative lung tissues were fixed in 10% formol-saline for routine histopathological processing and staining with hematoxylin and eosin (H&E).

The second part of the material included ready-made paraffin-wax sections of ovine lung tissues previously submitted to the Pathology Department for routine diagnosis during the past ten years (1987-1996). Numerous slides (1,114) were examined for various types of pulmonary lesions and those showing typical microscopic changes of SPA were further considered in the present study. The attached diagnostic reports were also reviewed including those based on gross examination supported by other bacteriological and parasitological findings.

■ RESULTS

Gross pathology

Post-mortem examination of the animal revealed moderate amounts of spumous fluid within the trachea and major bronchi. The costal surface of the diaphragmatic lobe of the right lung contained a single, approximately measuring 4 x 6 cm, slightly elevated nodular mass. It was white-grey and loosely demarcated from the adjacent apparently normal pulmonary parenchyma. The mass was of a moderately firm consistency and its cut surface was extremely pale and did not express an appreciable amount of fluid

Department of Veterinary Pathology, Al-Fateh University, Tripoli, Libya
Present Addresses:

1. Central Veterinary Research Laboratories, Khartoum, Sudan
2. Department of Pathology, Faculty of Veterinary Science, University of Khartoum, PO. Box 32, Khartoum North 13314, Sudan

upon press. Further palpation of the other lung lobes failed to demonstrate comparable lesions. No other remarkable changes were recognized in the rest of the respiratory system. The regional lymph nodes were not grossly enlarged but they were not examined microscopically.

Histopathology

The retrospective survey on sheep pulmonary lesions indicated that fibrinous pneumonia was the most common finding involving more than 60% of the total cases diagnosed at the Pathology Department during the designated period (1987-1996).

Pasteurella haemolytica and *P. multocida* were frequently isolated from those pneumonic lesions as shown in the departmental records. Other pulmonary lesions were diagnosed as suppurative bronchopneumonia, lung abscesses, verminous pneumonia, pulmonary tuberculosis, chronic interstitial pneumonia and chronic bronchitis. However, only four cases showed typical microscopic changes indicative of SPA. The involved animals were listed as adults with an average age of three years and a half. Other informations regarding their origin or breed were completely lacking.

The microscopic features of the fresh and old cases of SPA were basically similar and hence will be discussed together. The changes involved large portions of the examined parenchyma and were mostly confined to the alveoli with a frequent involvement of the adjacent bronchioles. The affected alveoli were lined with cuboidal to low columnar cells. These were arranged in variably protruding papillomatous structures that extended into the lumen of the alveoli (figure 1). Some of these projections tended to occlude partially or completely the lumen of many alveoli. Some of the bronchioles were also affected but their overall response was dominated by focal hypertrophy, and infrequently, hyperplasia of the lining epithelium.

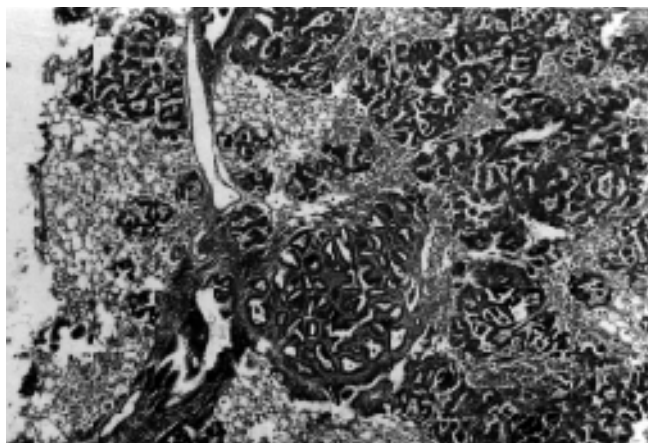


Figure 1: Lung of an aged ewe affected with SPA, with multifocal papillomatous proliferation of the alveolar epithelium (H&E X 40).

In addition, a large number of apparently unaffected alveoli were distended with numerous, closely packed large foamy macrophages (figure 2). In some cases, mononuclear cellular infiltration was occasionally accompanied by focal fibrosis or myxomatous changes that replaced considerable portion of the pre-existing lung parenchyma. Other changes of minor frequency and significance were those presented by peribronchiolar lymphocytic and phagocytic aggregates.

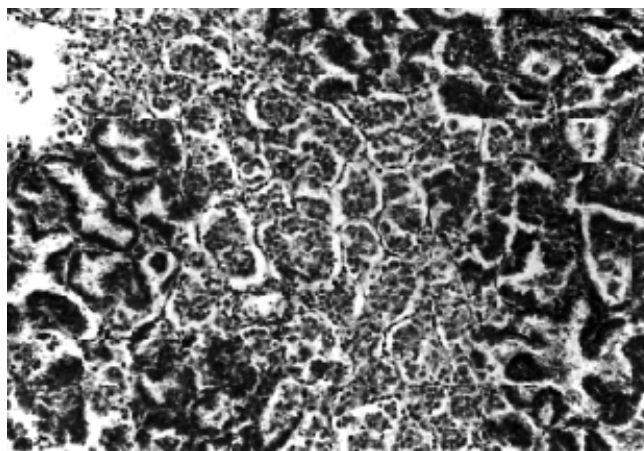


Figure 2: Lung of the same ewe, with large number of foamy macrophages present inside the apparently unaffected alveoli (H&E X 100).

■ DISCUSSION

The information reported here from the present clinical case combined with the retrospective data provided sufficient evidence for the presence of sheep pulmonary adenomatosis (SPA) in Libya. The most salient histopathological alterations in all affected lungs were almost similar to those previously described (4, 8, 16, 18, 20). These were mainly dominated by the distinctive multifocal papillomatous proliferation of neoplastic alveolar epithelium associated with the presence of large number of alveolar macrophages in the least affected parts of the lung tissue. However, the neoplastic proliferation of the alveolar epithelium was occasionally accompanied by some focal chronic interstitial reactions represented by focal fibrosis, mononuclear cellular infiltration, myxomatous infiltration and prebronchiolar lymphocytic aggregates. These changes were also observed with ovine lymphocytic interstitial pneumonia (maedi) which is caused by a closely related lentivirus (8, 9, 15). Nevertheless, the spontaneous occurrence of SPA and maedi in the same flock or in the same affected animal has repeatedly been reported in many other countries (5, 7, 15, 19).

SPA has been previously recognized in a number of Mediterranean countries other than Libya. For example, the disease was occasionally reported in Spain (6), Cyprus (20) and in the neighboring Tunisia (2). In the present investigation, only five cases were identified as SPA throughout the designated period of study (1987-1996). The first one was the currently described clinical case and the other four were detected out of 1,114 microscopic sections of ovine lungs showing various types of pulmonary lesions during the 10-year retrospective survey. It is apparent from these few cases that the overall incidence of SPA is fairly low in Libya as compared with some other countries (1, 2, 6, 16). However, this does not probably reflect the real epidemiological status of the disease in the whole country as the study was only confined to Tripoli area. It is quite possible that some genuine cases of SPA in the remote parts of the country might have not been properly diagnosed by local veterinarians, due to the considerable lack of adequate laboratory facilities in these areas. In addition, a number of pulmonary lesions included in the present retrospective data were grossly diagnosed as fibrinous or verminous pneumonia without further histopathological confirmation, and this would eventually reduce the chances of detecting the disease (SPA) when co-existing with any of the above-

mentioned pathological conditions. Further studies are therefore required in order to outline the extent and regional distribution of the disease throughout the country for establishing future control measures.

Acknowledgements

We are grateful to Ms Turky Adoma for technical assistance and full cooperation throughout the tedious probing task on the departmental records.

REFERENCES

1. BASSETT H.F., SHEEHAN P., 1989. Outbreak of sheep pulmonary adenomatosis in Irish Republic. *Vet. Rec.*, **124**: 46-47.
2. BOUTOURIA M., SOUSSI H., 1987. Pulmonary adenomatosis of sheep in Tunisia. *Maghreb Vet.*, **3**: 29-32.
3. COWDRY E.V., 1925. Studies on the aetiology of Jaagsiekte. *J. Expt. Med.*, **42**: 323-345.
4. CUTLIP R.C., YOUNG S., 1982. Sheep pulmonary adenomatosis (Jaagsiekte) in the United States. *Am. J. Vet. Res.*, **43**: 2108-2113.
5. DIGUARDO G., CONDOLEO R., AUTORINO L., 1992. Multicentric lymphosarcoma associated with pulmonary adenomatosis (Jaagsiekte), pulmonary lymphoid hyperplasia and lymphoid interstitial pneumonia in a ewe. *Vet. Path.*, **29**: 262-264.
6. DUALDE-PRERES C., 1963. Studies on ovine pulmonary adenomatosis in Spain. Proc. 17th World Vet. Cong. Hannover, Germany, 14-21 August 1963. **1**: 347-355.
7. GONZALEZ L., JUSTE R.A., CUERVO L.A., IDIGORAS L., SAEZ DE OCARIZ C., 1993. Pathological and epidemiological aspects of the coexistence of maedi-visna and sheep pulmonary adenomatosis. *Res. Vet. Sc.*, **54**: 140-146.
8. JUBB K.V.F., KENEDDY P.C., PALMER N., 1985. Pathology of Domestic Animals, 3rd ed., New York, NY, USA, Academic Press, Vol. 2.
9. LAIRMORE M.D., ROSADIO R.H., MARTINI J.C. DE, 1986. Ovine lentivirus lymphoid interstitial pneumonia. *Am. J. Path.*, **125**: 173-181.
10. MACKY J.M.K., 1969. Tissue culture studies on sheep pulmonary adenomatosis (Jaagsiekte). *J. Comp. Path.*, **79**: 141-146.
11. PALMARINI M., COUSENS C., DALZIEL R.G., BAI J., STEDMAN K., MARTINI J.C. DE, SHARP J.M., 1996. The exogenous form of jaagsiekte retrovirus is specifically associated with a contagious lung cancer of sheep. *J. Virol.*, **70**: 1618-1623.
12. PALMARINI M., DEWAR P., HERAS J.M. DE LAS, INGLIS N.F., DALZIEL R.G., SHARP J.M., 1995. Epithelial tumour cells in the lungs of sheep with pulmonary adenomatosis are major sites of replication for jaagsiekte retrovirus. *J. Gen. Virol.*, **76**: 2731-2737.
13. PALMARINI M., HOLLAND J.M., COUSENS C., DALZIEL R.G., SHARP J.M., 1996. Jaagsiekte retrovirus establishes a disseminated infection of the lymphoid tissues of sheep affected by pulmonary adenomatosis. *J. Gen. Virol.*, **77**: 2991-2998.
14. PERK K., 1982. Slow virus infection in ovine lung. *Adv. Vet. Sci. Comp. Med.*, **26**: 267-288.
15. ROSADIO R.H., SHARP J.M., LAIRMORE M.D., DAHLBERG J.E., MARTINI J.C. DE, 1988. Lesions and retroviruses associated with naturally occurring ovine pulmonary carcinoma (sheep pulmonary adenomatosis). *Vet. Path.*, **25**: 58-66.
16. SHIRLAW J.F., 1959. Studies on Jaagsiekte in Kenya. *Bull. Epiz., Dis. Afr.*, **7**: 287-302.
17. SMITH W., MACKAY J.M.K., 1969. Morphological observations on a virus associated with sheep pulmonary adenomatosis (Jaagsiekte). *J. Comp. Path.*, **79**: 421-424.
18. STEVENSON R.G., REHUMTULLA A.J., THOMSON R.G., 1980. Pulmonary adenomatosis (Jaagsiekte) in sheep in Canada. *Can. Vet. J.*, **21**: 267-286.
19. SYNDER S.P., MARTINI J.C. DE, AMEGHINO E., CALETTI E., 1983. Coexistence of pulmonary adenomatosis and progressive pneumonia in sheep in the central Sierra of Peru. *Am. J. Vet. Res.*, **44**: 1334-1338.
20. TOUMAZOS P., 1989. First report of sheep pulmonary adenomatosis in Cyprus. *Br. Vet. J.*, **145**: 289-290.
21. WANDRA J.G., 1971. Sheep pulmonary adenomatosis. *Adv. Vet. Sc. Comp. Med.*, **15**: 251-283.
22. YORK D.F., VIGNE R., VERWOERD D.W., QUERAT G., 1991. Isolation, identification and partial DNA cloning of genomic RNA of jaagsiekte retrovirus, the aetiological agent of sheep pulmonary adenomatosis. *J. Virol.*, **65**: 5061-5067.
23. YORK D.F., VIGNE R., VERWOERD D.W., QUERAT G., 1992. Nucleotide sequence of the jaagsiekte retrovirus, an exogenous and endogenous type D retrovirus of sheep and goats. *J. Virol.*, **66**: 4930-4939.

Reçu le 28.9.98, accepté le 23.11.99

Résumé

Ali O.A., Abdelsalam E.B. Adénomotose pulmonaire chez un ovin en Libye : description macroscopique et histopathologique

Les caractéristiques générales et histopathologiques d'adénomotose pulmonaire ovine ont été mises en évidence dans le poumon droit d'une brebis âgée de race Beriberi, qui souffrait de détresse respiratoire persistante. Ces caractéristiques étaient principalement la prolifération papillomateuse multifocale de l'épithélium alvéolaire, avec d'abondantes infiltrations alvéolaires des macrophages. Quatre cas semblables ont été identifiés à partir du matériel obtenu pendant dix années d'études histopathologiques sur la maladie dans la région de Tripoli.

Mots-clés : Ovin - Adénomotose pulmonaire - Carcinome - Poumon - Jamahiriya arabe libyenne.

Resumen

Ali O.A., Abdelsalam E.B. Adenomatosis pulmonar ovina (Jaagsiekte) en Libia: evidencia general e histopatológica

Características generales e histopatológicas indicativas de adenomatosis pulmonar ovina, fueron detectadas en el pulmón derecho de una vieja oveja hembra Beriberi, presentado dificultad respiratoria persistente. Estas fueron principalmente dominadas por proliferación papilomatosa multifocal del epitelio alveolar, asociada con abundantes infiltrados de macrófagos alveolares. Cuatro casos similares fueron detectados en durante diez años de estudio histopatológico de la enfermedad en el área de Trípoli.

Palabras clave : Ovino - Adenomatosis pulmonar - Carcinoma - Pulmones - Jamahiriya arabe libia.