

Rhabditic dermatitis in a bull apparently caused by *Pelodera strongyloides*

I. Yeruham ^{1*} S. Perl ²

Key words

Cattle - Bull - *Pelodera strongyloides* - Dermatitis - Rhabditidae.

Summary

Dermatitis probably caused by *Pelodera strongyloides* in a 4-year-old Charolais bull is described. Spontaneous recovery of the skin lesion on the abdomen occurred within four weeks of the animal being moved from the infected area.

INTRODUCTION

Rhabditic dermatitis is caused by a free-living nematode, *Pelodera strongyloides* (4), which is a saprophytic soil nematode. This nematode lives in wet, decaying bedding, moist soil and occasionally in bruised and moist skin. The disease is rare and is usually associated with keeping animals in filthy conditions, where they are constantly exposed to invasion by the free-living nematodes. The lesions are confined to areas which have been in contact with contaminated materials (9), and the nematode takes up residence in the hair follicles (9). *P. strongyloides* dermatitis has been described in dogs (2, 8, 11), horses (3), cattle (5, 7), sheep (1), guinea pigs (10) and humans (6). The nematode has also been found in the eye orbits of several rodent species (10).

To the authors' knowledge, *Pelodera* dermatitis had not been reported in the Mediterranean regions so far.

CASE HISTORY AND CLINICAL FINDINGS

A 4-year-old bull out of a group of 30 Charolais imported two years ago was presented at the school because of a skin lesion on the abdomen. A single affected area was observed on the abdomen, 12 cm in diameter, with marked skin thickening which became wrinkled with alopecia, and containing thick yellow caseous material. No scratching or licking of the lesion was detected.

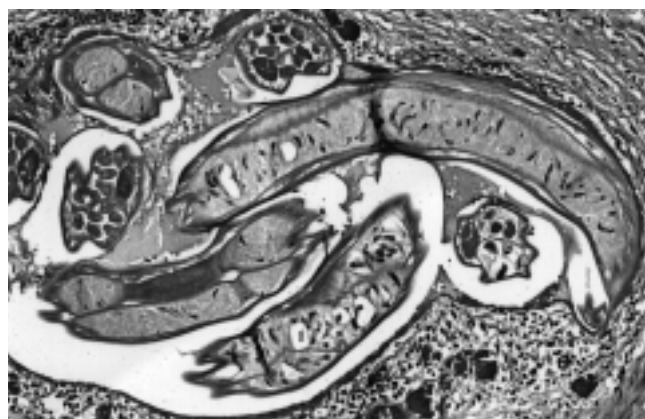


Figure 1: Longitudinal and transverse sections of *Pelodera strongyloides* larvae in the dermis with secondary inflammation (hematoxylin-eosin; x10).

A biopsy was taken with a 4 mm cutaneous punch after the site had been anesthetized by infiltration of 2% procaine. The tissue samples were fixed in 10% neutral buffered formaldehyde, serially sectioned, and stained with hematoxylin-eosin.

On histopathological examination, the hair follicles were found to contain transverse and longitudinal sections of small nematodes, keratotic material and nuclear debris (figure 1). The parasites were not confined to the hair shafts; they were also found within the space in the dermis. There was a dense perifollicular infiltration of inflammatory cells, histocytes and numerous eosinophils.

Microscopic examination of scrapings from the skin lesion revealed numerous motile larvae which could correspond to *P. strongyloides*, according to the description of Willers (11). No pathogenic bacteria or fungi were isolated from skin samples submitted for bacteriological and mycological examination. No treatment was attempted, and the affected animal recovered spontaneously within four weeks of the animals being moved to a new, clean and dry location with plenty of bedding.

1. "Hachaklait" Gadera and the Koret School of Veterinary Medicine, the Hebrew University of Jerusalem, POB 12, Rehovot 76100, Israel

2. The Kimron Veterinary Institute, Bet Dagan 50250 and the Koret School of Veterinary Medicine, the Hebrew University of Jerusalem, POB 12, Rehovot 76100, Israel

* Corresponding author: 4 Hagoren St., Gadera 70700, Israel

■ DISCUSSION

Dermatitis caused by *Pelodera strongyloides* is an uncommon skin disorder in cattle (5, 7). The disease is self-limiting and spontaneous recovery in cattle affected by *P. strongyloides* has been reported (5), as was the case in this study.

The bull had been imported two years before the skin lesion was observed, and therefore it is probable that the infestation with the free-living nematode occurred in the local farm where suitable environmental conditions exist for the development of nematodes. Hence, no treatment was attempted and spontaneous recovery occurred. Similar observations were reported elsewhere (5, 9).

In the parasitological examination of the skin scrapings only larvae of *P. strongyloides* were identified, contrary to the report of Levine *et al.* (5) who found also adult nematodes in scrapings from infested cattle. Lesions are generally confined to body areas which are in contact with damp, filthy bedding.

The histopathological findings in this bull were similar to those reported in dogs (9) and cattle (7). Considering the nature of the infection, the structure of the nematodes and the characteristic histopathological features, it appeared that the dermatitis was probably caused by *P. strongyloides*.

Although an apparently rare disease, *Pelodera* dermatitis should be considered in any differential diagnosis that includes ringworm and cutaneous onchocercosis (*Onchocerca ochengi*). Definitive identification should be based on adult worms cultivated from larvae in blood agar plate.

Résumé

Yeruham I., Perl S. Dermatite à Rhabditidés chez un taureau apparemment causée par *Pelodera strongyloides*

Une dermatite probablement causée par *Pelodera strongyloides* chez un taureau Charolais âgé de quatre ans est décrite. Les lésions dermiques au niveau de l'abdomen ont guéri spontanément quatre semaines après que l'animal ait été transféré hors de la zone infectée.

Mots-clés : Bovin - Taureau - *Pelodera strongyloides* - Dermatite - Rhabditidés.

REFERENCES

1. BERGELAND M.E., TODD K.S. Jr., OHLENDORF L.F., 1976. Dermatitis in sheep caused by *Pelodera strongyloides*. *Proc. Helminthol. Soc. Wash.*, **43**: 230-231.
2. BRIZARD A., EUZEBY J., 1949. Un cas de dermatose vermineuse du chien. *Revue Méd. vét.*, **100**: 82-86.
3. FARRINGTON D.O., LUNDVALL R.L., GREVE J.H., 1976. *Pelodera strongyloides* dermatitis in a horse in Iowa. *Vet. Med./Small Anim. Clin.*, **71**: 1199-1202.
4. LEVINE N.D., 1968. Nematode parasites of domestic animals and of man. Minneapolis, Minn., USA, Burgess Publishing.
5. LEVINE N.D., MILLER L.J., MORRILL C.C., MANSFIELD M.E., 1950. Nematode dermatitis in cattle associated with rhabditis. *J. Am. vet. Med. Assoc.*, **116**: 294-296.
6. PASYK K., 1978. Dermatitis rhabditidosa in an 11-year-old girl. A new cutaneous parasitic disease of man. *Br. J. Dermatol.*, **93**: 107-112.
7. RHODE E.A., JASPER D.E., BAKER N.F., DOUGLAS J.R., 1953. The occurrences of *Rhabditis* dermatitis in cattle. *North Am. Vet.*, **34**: 634-637.
8. SCHLOTTHAUSER C.F., ZOLLMAN P.E., 1955. The occurrence of *Rhabditis strongyloides* in association with dermatitis in a dog. *J. Am. vet. Med. Assoc.*, **127**: 510-511.
9. SCHWARTZMAN R.M., 1964. *Rhabditis* dermatitis in the dog. *J. Am. vet. Med. Assoc.*, **145**: 25-28.
10. TODD K.S. Jr., SEAMAN W.J., GRETSCHMANN K.W., 1982. *Pelodera strongyloides* dermatitis in a guinea pig. *VM/SAC*, **77**: 1400-1402.
11. WILLERS W.B., 1970. *Pelodera strongyloides* in association with canine dermatitis in Wisconsin. *J. Am. vet. Med. Assoc.*, **156**: 319-320.

Reçu le 24.2.98, accepté le 19.8.98

Resumen

Yeruham I., Perl S. Dermatitis larval en un toro, causada aparentemente por *Pelodera strongyloides*

Se describe un caso de dermatitis, provocada posiblemente por *Pelodera strongyloides* en un toro Charolais de 4 años de edad. Las lesiones curaron espontáneamente, cuatro meses después de que el animal fue trasladado fuera de la zona infectada.

Palabras clave: Ganado bovino - Toro - *Pelodera strongyloides* - Dermatitis - Rhabditidae.