

Tunga penetrans (Insecta: Siphonaptera) in pigs in São Tomé (Equatorial Africa): Epidemiological, clinical, morphological and histopathological aspects

S. Pampiglione ^{1*} M. Trentini ² F. Mattei Gentili ³
J.L.X. Mendes ⁴ C. Pampiglione ² F. Rivasi ⁵

Key words

Mankind - Swine - *Tunga penetrans* - Symptoms - Histopathology - Body conformation - Epidemiology - São Tomé and Príncipe.

Summary

The island of São Tomé, a former Portuguese colony, located in the Gulf of Guinea, is nowadays part of an independent republic, the Republic of São Tomé and Príncipe. A survey carried out by the authors on swine slaughtered at the public slaughterhouse of the capital has ascertained that 28 subjects out of 100 examined were affected by lesions associated with *Tunga penetrans* (Insecta: Siphonaptera) localized particularly in the legs, snout and udders. In the latter the presence of fleas inside the tissues of the teats caused heavy economic damage due to inability to nurse the sucking-pigs, resulting in the death of whole litters. Human cases were frequently reported on the island posing a real public health problem. One of the authors, too, was affected by the parasite. It can be assumed that swine act as a reservoir of chigoes in São Tomé, as was observed in many villages of Latin America. Photographic records of the clinical and histological aspects of the lesions and of the morphology of the parasite are presented.

■ INTRODUCTION

Tunga penetrans (Insecta: Siphonaptera), commonly called sand-flea, chigoe or chigger flea, is an insect parasitizing man and various domestic and wild warm-blooded vertebrates. It is present in many regions of Latin America where it originated from, and from which it spread to almost all of Africa, Madagascar and some regions of Asia (1).

Whereas males and non-fertilized females behave as hematophagous ectoparasites, pregnant females, by a mechanism peculiar to this genus, which has been studied in detail since the

last century (2, 13, 14, 20), penetrate the depth of the skin where, following the dilation of the intestine and Malpighian tubules (9) and the development of eggs (12), enlarge up to the size of a pea in about two weeks and provoke more or less invalidating inflammatory and ulcerative processes. As a rule, the parasite lesions, although of benign nature if properly treated, may represent a portal of entry for other infections including tetanus (3). Once mature, the eggs, more than 200 per female (9, 12), are released and fall to the ground, where larval stages will develop by feeding on decaying organic matter and transform into pupae after 10 to 18 days (10) or more (9) and eventually into adults, thus completing the cycle.

The international literature frequently reports human cases contracted in endemic areas in autochthonous populations or in non-endemic regions in persons coming back from such areas. Publications in the veterinary sector and reports on zootechnical damage associated with the parasite are however scanty (1, 4, 6, 19) although it has been ascertained that this disease is a true zoonosis with its reservoir in swine (2, 7, 16, 17) (in some countries, e.g. Brazil, the parasite is commonly called *bicho de porco*) or, more rarely, in the dog (18).

1. Department of Veterinary Public Health, University of Bologna, Italy

2. Department of Biology, University of Bologna, Italy

3. Veterinary Practitioner, Padua, Italy

4. Direction of Veterinary Services, Ministry of Agriculture, Democratic Republic of São Tomé and Príncipe

5. Department of Morphological Sciences, University of Modena, Italy

* Corresponding author: Dipartimento di Sanità Pubblica Veterinaria e Patologia Animale, Università di Bologna, Via Tolara di Sopra, 40064 Ozzano Emilia, Italia

Tel.: 0039-51-792002 or 792063; Fax: 0039-51-792039

Tunga penetrans in pigs in São Tomé

Having had the opportunity to see several cases of the condition in swine on the island of São Tomé and to collect substantial parasitological material, the authors thought it was useful to report the presence of the parasite in a geographic area not yet indicated as endemic and to illustrate its clinical, morphological and histopathological aspects.

The Island of São Tomé, along with the Island of Príncipe and a few other small islands, is part of a little volcanic archipelago in the Gulf of Guinea, west of the African coast (between 1°44' Lat. N and 0°22' Lat. S and between 7°28' and 6°28' Long. E). It has been an independent state, the Democratic Republic of São Tomé, since 1975.

It has a surface of 844 km². The landscape is exceedingly varied depending on the diversity of its profile, with a mountain in its occidental half, 2024 m high and covered with luxuriant vegetation of equatorial type, which leans abruptly to the sea while in the eastern part the land slopes down and becomes a plain with aspects ranging from savannah to semi-arid areas. The climate of the northern coastal strip is characterized by two seasons, wet from September to May and dry from June to August. The rest of the territory has an equatorial climate with rainfall throughout the year sometimes averaging 7000 mm/year. Relative humidity varies according to the different zones from a minimum of 65.3% to saturation. Average yearly temperature is 25.7°C with differences of 3°C between the hottest and coldest months (data collected at the Ministry of Agriculture of São Tomé).

The population numbers 96,611 inhabitants (census of 1981) with a mean density of 97 inhabitants/km², mainly farmers. The most widespread culture is cacao (practically a monoculture), although coffee, coconut palms, pineapples, etc. are grown in small plots of land. The population lives in urban settlements or in farms and sparse small rural centers. Sanitary conditions are very poor, due to the shortage of toilets and the strong fecal pollution of the environment (15), which consequently affect the population's health.

The livestock population (1992) consists of 500 cattle, 400 swine, 28,000 goats, 100 sheep and 12 horses. As to swine, a serious outbreak of African swine fever occurred in 1986 on the occasion of a project for the introduction of Large White pigs into the island. A stamping-out program was implemented which actually affected only freshly-introduced pigs in state farms, whereas small, family-run farms were not involved at all as the owners let their animals run to the forest in order not to have them killed. This seems not to have had a negative impact since no new cases of the disease were reported in subsequent years and, after recovering the pigs from the forest, the swine population was restored fairly rapidly. Pigs in family farms are reared free range and allowed to move around the houses (figure 1) and sometimes in the brushwood so that they can feed on waste and cooking refuse or on edible vegetables found in the island's forest environment.

■ MATERIALS AND METHODS

The pigs examined (100 head consisting of 66 males and 34 females aged 6 to 18 months) all came from small herds of the family type sited in the districts of Agua Grande, Lobata, Mesoxi and Lemba. They were all crossbred and had been taken to the public abattoir for slaughter from January to March 1992. These were all the pigs slaughtered during this period under veterinary control.



Figure 1: Pigs kept free to circulate among the houses in São Tomé.

The animals were first examined clinically, as a naked-eye diagnosis is easy, due to the obvious lesions which, if present, are typical of the disease. Biopsy samples were taken both to confirm clinical diagnosis and to study the histopathology of the lesions and the parasite's morphology in more detail. This material was fixed in buffered 10% formalin and histological sections were stained with hematoxylin-eosin, PAS and Trichromic Masson Goldner.

■ RESULTS

Clinical and epidemiological findings

Out of 100 pigs examined, 28 (10 males and 18 females) showed typical lesions of *Tunga penetrans*, always several in number, sometimes arranged in a carpet-like fashion, consisting of tens or hundreds of small protuberances and crater-shaped ulcerations giving the skin surface a pitted, warty or honeycomb-like aspect. The most affected age class (60% of positive cases) was under one year old. No significant differences were seen between sexes except for localization, which was more frequent in the udders of females. The lesions were sometimes present in the snout (85.7%) (figure 2) and teats (46.4%) (figure 3), the latter sometimes showing necrotic processes with partial mutilation and contemporary mammary obstruction and mastitis, but in all cases they were present in the legs (figure 4). The occasional presence of *T. penetrans* was also observed in the legs of a goat and in the foot-pad of a cat as well as in the soles and toes of some farmers and of one of the authors of this paper.

Morphological and histopathological aspects

Cross-sections of the parasites (figure 5) showed the external cuticle with the hypoderma delimiting the enlarged abdomen, the anterior end, much smaller than the rest of the body, consisting of the head and thorax, and sometimes the posterior end with the last abdominal segments. Some sections of the head showed the pigmented eyes and a portion of the biting-suckling buccal apparatus immersed in the derma (figure 6). In the thoracic area sections of the legs were seen. Within the abdominal cuticle, in a more or less enlarged body according to the stage of development, one could observe some bundles of striated, hypertrophic muscular

fibers (figure 7), which started from the thorax and penetrated the abdomen joining the cuticle peripherally. Sections of the digestive tract were also seen containing amorphous material and granulocytes, as well as numerous small tracheae and sexual tubules containing eggs at different stages of maturation.

Microscopic examination of the sections showed skin lesions around the chiggers according to different phases of penetration and development of the parasite. These were always ulcerated or microulcerated, with the presence of parts of well-preserved insects or their residues more or less altered by regressive processes.

At the cutaneous level, there was usually a conspicuous inflammatory infiltration of the acute type, consisting prevalently of eosinophilic granulocytes. Chronic inflammatory changes were also present with lymphocytes, plasmacells and fibroblasts. Newly formed capillary vessels were also seen with thin walls suggesting a pronounced congestion of the area. The presence of some hemorrhagic foci, edematous zones and microabscesses due to possible superimposed bacterial infections were also observed.

The epithelial layer, frequently showing acanthosis and hyperkeratosis with a markedly irregular surface, was often ulcerated showing different evolutive stages. In some areas, the horny layer, considerably thinned, covered the parasite's body almost completely, so that it was deeply inserted into the basal superficial layers of the host and communicated with the outside through a small foramen that had obviously allowed the parasite to breath.

Some fields showed larger cutaneous ulcers with walls containing a granulation tissue incorporating chitinous fragments of the insect's exoskeleton and microsupsurative foci consisting of exudative-necrotic, fibrinous-leukocytary material.

■ DISCUSSION

Tungiasis in man has been reported in São Tomé since the beginning of this century: Enderlein (8) reported a case in a foot of a Black person without indicating his information source. To our knowledge, the literature consulted does not report investigations or descriptions of other cases in subsequent periods. We may, however, hypothesize on the basis of the first case and the frequent movements of the population between São Tomé and Angola, the latter being one of the first zones infested by the



Figure 2: Lesions by *Tunga penetrans* on the snout of a pig.

parasite in Africa (11), that the condition has been present and probably spread in the island since the beginning of this century.

At present, tungiasis is a serious public health problem in São Tomé involving both swine and man. The parasite seems to be frequent especially in children, as the fact was mentioned by some school teachers. The pig farming methods which allow the animals to move freely among the houses in search of waste, as well as the very limited use of shoes by the inhabitants, especially children, result in a large diffusion of the disease due to a wide dissemination of eggs over the ground. It may be assumed that,



Figure 3: Lesions by *Tunga penetrans* in the teats of a sow.

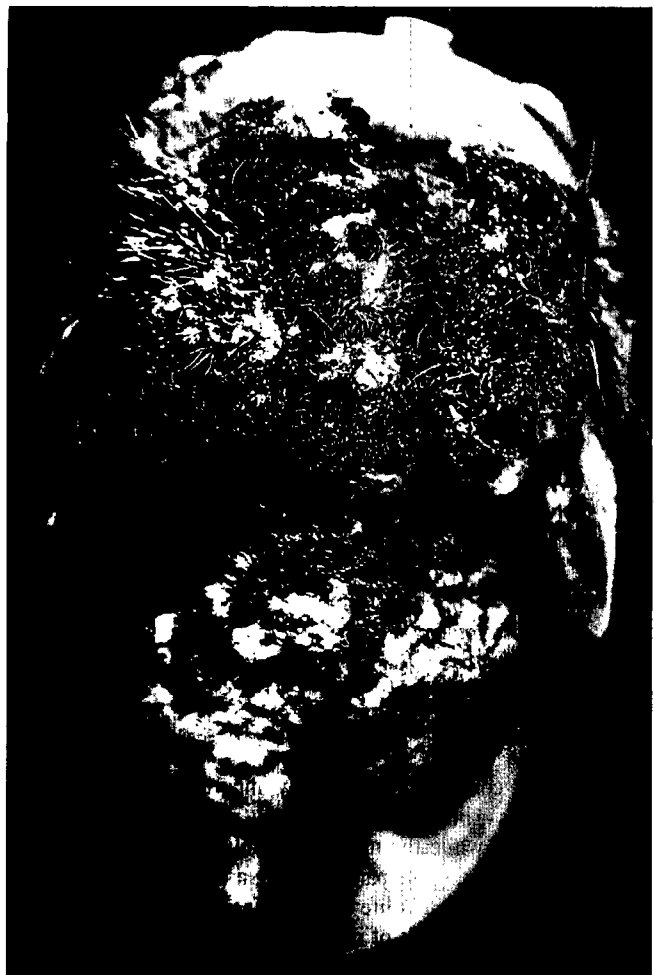

Figure 4: A foot of swine seriously affected by *Tunga penetrans*.

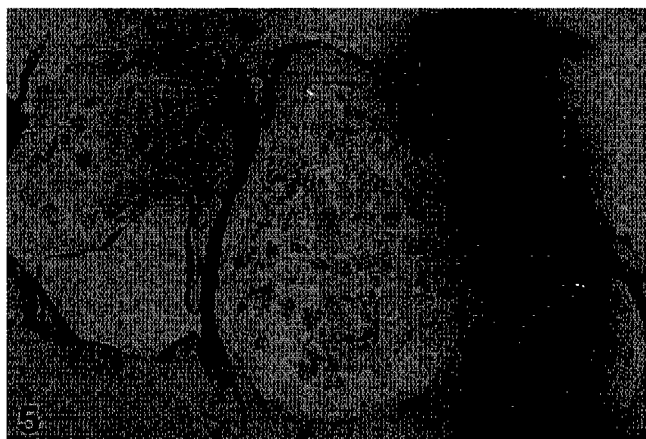


Figure 5: Histological section showing 3 *Tunga penetrans* embedded into the skin of a swine (Trichromic Masson Goldner, x 25).

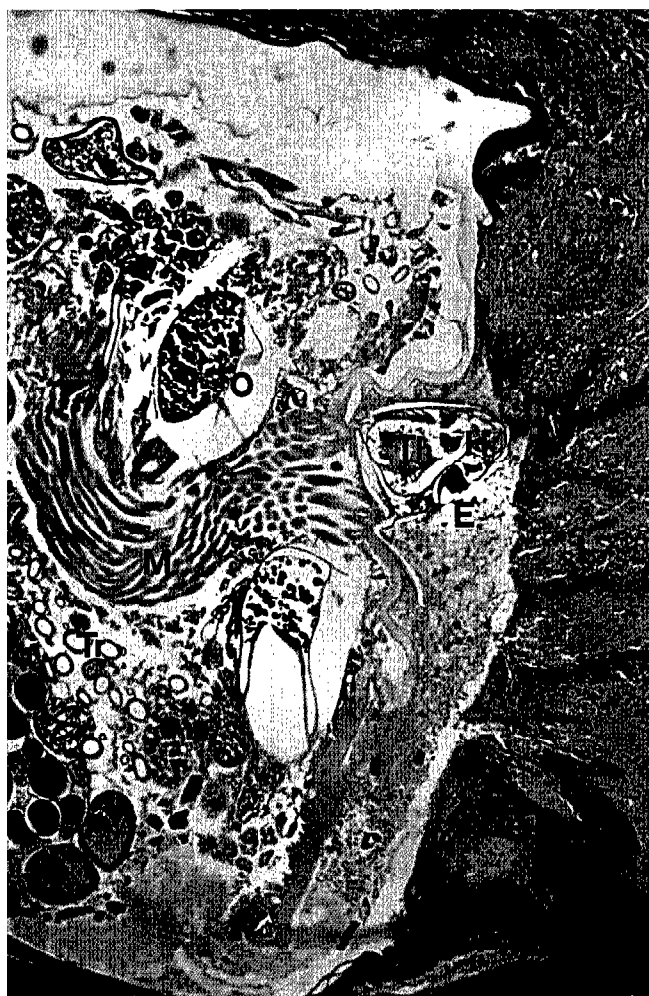

Figure 6: Histological section of *Tunga penetrans* (Trichromic Masson Goldner, x 62). E = eye, H = head, M = muscle fibers, O = ovary, Th = thorax, Tr = tracheae.

in the past, the condition was probably imported into the island by infected persons, but pigs are certainly now a reservoir of the disease. In fact, while the natives can rely on self-treatment by immediately removing the parasite using a thorn or a needle, thus interrupting the parasite's life cycle, swine passively undergo the establishment of hundreds of insects in their skin without defense, and spread thousands of eggs over the ground with their movements among the houses.

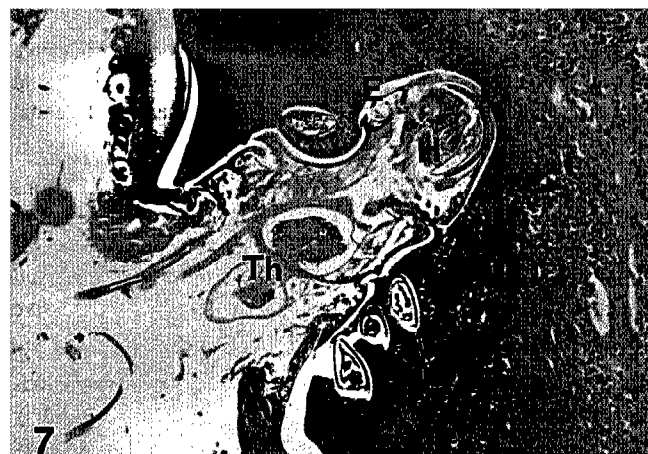

Figure 7: A detail of the head and thorax of *Tunga penetrans* (PAS, x 125). E = eye, H = head, L = legs, Th = thorax.

In São Tomé, the disease in swine is strongly debilitating, with lameness and painful infestation of the snout in both sexes and, in females, painful lesions of the teats with frequent inflammatory or necrotic complications. Parasitism of the latter location often results in the mother's inability to nurse the litter, leading to the death of all piglets. This situation was shown to be one of the reasons why farmers have their sows slaughtered, as indicated by their own accounts.

Four foci of tungiasis reported in swine in Africa in the literature were identical to those of São Tomé due to similar conditions of both the environment and farming methods with mass infestation and loss of litters. In another outbreak in a model farm in Tanzania (4, 5), no animal exhibited extensive inflammatory processes or serious consequences thanks to a timely diagnosis and an immediate, successful treatment. It is obvious that the situation in São Tomé is due to the primitive type of farming, depressed socioeconomic conditions of the population and farmers' ignorance of the parasite's life cycle and the ways to interrupt it. No empirical treatment appeared to be utilized on the island. The control or even eradication of the condition on São Tomé might be noticeably improved by health authorities educating farmers to enable them to promptly diagnose and treat the disease in affected swine, as well as distributing antiparasitic ointments or lotions at low prices through veterinary services.

A finding of this investigation contrasting with the reports of other authors is that the pigs studied here were generally kept on muddy, damp soil, whereas since Blanchard's studies in 1890 (2) it has always been stated that *T. penetrans* needs dry, sandy soils to develop into larval stages.

Acknowledgments

Thanks are due to the Minister of Agriculture and the Minister of Health of the Republic of São Tomé and Príncipe for supporting our research and arranging the stay of some of the authors on the Island. Thanks are also due to the personnel of the Public Abattoir for their technical assistance.

REFERENCES

1. AVILA-CONZALEZ J., 1977. Reporte sobre un brote de niguasis en el ganado porcino de la población de Yaxcaba, Yucatán. Aspectos zoonóticos del mismo. *Mem. I Simp. Intern. Lab. Diagn. Mexico*, 3: 776-779.
2. BLANCHARD R., 1890. *Traité de zoologie médicale*, tome II. Paris, France, Baillière et Fils, p. 484-493.

3. BRUMPT E., 1949. Précis de parasitologie, 6^e ed, tome II. Paris, France, Masson, p. 1323-1325.
4. COOPER J.E., 1967. An outbreak of *Tunga penetrans* in a pig herd. *Vet. Rec.*, **80**: 365-366.
5. COOPER J.E., 1976. *Tunga penetrans* infestation in pigs. *Vet. Rec.*, **98**: 472.
6. DIPEOLU O.O., 1975. Ectoparasites of local pigs in Western Nigeria. *Niger. J. Anim. Prod.*, **2**: 222-226.
7. DURAN C., SOTO ALFARO J.M., PICADO C., 1916. Biología de la Nigua. *An. Hosp. S. José Costa Rica*: 1-17.
8. ENDERLEIN G., 1901. Zur Kenntniss der Flohe und Sanflohe. *Zool. Jahrb. Syst.*, **14**: 549-557.
9. GEIGY R., HERBIG A., 1949. Die Hypertrophie der Organe beim Weibchen von *Tunga penetrans*. *Acta trop.*, **6**: 246-262.
10. HICKS E.P., 1931. The early stages of the Jigger, *Tunga penetrans*. *Ann. trop. Med. Parasitol.*, **24**: 575-586.
11. HOEPLI R., 1963. Early references to the occurrence of *Tunga penetrans* in tropical Africa. *Acta trop. (suppl.1)*, **20**: 143-153.
12. JORDAN K., 1956. Suctoria. I. Tungidae. In: Smart J. Ed., 3rd ed., A handbook for the identification of insects of medical importance. London, UK, British Museum, p. 229-231.
13. MANSON P., 1893. The chigger or sand-flea (*Pulex penetrans*). In: Davidson's Hygiene and diseases of warm climates. Edinburg, London, UK, Young J. Pentland Publ., p. 963-966.
14. MONIEZ R., 1889. Les parasites de l'homme (animaux et végétaux). Paris, France, Baillière et Fils, p. 251-256.
15. PAMPIGLIONE S., VISCONTI S., PEZZINO G., 1987. Ricerche sui parassiti intestinali dell'uomo in Africa Subsahariana. II: São Tomé e Príncipe. *Parassitologia*, **29**: 15-25.
16. PATTON W.S., 1931. Insects, ticks, mites and venomous animals of medical and veterinary importance. Part II, Public Health. Croydon, UK, Grubb Ltd, p. 653-657.
17. PESSOA S.B., 1958. Parasitologia médica, 5a ed., Rio de Janeiro, Brasil, Guanabara Koogan, p. 902-903.
18. RIETSCHER W., 1989. Beobachtungen zum Sandfloh (*Tunga penetrans*) bei Mensch und Hund in Französisch Guayana. *Tierarztl.*, **17**: 189-193.
19. VERHULST A., 1976. *Tunga penetrans* (*Sarcopsylla penetrans*) as a cause of agalactia in sows in the Republic of Zaire. *Vet. Rec.*, **98**: 384.
20. WESTWOOD J.O., 1840. On the characters of the chigoe or jigger. *Trans. Entomol. Soc. London*, **2**: 199-203.

Reçu le 15.6.98, accepté le 21.10.98

Résumé

Pampiglione S., Trentini M., Mattei Gentili F., Mendes J.L.X., Pampiglione C., Rivasi F. *Tunga penetrans* (Insecta : Siphonaptera) chez le porc à São Tomé (Afrique équatoriale) : aspects épidémiologiques, cliniques, morphologiques et histopathologiques

L'île de São Tomé, une ancienne colonie portugaise située dans le Golfe de Guinée, fait partie aujourd'hui d'une république indépendante, la République de São Tomé et Príncipe. Une enquête réalisée sur des porcs abattus à l'abattoir public de la capitale a établi que, sur 100 sujets examinés, 28 étaient affectés par des lésions provoquées par *Tunga penetrans* (Insecta: Siphonaptera), localisées particulièrement dans les pattes, le museau et les mamelles. La présence également de puces dans l'épaisseur des mamelons a provoqué des pertes économiques importantes car ces conditions ont empêché l'allaitement des porcelets, entraînant ainsi la mort de nichées entières. Des cas humains ont été reportés fréquemment dans l'île, cette parasitose constituant un vrai problème de santé publique. Un des auteurs a été infecté lui même par le parasite. Il semble que le porc représente un réservoir de *T. penetrans* à São Tomé, comme cela a pu être observé dans de nombreux villages d'Amérique latine. Les auteurs présentent les images photographiques des manifestations cliniques, du tableau histologique des lésions et de la morphologie du parasite.

Mots-clés : Genre humain - Porcin - *Tunga penetrans* - Symptômes - Histopathologie - Conformation animale - Epidémiologie - São Tomé et Príncipe.

Resumen

Pampiglione S., Trentini M., Mattei Gentili F., Mendes J.L.X., Pampiglione C., Rivasi F. *Tunga penetrans* (Insecta: Siphonaptera) en cerdos en Santo Tomé (Africa ecuatorial). Aspectos epidemiológicos, clínicos, morfológicos e histopatológicos

La isla de Santo Tomé, antigua colonia portuguesa, localizada en el Golfo de Guinea, es actualmente parte de una república independiente, la República de Santo Tomé y Príncipe. Los autores realizaron un estudio sobre los suidos sacrificados en el matadero público de la capital, el cual demostró que 28 de los 100 individuos examinados se encontraron afectados por lesiones asociadas con *Tunga penetrans* (Insecta: Siphonaptera), localizadas principalmente en las patas, hocico y ubres. En esta última, la presencia de pulgas adentro de los tejidos de los pezones causó unas fuertes pérdidas económicas, debido a la incapacidad de alimentar a los lechones lactantes, conduciendo a la muerte de toda la camada. Se reportaron frecuentemente casos en humanos en la isla, representando un verdadero problema para salud pública. Uno de los autores se encontró también afectado por los parásitos. Se puede asumir que los suidos actúan como reservorio en Santo Tomé, tal y como se observó en varios pueblos de América latina. Se presentan estudios fotográficos de los aspectos clínicos e histológicos de las lesiones y de la morfología del parásito.

Palabras clave: Genero humano - Cerdo - *Tunga penetrans* - Síntomas - Histopatología - Conformación animal - Epidemiología - Santo Tomé y Príncipe.