

Communication

Lumpy skin disease : Observations on the recent outbreaks of the disease in the Sudan

A.I. Khalafalla¹M.A. Gaffar Elamin¹Z. Abbas¹

KHALAFALLA (A.I.), GAFFAR ELAMIN (M.A.), ABBAS (Z.).
Récentes épidémies de dermatose nodulaire contagieuse bovine observées au Soudan. *Revue Elev. Méd. vét. Pays trop.*, 1993, **46** (4) : 548-550

Des épidémies de dermatose nodulaire contagieuse bovine observées chez des vaches de races Frisonne et locale dans l'Etat de Karthoum durant la période 1989-1991 sont décrites ici. La maladie a été diagnostiquée grâce à l'examen clinique, à l'isolement et l'identification du virus, au microscope électronique. Les signes cliniques étaient les suivants : fièvre, écoulement nasal, apparition de multiples nodules cutanés de diverses tailles, œdème des membres inférieurs et de la poitrine, avortements. La maladie était sévère chez les bovins de pure race Frisonne, avec un taux de morbidité de 37,9 p. 100 et un taux de mortalité de 4,2 p. 100 tandis qu'elle était assez modérée chez les bovins de race locale.

Mots-clés: Bovin - Bovin Frison - Dermatose nodulaire contagieuse - Diagnostic - Épidémiologie - Soudan.

Introduction

Dairy farming is becoming very important in the Sudan. Many dairy farms have been recently established and high milk yielding cattle breeds have been introduced in a National upgrading programme of indigenous breeds. One of the major problems facing this upgrading programme is the infectious diseases which are endemic in the country.

Lumpy skin disease (LSD) in the Sudan was first reported in 1971 (2) and the causative virus (capripoxvirus) isolated from cases in various parts of the country. The objective of the present study was to investigate into the recent outbreaks of LSD in the country with special reference to clinical and epidemiological features in affected animals.

Materials and Methods

The disease was thought to originate from an area South of Khartoum ; it appeared after the rainy season in 1989. In December 1989, it was reported in a large dairy farm South East of Khartoum. This farm belongs to the Arab Company for Livestock Development (ACOLID) and keeps 1882 imported Friesian cattle of different ages raised under local conditions. The disease was later obser-

ved in the small dairy farms of the Kuku dairy project involving indigenous, imported Friesian and crossbred cattle. The project covers a wide area, East of Khartoum and the disease continued to spread to the North and East of Khartoum until October 1991 when no more new outbreaks were reported.

Affected animals were examined clinically and epidemiological data collected. Post-mortem examination was carried out immediately after death in some animals. Biopsies were collected from skin nodules of affected animals and processed for histopathological analysis, electron microscopy, virus isolation and identification, as previously described (2, 11).

Results

Laboratory investigations

The histopathological findings were similar to those reported for LSD by ALI *et al.* (1), BIDA (3) and BURDEIN (4). The LSD virus was isolated and identified in cell culture and confirmation was obtained by electron microscopy (fig. 1).

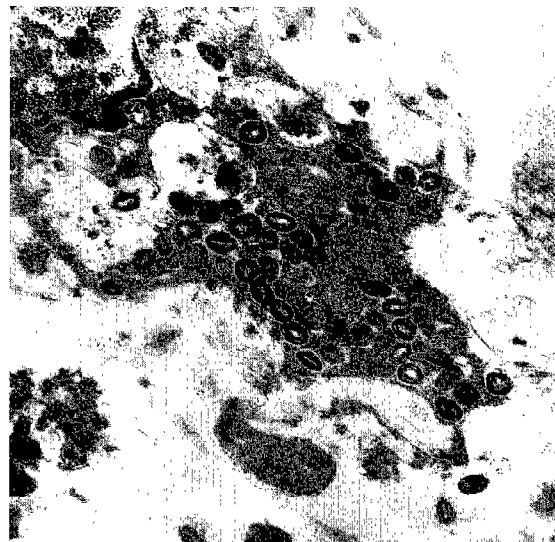


Figure 1 : Electron micrograph showing lumpy skin disease virus particles in skin biopsy (x 14,400).

Clinical findings and epidemiological data

The disease was initially characterized by inappetance and a sharp rise in body temperature (40-42°C), nasal discharge and salivation for 2-3 days, when skin rashes began to appear. Young animals usually died at this stage. The skin rashes soon developed into nodules, 0.5 to 5 cm in diameter, which appeared on the neck, brisket, back and thighs. Occasionally nodules were seen on the udder, vulva, scrotum and around the eyes and lips. A

1. Central Veterinary Research Laboratories, SOBA, POB 8067, Elamarat, Khartoum, Soudan.

Reçu le 16.3.1993, accepté le 16.9.1993.

generalized form of the disease with nodules all over the body appeared to be of common occurrence (photo 1). Oedema of legs and brisket and enlargement of lymph nodes were frequently observed and 3-6 % of pregnant cows aborted. The number of animals at risk, as well as morbidity and mortality rates in imported Friesian cattle at the ACOLID dairy farm are shown in table I. In this farm the disease caused a morbidity rate of 37.9 % and a total mortality rate of 4.2 % and 10 cases of abortion.

In the farms of the Kuku dairy project, the pattern of the disease in imported Friesian cattle was similar to that observed at the ACOLID farm. However, the morbidity in local breeds was estimated to 15 % with no recorded deaths. Post-mortem examinations showed that pneumonia was the most commonly observed lesion.



Photo 1 : A five-year old cow with generalized skin nodules.

TABLE I Pattern of lumpy skin disease outbreak in imported Friesian cattle at ACOLID dairy farm.

	Number of Animals involved	Animals with clinical disease		Deaths		Case Fatality Rate (%)
		Number	%	Number	%	
Adults	1,040	527	50.6	45	4.3	8.5
Calves	619	132	21.3	9	1.4	6.8
New born	223	56	25.1	26	11.6	46.4
Total	1,882	715	37.9	80	4.2	11.2

Discussion

The present outbreaks were caused by the Neethling-type virus of the lumpy skin disease, as suggested by the histopathological and electron microscopical findings in addition to virus neutralization.

The clinical signs observed in the present outbreaks are similar to those mentioned by ALI *et al.* (1), ALI and OBEID (2) and are in accordance with previous outbreaks (1, 5, 8). All age groups were affected, but death rates in newborn calves were relatively high (11.6 %) and probably due to pneumonia.

The economic importance of LSD in indigenous cattle was not presumed to be very large as it took a milder form and often led to complete recovery. On the other hand, in the exotic imported breeds the disease showed a severe progressive form which frequently terminated fatally. In these purebred Friesian animals, abortion usually occurred in severely affected cows and most of the aborted animals died, probably due to secondary complications.

The transmission routes were not studied in the present outbreaks. However, they were associated with a large number of flies and mosquitoes and with crowded animal enclosures. These observations suggest insect transmission. Aerosol transmission was also supported by the presence of nasal discharge and salivation in affected animals which consequently contaminated the environment and produced virus aerosol.

Since LSD is endemic in Africa including Sudan, it seemed reasonable to speculate that a high percentage of the Sudanese cattle had an earlier infective experience with the causative agent which is known to induce live-long immunity (9). Another explanation to the severity of LSD in imported Friesian cattle could be that the exotic breeds with a thinner skin opposite to the thick-skinned indigenous African ones are more predisposed to the development of severe lesions due to the disease (6).

Despite the fact that outbreaks of LSD continue to occur in the country since 1971, no National programme of control has been adopted. A local strain of LSD has been selected at this Institute to develop a candidate vaccine through serial passages in cell culture. However, this process is still underway.

A recent policy has been adopted by the veterinary authorities to improve the dairy industry by introducing high-milk yielding cattle breeds. However, such a policy has to consider the risk of LSD reported in this study and the vaccination programme of imported cattle should include this disease.

Acknowledgements

The authors are grateful to Mr. SAYED YOUSIF and Miss Wafa SALIH for their technical assistance in electron microscopy. We are indebted to Drs M. ABBAS, Y. ABDEL RAOOF and M.E. MAHGOOD for their interest and cooperation.

Communication

References

1. ALI (A.A.), ESMAT (M.), ATTIA (H.), SELIM (A.), ABDEL HAMID (Y.M.). Clinical and pathological studies of lumpy skin disease in Egypt. *Vet. Rec.*, 1970, **127** : 549-550.
2. ALI (B.H.), OBEID (H.M.). Investigation on the first outbreaks of lumpy skin disease in the Sudan. *Br. Vet. J.*, 1977, **133** : 184-189.
3. BIDA (S.A.). Confirmation by histopathological of the probable widespread of lumpy skin disease (LSD) in Nigeria. *Bull. Anim. Hlth Prod. Afr.*, 1977, **25** : 317-324.
4. BURDEN (M.L.). The use of histopathological examinations of skin material for the diagnosis of lumpy skin disease in Kenya. *Bull. epizoot. Dis. Afr.*, 1959, **7** : 27-36.
5. HAIG (D.A.). Lumpy skin disease. *Bull. epizoot. Dis. Afr.*, 1957, **5** : 421-430.
6. PIERRE (F.). La maladie nodulaire cutanée des bovins en Côte-d'Ivoire. *Revue Élev. Méd. vét. Pays trop.*, 1978, **31** (3) : 281-286.
7. VAN ROOYEN (P.J.), MUNZ (E.K.), WEISS (K.E.). The optimal condition for the multiplication of Neethling-type lumpy skin disease virus in embryonating eggs. *Onderstepoort J. vet. Res.*, 1969, **36** : 165-174.
8. WEISS (K.E.). Lumpy skin disease. In : GARD (S.), HALLAUER (C.), MEYER (K.F.) Eds. Virology monographs. Vol. 3. New York, Springer Verlag, 1968. p. 111-131.
9. WOODS (J.A.). Lumpy skin disease. A review. *Trop. Anim. Hlth Prod.*, 1988, **20** : 11-17.

KHALAFALLA (A.I.), GAFFAR ELAMIN (M.A.), ABBAS (Z.). Lumpy skin disease : Observations on the recent outbreaks of the disease in the Sudan. *Revue Élev. Méd. vét. Pays trop.*, 1993, **46** (4) : 548-550

Outbreaks of lumpy skin disease in imported Friesian and indigenous cattle which occurred in the Khartoum State during the period of 1989-1991, are described. The disease was diagnosed from clinical findings, isolation and identification of the virus and from electron microscopy. Clinical findings included pyrexia, nasal discharge, appearance of multiple skin nodules of varying sizes, oedema of legs and brisket and abortion. The disease in purebred Friesian cattle was severe with a morbidity rate of 37.9 % and a mortality rate of 4.2 % while it was rather mild in indigenous cattle.

Key words : Cattle - Friesian cattle - Lumpy skin disease - Diagnosis - Epidemiology - The Sudan.