

G.N. Isitor¹C.O. Njoku¹A.O. Adogwa¹A.O. Oyekan¹

Study of efficacy of Lamstreptocide A & B on cases of dermatophilosis within the Caribbean

ISITOR (G.N.), NJOKU (C.O.), ADOGWA (A.O.), OYEKAN (A.O.). Étude sur l'efficacité du Lamstreptocide A et B sur des cas de dermatophilose dans les Caraïbes. *Revue Élev. Méd. vét. Pays trop.*, 1993, 46 (1-2) : 303-308

L'efficacité du Lamstreptocide A et B a été étudiée sur 9 cas naturels de dermatophilose bovine et caprine dans 8 fermes différentes de Saint Kitts, par des méthodes histopathologiques et bactériologiques classiques. Les lésions de 5 des ruminants traités ont séché et les croûtes d'un animal gravement atteint se sont décollées considérablement, laissant apparaître un tissu érythémateux, 3 semaines après l'application du produit. En dehors de 3 cas sans gravité qui n'ont pu être suivis et qui seraient guéris, aucun des 5 animaux n'était véritablement guéri 3 semaines après le traitement, ni même après une deuxième application du produit. Un test *in vitro* sur la sensibilité au produit appliqué en surface de gélose, à des concentrations de plus de 1 p.100, a révélé un ralentissement de la croissance de *Dermatophilus congolensis*. Néanmoins, il n'y avait pas d'inhibition de la croissance de la bactérie par des disques de papier filtre imprégné.

Mots clés : Bovin - Caprin - Dermatophilose - *Dermatophilus congolensis* - Isolement - Lésion - Maladie de la peau - Bactéricide - Thérapeutique - Caraïbes - Saint-Kitts.

INTRODUCTION

Dermatophilosis is a chronic dermatitis of domesticated animals, in particular the ruminant species. The devastating effects of the condition, hide depreciation, overall decreased productivity (lowered fertility and increased culls, etc.), can hardly be ignored while pursuing policies aimed at combating the menace posed by the disease. On the contrary, past research efforts appeared skewed in the direction of multiple endless laboratory investigations with meagre contents of therapeutic procedures.

Given this background of abundant laboratory data on dermatophilosis, but with no reliable therapeutic or prophylactic regime at present, it is not surprising that in recent times there is an upsurge in attempts to formulate therapeutic products for the condition, regardless of scientific protocols. Lamstreptocide A & B represents one of such products the efficacy of which has been widely publicized by the producers at the National Veterinary Research Institute, Vom, Nigeria, but seems to have been minimally subjected to the crucible of tedious scientific testing prior to its being marketed in Nigeria.

The producers (5) claimed an average cure rate of 93 % by the product when topically applied on cases of dermatophilosis. The product which represents a mixture of ferruginous clay and oil extracted from *Khaya* spp. was also accredited with insect repellent properties as well as efficacy on mange in rabbits, caprine fungal infections, and multiple dog skin infections.

The present investigation is a pilot attempt to verify the claim of efficacy of the product under the Caribbean climatic conditions.

MATERIALS AND METHODS

Field studies and treatment trials

Clinical evaluation studies of lesions of natural bovine and caprine dermatophilosis and the treatment trials were undertaken in 8 different animal farms on the island of St. Kitts, during the months of September and October, 1992. A total of 9 clinical cases, 7 cattle and 2 goats, was studied.

The pre-treatment lesion evaluation studies involved visual inspection of the lesion characteristics, such as the size, location and extent of scabiness, as well as the overall animal body condition. Previous history of dermatophilosis and the prevailing husbandry practices within the farms were also evaluated. Scabs were collected from representative lesions by means of sterile forceps and stored in sterile specimen vials placed immediately in ice-cooled vacuum flasks. The vacuum flasks were further refrigerated prior to being transported to our laboratory at the School of Veterinary Medicine, University of The West Indies, Trinidad, W.I.

Treatment trials were undertaken on cases by smearing the undiluted (2.5%) Lamstreptocide A & B with the aid of paint brushes on an affected side of one half of the body or on the extremities of one side of the affected animals.

The other affected side or the opposite affected extremities were smeared with distilled water by means of another paint brush and served as control. In occasional instances where the animal was quite vicious, the brush handle was tied to a stick to facilitate application of the substance from a safe distance (photo 1).

1. School of Veterinary Medicine, Faculty of Medical Sciences, The University of The West Indies, St. Augustine, Trinidad, Trinité et Tobago.



Photo 1 : Topical application of Lamstreptocide A & B by means of a brush tied to a stick.

Laboratory studies on pre- and post-treatment specimens

Histopathologic and direct smear preparations

Portions of the scabs were fixed in 10 % buffered-neutral formalin, dehydrated in graded ethanol solution, infiltrated and embedded in paraplast, and thick sections (approximately 6 μm thick) were obtained and stained by standard Hematoxylin and Eosin procedures, and by Wright's Stain. Portions of the scabs were similarly utilized for direct smear demonstration of *Dermatophilus congolensis* by teasing in drops of sterile distilled water, and staining of the smear by Wright's method.

Bacterial isolation

This was accomplished by processing portions of the scabs according to HAALSTRA's method (2), which involved placement of scabs in sterile distilled water for 3 1/2 hours at room temperature in bijou bottles, and subsequent transfer of the bottles with loosened lids into candle jars for 15 min. Loopfuls of zoospores were obtained from the surface of the water and inoculated into blood agar plates which were incubated in 10 % CO_2 atmosphere at 37 °C for 48 h.

In vitro sensitivity tests

Different volumes of the stock preparation of Lamstreptocide A & B were mixed with a fixed volume of sheep blood agar to yield final concentrations of 0.5, 1, 2,

5 and 10 % of the drug. Loopfuls of pure colonies of *D. congolensis* were streaked on untreated (control) and lamstreptocide-treated agar plates. All experiments were carried out in triplicates. The plates were incubated in 5 % CO_2 at 37°C and the growth of *D. congolensis* was monitored for 3 to 7 days.

Lamstreptocide agar impregnated disks were prepared as follows :

0.5, 1, 2, 5 and 10 % different concentrations, of Lamstreptocide A & B were prepared in 5 mm diameter filter paper disks (Whatman No.1), sterilized at 120 °C for 15 min, and were subsequently impregnated with the various concentrations as above. The impregnated disks were placed on the first set of plates while the second set had 5 mm diameter wells cut in them and then filled with the different concentrations. All the blood agar plates were incubated at 37 °C in 5-10% CO_2 for 48 h. The growth of *D. congolensis* around the zones in which Lamstreptocide A & B were applied was measured and recorded as areas of inhibition.

RESULTS

The findings on pre-treatment clinical evaluation studies of the lesions of cases are summarized in table I. The bovine cases had lesions which were either discrete, isolated scabs, located mostly on the dorsum of the trunk (photo 2), or severe scabby encrustations mostly affecting the manus and pes (photo 3). An exceptional bovine case was a calf (MO2) with generalized, severe, confluent and exudative lesions on almost all areas of the body surface (photo 4). This calf was in overall poor body condition with marked signs of emaciation and cachexia. It had a history of previous attacks of dermatophilosis which were treated with Terramycin LA, but with subsequent relapses. In general, apart from this severely affected calf and the case shown in photo 3, both of which had a history of previous infection of dermatophilosis, most other bovine cases were first time infected cases. The 2 capri-

TABLE I Summary of lesion characteristics of cases.

Lesion Type	No. of cases	Species
Mild, discrete, isolated scabs, mostly on dorsum of trunk, neck and face	5	Bovine
Severe confluent, exudative encrustations, mostly on manus and pes	1	Bovine
Very severe generalized exudative and scabby lesions ; overall emaciation and cachexia	1	Bovine
Discrete and confluent scabs on the face, pinnae, muzzle and neck	2	Caprine



Photo 2 : A pre-treatment case with discrete, isolated scabs on the dorsum of the trunk.



Photo 4 : A pre-treatment calf with severe, generalized confluent and exudative lesions. Note the overall poor body condition.

ne cases, MO1 and CN2, had scabby lesions on the face, pinnae and other areas of head and neck. The overall body condition of the typical caprine case was fair (photo 5).

Table II represents summaries of results obtained following treatment of cases with Lamstreptocide A & B. Pre-treatment demonstration of *D. congolensis* by histopathological and bacteriological isolation methods were positive in a total of 8 out of the 9 encountered cases. The follow-up post-treatment histopathologic and bacteriological evaluation studies undertaken at 3 weeks yielded positive results for the presence of *D. congolensis* in the lesions.

Apart from the slight changes which involved overall drying of scabs in most cases (at about 1 week post-treatment) (photo 6), and a significant peeling-off of scabs on the treated manus and pes of a case (Bk.1), exposing an




Photo 3 : A pre-treatment severely affected case, mostly involving the manus and pes.



Photo 5 : A pre-treatment caprine case showing lesions on the face, pinnae and other areas of the head and neck.

TABLE II Summary of 3 weeks. Post-treatment study.

Lesion appearance	Demonstration of <i>D. congolensis</i>		No. of cases
	Histopathology	Bacteriology	
Dried scabs on both treated and untreated body areas	+++	+++	3
Peeled-off scabs on the treated manus and pes with resultant underlying erythematous tissue	+++	+++	1
Dried-up scabs ; overall body improvement	++	+++	1
Cleared-up scabs and overall body improvement	Not done	Not done	1
Mildly improved overall body condition ; follow-up administration of Terramycin LA. ; animals subsequently slaughtered	Not done	Not done	2

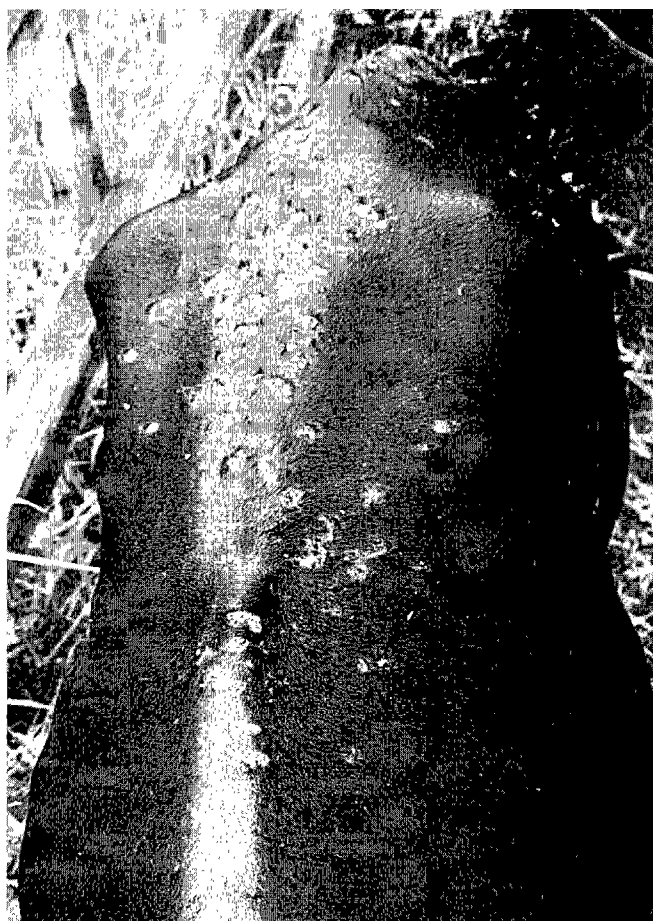

Photo 6 : The dried lesions of the animal shown in photo 2 , at 3 weeks post-treatment.

erythematous underlying tissue (photo 7), there was no remarkable change of lesions between the treated and untreated body areas.

Of the remaining 3 positive pre-treatment cases, there was an observed clearing-up of the initial mild lesions of a case (Bk.1 M) which was subsequently slaughtered prior to our follow-up post-treatment study. The other 2 cases were treated with Terramycin LA according to the wish of the owners and so were not available for post-treatment follow-up studies.

A reapplication of Lamstreptocide A & B to the previously treated body areas of 3 of the 5 positive post-treatment cases did not yield any remarkable change of lesions 2 weeks later. The result of the *in vitro* sensitivity test for the antibacterial activity of Lamstreptocide A & B is shown in table III. A slowing down of growth of *D. congolensis* was observed at concentrations of Lamstreptocide A & B



Photo 7 : The case shown in photo 3 at 3 weeks post-treatment. Note peeled-off lesions of the treated lower extremities which have underlying erythematous tissue.

TABLE III Summary of result obtained on *in vitro* antibacterial sensitivity test of Lamstreptocide A and B.

Method	Concentration %	Remarks
Agar-streak procedure	0.5, 1, 2, 5, 10	Slow growth of <i>D. congolensis</i> at concentration > 1% at 7 days post-inoculation
Agar-impregnated disk procedure	0.5, 1, 2, 5, 10	Growth of <i>D. congolensis</i> at 24 h post-inoculation

in excess of 1 % at 7 days post-inoculation, by the agar-streak method. There was no inhibition of growth of *D. congolensis* by Lamstreptocide A & B at any of the concentration tested, utilizing the agar-impregnated method.

DISCUSSION

As evident from this study, the efficacy of Lamstreptocide A & B on the few cases of dermatophilosis is questionable. Apart from the drying-up of scabs on most of the cases, and the peeling-off of the scabs revealing underlying erythematous tissue in a case, an outright recovery attributable to Lamstreptocide A & B was only demonstrated in 3 mild cases within the first category of lesions described in table I. Unfortunately, these mild cases were unavailable for post-treatment follow-up investigations.

One of the issues of concern pertains to the 5 cases in which the observable effect of Lamstreptocide A and B was mere drying-up and peeling-off of scabs. The major concern in this regard is the fact that the scabs of both treated and control sites were significantly positive for *D. congolensis* at 3 weeks post-treatment. Even after the reapplication of the substance to previously treated body areas of 3 of the 5 post-treatment cases, the scabs were still positive for *D. congolensis* at 2 weeks post-treatment.

Perhaps the most disturbing aspect is the *in vitro* sensitivity result in which there was no outright inhibitory activity on the growth of *D. congolensis* by Lamstreptocide A & B, employing two standard sensitivity methods. Only a slowing down of growth of *D. congolensis* at concentrations of the substance in excess of 1 % was noted, employing the agar-streak method. It may, however, be possible that the potency of the product may have been compromised as a result of transporting it over a long period and using it in a distant location (the Caribbean).

The producers had, however, indicated that "geographical variations did not seem to influence the efficacy of the product in infected cattle" (5). It is also possible that the recorded success with the product on tested cases in Nigeria, in which a cure rate of 93 % was reported (5),

pertained to mild cases rather than severe cases as with some of the cases of the present investigation. In view of the continued threat of dermatophilosis on ruminant production, and of the complex etiology of the condition in which *D. congolensis* and pox viruses may play roles in the causation of the disease (1, 3, 4, 6), it is suggested that more trial studies on the efficacy of the product be undertaken in other geographic locations.

ACKNOWLEDGEMENTS

We acknowledge The University of the West Indies for funding this research, and the Veterinary Research Laboratory, Ministry of Agriculture, Curepe, Trinidad for assistance with the laboratory processing of specimens. We are also grateful to the Chief Veterinary Officer and the Veterinary Department of the Ministry of Agriculture, St. Kitts, for cooperation in making the animals available for the project.

REFERENCES

1. ABU SAMRA (M.T.), WALTON (G.S.). The inoculation of rabbits with *Dermatophilus congolensis*. *J.Comp. Pathol.*, 1981, **86** : 1-172.
2. HAALSTRA (R.T.) Isolation of *Dermatophilus congolensis* from skin lesions in the diagnosis of streptothricosis. *Vet. Rec.*, 1965, **77** : 824-825.
3. ISITOR (G.N.), DELLMANN (H.D.), ADEGBOYE (D.S.), EZEOKOLI (C.D.), CHINEME (C.N.). Ultrastructural evidence for involvement of pox virions in lesions of bovine dermatophilosis. *Trop. Vet.*, 1984, **2** : 183-189.
4. ISITOR (G.N.), KAZEEM (H.M.), NJOKU (C.O.), ADEGBOYE (D.S.), DELLMANN (H.D.). Frequency of involvement of pox virions in lesions of bovine dermatophilosis. *Trop. Anim. Hlth. Prod.*, 1988, **20** : 210.
5. LAMORDE (A.G.), MAKINDE (A.A.), ADE AJAYI OKEKE (A.N.C.), ALI (U.D.), EZEH (A.O.), UZOUKWU (M.), ENURAH (I.U.), AHMED (M.S.), ABUBAKAR (A.A.), DURBI (I.A.A.), EMENIKE (A.O.), GARBA (A.), ALIYU (A.). Therapeutic trials on dermatophilosis in zebu cattle in Nigeria using natural products. *In* : 2nd International Symposium on dermatophilosis. National Veterinary Research Institute, Vom, Plateau State, Nigeria, November 4-9, 1991.
6. MUNZ (E.). Double infection of sheep and goats in Kenya with orf virus and *Dermatophilus*. *In* : LLOYD, SELLERS Eds. *Dermatophilus* infections in animals and man. London, Academic Press, 1976. P. 57-65.

G.N. Isitor C.O. Njoku A.O. Adogwa A.O. Oyekan

ISITOR (G.N.), NJOKU (C.O.), ADOGWA (A.O.), OYEKAN (A.O.).
Study of efficacy of Lamstreptocide A & B on cases of dermatophilosis within the Caribbean. *Revue Elev. Méd. vét. Pays trop.*, 1993, **46** (1-2) : 303-308

The efficacy of Lamstreptocide A & B was studied on 9 natural cases of bovine and caprine dermatophilosis in 8 different farms in St. Kitts, employing standard histopathologic and bacteriological methods. The lesions of 5 of the treated cases were dried-up, and there was marked peeling-off of scabs of a severely affected case exposing erythematous underlying tissue, at 3 weeks post-application of the product. Apart from 3 mild cases which were not available for follow-up studies and which were reported to have recovered, there was no outright recovery of the 5 animals after treatment at 3 weeks, and even after a second application of the product. An *in vitro* sensitivity test of the product revealed a slowing down of growth of *Dermatophilus congolensis* at concentrations in excess of 1 % by agar-streak method. However, there was no inhibition of growth of the bacterium by an agar-impregnated sensitivity method.

Key words : Cattle - Sheep - Dermatophilosis - *Dermatophilus congolensis* - Isolation - Lesion - Dermatology - Bactericide - Therapeutics - Caribbean - Saint Kitts.

ISITOR (G.N.), NJOKU (C.O.), ADOGWA (A.O.), OYEKAN (A.O.).
Eficiencia del Lamstreptocide A y B en casos de dermatofilia en el Caribe. *Revue Elev. Méd. vét. Pays trop.*, 1993, **46** (1-2) : 303-308

Se estudió la eficiencia del Lamstreptocide A y B en nueve casos naturales de dermatofilia bovina y caprina, en ocho establecimientos en San Kitts. Se utilizaron métodos histopatológicos y bacteriológicos estándar. Las lesiones de cinco rumiantes tratados fueron secadas. En un caso severo se observó la descamación, con exposición de tejido eritematoso tres semanas después de la aplicación del producto. Con excepción de tres casos leves, a los cuales no se les dió seguimiento, pero se reportó la cura, tres semanas después del tratamiento, no hubo recuperación en los cinco animales tratados, mismo después de una segunda aplicación del producto. Una prueba de sensibilidad *in vitro* del producto, mostró un crecimiento lento de *Dermatophilus congolensis* en concentraciones de 1% de exceso por el método de "agar-streak". Sin embargo no hubo inhibición de crecimiento bacteriano mediante el método de sensibilidad por agar impregnado.

Palabras claves : Bovino - Caprino - Dermatofilia - *Dermatophilus congolensis* - Aislamiento - Lesión - Dermatología - Bactericida - Terapéutica - Caribe - San Kitts.