

B. Poermadjaja<sup>1</sup>N. Ambrose<sup>1</sup>A. Walker<sup>1</sup>A. Morrow<sup>1</sup>

## Cellular responses in experimental chronic and acute dermatophilosis infections of sheep

POERMADJAJA (B.), AMBROSE (N.), WALKER (A.), MORROW (A.). Réponses cellulaires dans la dermatophilose expérimentale chronique et aiguë de moutons. *Revue Élev. Méd. vét. Pays trop.*, 1993, **46** (1-2) : 277-282

Lors de lésions de la dermatophilose, le derme est infiltré par un éventail de types de cellules. Le but de cette étude était de vérifier si la composition des infiltrations cellulaires dans les lésions chroniques était différente de celle dans les lésions en voie de guérison. Des infections expérimentales de moutons par *Dermatophilus congolensis* ont été utilisées pour étudier les changements en types cellulaires qui se succèdent au cours d'infections chroniques et aiguës. Des infestations par des *Amblyomma variegatum* adultes ont été utilisées pour produire des lésions chroniques chez des moutons infectés, tandis que des infections de moutons sans tiques donnaient des lésions aiguës. Les types de cellules dans le derme des sites d'infection ont été colorés et typés par des méthodes d'histopathologie et d'immunohistochimie. Les neutrophiles étaient dominants au cours de la réponse initiale et étaient présents en plus grand nombre dans les lésions chroniques. Des cellules plasmatisées étaient présentes dans les deux types de lésions, mais persistaient dans les lésions chroniques, tandis qu'elles disparaissaient de la peau dans les sites des lésions aiguës après la guérison des lésions. Déjà à partir de 4 jours après l'infection il y avait de 2 à 3 fois plus de cellules mononucléaires dans les lésions chroniques que dans les lésions aiguës, et ces cellules persistaient dans les lésions chroniques. La population des cellules mononucléaires dans les lésions chroniques consistait en lymphocytes T auxiliaires et en lymphocytes T suppresseurs cytotoxiques dans des proportions égales, tandis que dans les lésions aiguës en voie de résolution, 14 jours après infection, le nombre de cellules T auxiliaires dépassait celui des cellules T suppresseurs cytotoxiques.

*Mots clés* : Ovin - Dermatophilose - *Dermatophilus congolensis* - Lésion - Tique - *Amblyomma variegatum* - Immunologie - Cellule - Lymphocyte.

### INTRODUCTION

The cellular infiltrate in the dermis of ruminant skin infected with *Dermatophilus congolensis* contains a range of cell types. The dominant cells are neutrophils (2,9) and mononuclear cells (3). ODUYE (8) reviewed the histopathological studies on chronic and acute dermatophilosis, he concluded that neutrophils dominate the initial reaction and mononuclear cells dominate the reaction in the dermis of advanced chronic lesions. Neutrophils also occur in the scabs of chronic lesions. Experimental infection of ruminants with *D. congolensis* produces acute lesions which resolve without treatment in 2-4 weeks. To date

there has not yet been a parallel study of cell types in experimental acute and chronic infections under controlled conditions. This information is essential for future studies on all aspects of the immunology of dermatophilosis : at present the mechanisms involved in protective responses, lesion healing responses, and pathogenic responses are not understood. However it has been suggested that skin surface antibodies may be responsible for protection (3, 6, 11) and lesion resolution (3), that increased epidermal cell turnover caused by lymphokines from mononuclear cell infiltrates may contribute to lesion resolution (13) and that a persistent mononuclear cell response may contribute to pathogenesis (1).

Recently it has been shown that chronic dermatophilosis lesions can be produced by infesting animals with adult *A. variegatum* ticks prior to infecting them with *D. congolensis* at sites far separate from the ticks (12). This paper describes the cell types present in the skin of tick infested and tick-free sheep following experimental infection with *D. congolensis*. The aim was to find out if there were differences between the cell types present in the dermis during acute and chronic dermatophilosis infections.

### MATERIALS AND METHODS

Four sheep (Blackface x Suffolk ewes) were paired for weight, kept indoors at 20 °C, 75 to 95 % relative humidity and fed rations of hay and concentrates ample for health. The sheep had not been exposed to ticks before and were treated with anthelmintic (fenbendazole) before use. The autopsy material described here came from the second *A. variegatum* infestation and *D. congolensis* infection, 7 weeks after a first infestation and infection.

Adult *Amblyomma variegatum* were applied to one sheep of each pair (test sheep) at a separate site from the sites of infection with *D. congolensis*. The other sheep of each pair were without ticks (control sheep). Cotton bags to confine the ticks were glued to wool on the shoulders of test sheep. Ten male ticks were allowed to feed for at least one week then females were added to give 10 mating pairs. The timing of tick feeding was such that females had fed for approximately 5 days before *D. congolensis* was applied. Feeding proceeded until repletion or the end of that phase of the experiment at 5 weeks after the application of males.

1. Centre for Tropical Veterinary Medicine, Easter Bush, Roslin, Midlothian, EH25 9RG, Ecosse, Grande-Bretagne.

One flank of each sheep was sheared close to the skin but the skin was not scarified. The skin was washed with a solution of non-ionic detergent ('Tween 80'), left to dry, then degreased with a 1:1 mixture of ethanol and ether. Sites for infection with *D. congolensis* measuring 2 x 4 cm were outlined with a marker pen. The *D. congolensis* isolate was taken from a sheep in Scotland, it was cultured on Columbia agar containing 7 % calf serum. Cocci and zoospores were scraped from the agar and suspended in Hanks balanced salt solution containing 0.5 w/v pig gelatin as a thickening agent. The resulting suspension was used at a concentration of  $1.25 \times 10^8$  per cm<sup>2</sup>. 100  $\mu$ l of *D. congolensis* suspension was applied to sites on the sheep such that at autopsy, at the end of the experiment, they had sites of ages 4, 9, 14, 18, 23 and 28 days post-infection (dp.i.). In addition an uninfected site was taken as a day 0 control and the site of infection with the highest dose from the first infection was taken to represent a 56 day old site.

At autopsy samples of the infection site from control and test sheep were taken for histology and immunohistochemistry. Samples for histology were fixed and processed for light microscopy examination using methacrylate plastic embedding. Four 2  $\mu$ m thick sections from each sample were stained with Giemsa's stain, and four sections stained with pyronin and methyl green to examine plasma cells. The number of mononuclear cells, neutrophils and plasma cells were counted in 5 similar fields of view at x 1000 magnification. Fields in the upper dermis were selected to avoid major skin organelles. Median values of the cell counts were determined.

Samples of infection sites for immunohistochemistry were taken from test and control sheep at 0, 14 and 28 days post-infection, they were frozen immediately after being taken. Sections were cut at 8  $\mu$ m, mounted onto coated multiwell slides and dried for 2-3 hours at 37 °C. A panel of monoclonal antibodies (MAbs) against ovine lymphocyte subsets was purchased from the Centre for Animal Biotechnology, University of Melbourne, Australia, their specificities and phenotypes are given in table I. The optimal working dilutions of the MAbs were determined by titration using the method described below. Dilutions of 1/10, 000 were selected except for CD1 which was used at 1/32,000. The MAbs were used to label lymphocytes in

TABLE I List of monoclonal antibodies.

Monoclonal antibody	Antigen specificity	Cell phenotype
SBU 20.27	CD1	Antigen presenting cells
SBU 44.38	CD4	T-helper cells
SBU 38.65	CD8	T-cytotoxic/ suppressor cells
SBU 25.91	CD5	Pan T-cell marker
SBU 19.19	T-19	Gamma-delta T-cells
SBU 20.96	CD45R	B-cells

sections using a standard indirect immunoperoxidase technique. Briefly, the sections were fixed in acetone, endogenous peroxidase activity was blocked with hydrogen peroxide and the slides were incubated with 200  $\mu$ l of an anti-ovine lymphocyte monoclonal antibody overnight at 18 °C under humidified conditions. After washing, the slides were each incubated with 200  $\mu$ l of goat anti-mouse IgG peroxidase conjugate (Nordic) diluted 1/100, for 1 h at 18 °C in a humidified chamber. After washing, positive labelling was visualised using a solution of the substrate 3,3'-diaminobenzidine tetra-hydrochloride containing hydrogen peroxide. The reaction was then enhanced with osmium tetroxide. The sections were counterstained with Giemsa's stain, dehydrated and mounted in DPX. Cell counts were made as described for the histological sections except that a magnification of X 400 was used.

## RESULTS

The *D. congolensis* infection procedure produced characteristic dermatophilosis lesions on all sheep. In the control sheep *D. congolensis* was present in lesions only up to 14 dp.i. and the lesions had resolved by 23-28 dp.i. However in tick-infested test sheep scabs were present until the end of the experiment at 56 dp.i. Histopathology showed the presence of *D. congolensis*, haemorrhagia and exudation up to 56 dp.i. In both test and control sheep eosinophils and mast cells were found only in small numbers in the dermis below infection sites.

The number of neutrophils increased in both test and control sheep after infection. In control sheep their numbers peaked at 4 dp.i. and declined to preinfection levels by 14-18 dp.i. However in the test sheep they peaked at higher levels than in controls on day 9 and declined to pre-infection levels by 18-23 dp.i. (fig. 1).

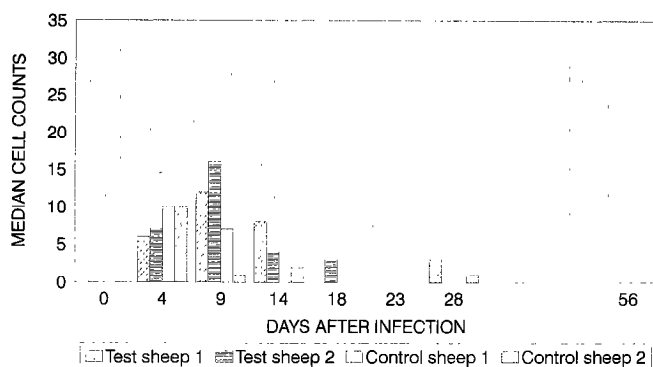


Figure 1 : Neutrophils in lesions on test and control sheep.

The number of plasma cells at infection sites increased in both test and control sheep after infection. In controls they peaked at 14 dp.i. then declined to pre-infection levels by 56 dp.i. In test sheep, the number of plasma cells peaked at 18-23 dp.i. and remained at a level above the number in pre-infection and control sheep skin until 56 dp.i. (fig. 2).

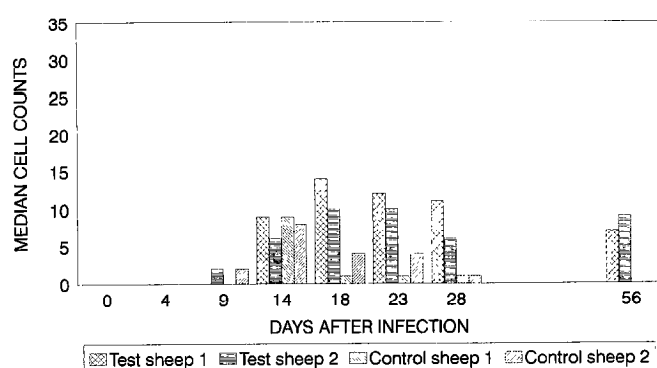


Figure 2 : Plasma cells in lesions on test and control sheep.

Mononuclear cells increased in the dermis of infection sites on control and test sheep. From 8-56 dp.i. mononuclear cells were more abundant in test than control sheep. Their numbers peaked at 14 dp.i. in all sheep, however at this time there were approximately 3 times as many in test sheep than control sheep. In the test animals mononuclear cells continued to be present at elevated levels until 56 dp.i. whereas in controls they declined between 14 and 56 dp.i. (fig. 3).

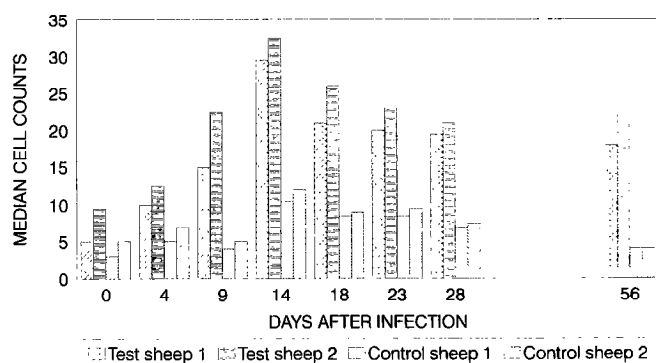


Figure 3 : Mononuclear cells in lesions on test and control sheep.

In the light of the above observations samples of skin were selected for study by immunohistochemistry. The aim was to provide more information on the differences

in the composition of lymphocyte populations in the mononuclear cell infiltrate of acute and chronic lesions on control and test sheep respectively. Day 0 post-infection was selected as a pre-infection control, day 14 post-infection was selected as the time when mononuclear cell numbers were at their maximum levels and acute lesions in control sheep were beginning to heal. Day 28 post-infection was selected as the time when control skin had returned to normal, as judged by histopathological observations, whereas on test sheep lesions were persisting.

The number of CD5 positive cells increased in both test and control sheep between 0 and 14 dp.i. and then remained at elevated levels until 28 dp.i. (fig. 4). The number of CD5 cells was equal to 73 % or greater of the combined total of CD4 and CD8 in all sheep, at all times except in test sheep at 14 dp.i. In these lesions at this time CD5 positive cells accounted for only 45 % and 48 % of the CD4 plus CD8 total.

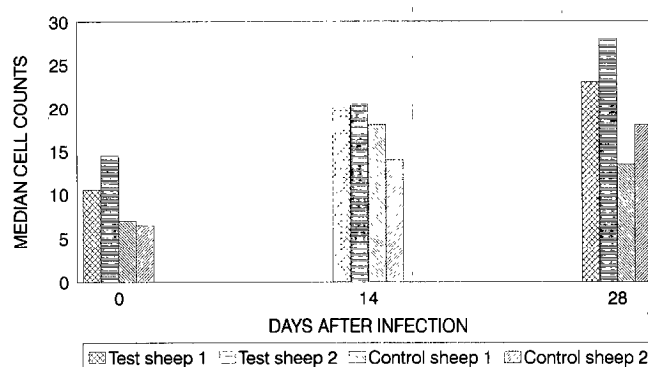


Figure 4 : CD5 positive cells in lesions on test and control sheep.

The number of CD1 positive cells (antigen presenting cells) increased in both test and control sheep between 0 and 14 dp.i., then, to 28 dp.i. they continued to increase in control sheep whereas they decreased in test sheep (fig. 5).

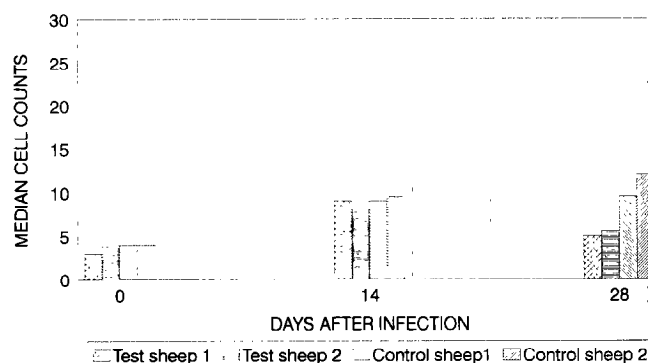


Figure 5 : CD1 positive cells in lesions in test and control sheep.

CD4 positive cells (T-helper cells) increased in number in test and control sheep between 0 and 14 dp.i., however they were more abundant in test than control sheep at 14 dp.i. (fig. 6).

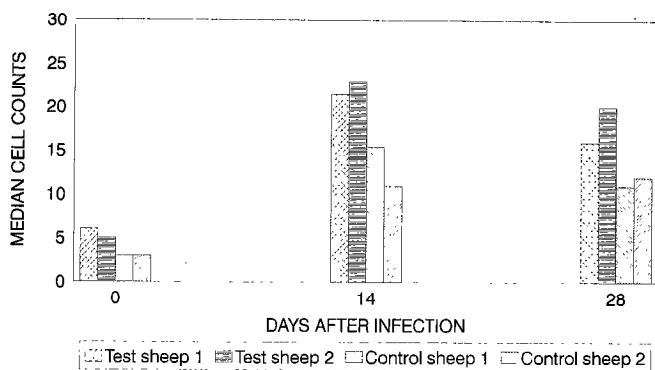


Figure 6 : CD4 positive cells in lesions on test and control sheep.

CD8 positive cells (T-cytotoxic/suppressor cells) were more abundant in the skin of test sheep at day 0. Their numbers increase from 0 to 14 dp.i. in both test and control sheep, however they were substantially more abundant in test than control sheep at 14 dp.i. (fig. 7).

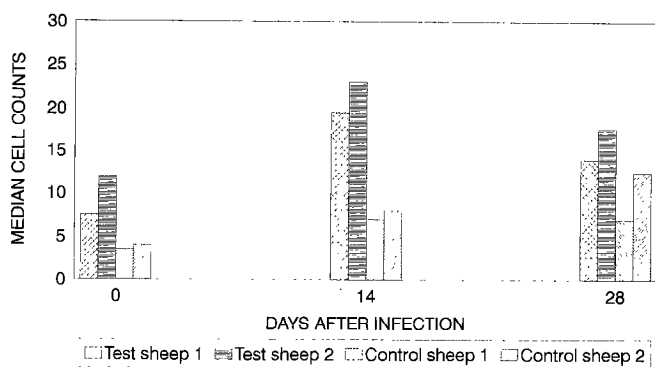


Figure 7 : CD8 positive cells in lesions on test and control sheep.

The ratio of CD4 : CD8 positive cells was 1 or less on all but three occasions ; it was substantially above 1 at 14 and 28 dp.i. in one control sheep and at 14 dp.i. in the other control sheep, these ratios were 2.2, 1.6 and 1.4 respectively.

The numbers of T-19 positive cells (gamma-delta T-cells) in both test and control sheep were small, they were slightly increased between 0 and 28 dp.i. (fig. 8).

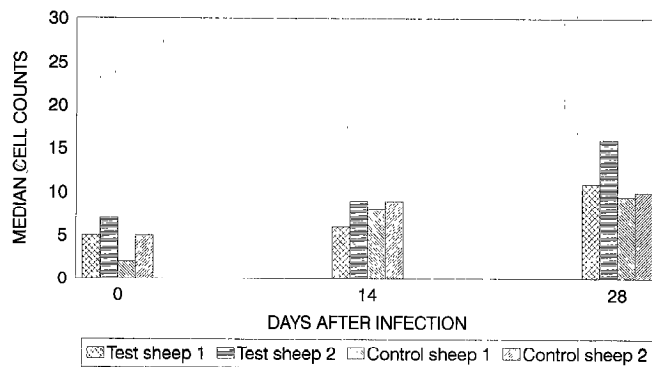


Figure 8 : T-19 positive cells in lesions on test and control sheep.

CD45R positive cells (B-cells) showed a similar pattern in test and control sheep : the numbers were small in both, from 0-14 dp.i. they increased and from 14-28 dp.i. they decreased (fig. 9).

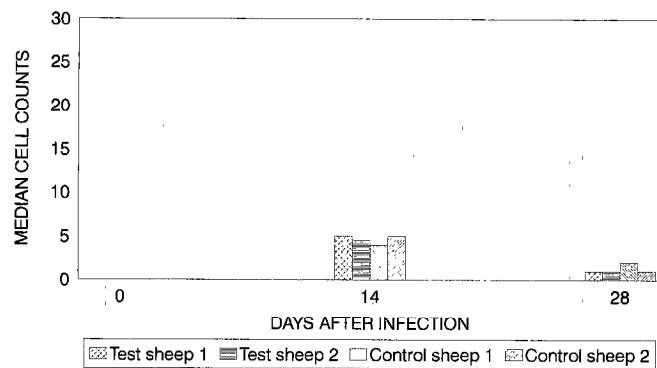


Figure 9 : CD45R positive cells in lesions on test and control sheep.

## DISCUSSION

Our observations on the presence of neutrophils and mononuclear cells in the dermis following infection with *D. congolensis* are in agreement with those of other workers. Neutrophils dominate the initial reaction, this is followed by an influx of mononuclear cells into the dermis. However in the lesions which become chronic on tick-infested test sheep the peak in numbers of neutrophils was later and greater than in control sheep. ELLIS *et al.* (4) found that neutrophils from sheep with chronic dermatophilosis phagocytosed opsonized *D. congolensis* more efficiently than neutrophils from sheep that had recovered from dermatophilosis. In our study the large number of neutrophils in chronic lesions were unable to control the infection. In a transmission electron microscope study of



these lesions POERMADJAJA (unpublished observation) found that *D. congolensis* hyphae were too big to be phagocytosed by neutrophils. This result appears to contradict the suggestion of ROBERTS (10) that neutrophils contribute to lesion resolution.

Our observations on the occurrence of plasma cells are interesting in that these cells occur in larger numbers and persist for longer in chronic than acute lesions. This begs the questions : Are they producing antibodies that contribute to healing but which are ineffective for some unknown reason and, do plasma cells in chronic and acute lesions produce antibodies with different specificities ? It has been shown that following inoculation of sheep and vaccination of cattle with *D. congolensis*, skin surface antibodies are produced that are specifically directed against *D. congolensis* antigens and it was suggested that they may contribute to clearing infections (7,11). However the efficacy of these antibodies in mediating killing of *D. congolensis* and the antigen specificity of skin surface antibodies on chronically infected animals has not been investigated.

Mononuclear cells were at least twice as numerous in chronic lesions compared to acute lesions from 14-56 dp.i.. This response indicates an exaggerated reaction to *D. congolensis* as a result of the *A. variegatum* infestation and in common with the heightened neutrophil response and persistent plasma cell response, these mononuclear cells do not contribute to lesion resolution. The results from immunohistochemical studies showed that the increased number of mononuclear cells in test sheep lesions were mainly composed of CD4 and CD8 positive cells in equal proportions. It is interesting to note that in their immunohistochemical studies of experimental infections of sheep with chronic dermatophilosis and spontaneously recovered sheep, ELLIS *et al.* (4) found CD4 : CD8 ratios of one or less except in the recovered sheep at 15 dp.i.. In our study the only noticeable deviation of CD4 : CD8 above one was in acute lesions at 14 and 28 dp.i.. It seems likely that an excess of T-helper cells is required for lesions to resolve, however the immune mechanism involved in lesion resolution remains unknown.

WOODMAN *et al.* (14) showed that acute infections in rats stimulated a *D. congolensis* specific T-helper cell response and WOODMAN (13) demonstrated that culture supernatants, possibly containing lymphokines, from *D. congolensis* stimulated lymphocytes altered the kinetics of epidermal cell growth. She suggested that increased epidermal cell turnover may lead to lesion resolution. If this is correct, lymphokine production in chronic and acute lesions may be qualitatively different, as the scabs of chronic lesions are characterised by massive accumulations of keratinocytes. An alternative hypothesis is that gamma-interferon is released by T-helper cells and is bacteriocidal or bacteriostatic, thus preventing the proliferation of *D. congolensis*.

ELLIS *et al.* (4, 5) showed that numbers of CD1 positive cells in sheep were low in chronic lesions and in peripheral blood of chronically infected sheep when compared to acute lesions and blood from previously unexposed sheep. In our study there was a small difference between the number of CD1 positive cells in acute and chronic lesions at 28 dp.i., in retrospect it would have been interesting to examine the lymphocyte subsets in chronic lesions at 56 dp.i.. In a separate study AMBROSE (unpublished observation) found that chronic lesions on naturally infected cattle did not contain any CD1 positive cells although normal skin from these animals did so. Perhaps a defect in the presentation of antigens is a factor that contributes to the development of chronic dermatophilosis.

## CONCLUSION

- *Amblyomma variegatum* infested and tick free sheep were used to study the cellular responses in chronic and acute dermatophilosis infections respectively.
- In this study neutrophils dominated the early reactions to *D. congolensis*. Larger numbers occurred in chronic than acute lesions.
- Mononuclear cells were more abundant in chronic than acute lesions from an early stage after infection.
- Mononuclear cells and plasma cells persisted in chronic lesions.
- Mononuclear cell responses in chronic lesions were composed of T-helper and T-cytotoxic/suppressor lymphocytes in equal proportions.
- In acute lesions at 14 days after infection, when lesions begin to resolve, T-helper were more abundant than T-cytotoxic/suppressor lymphocytes.

## ACKNOWLEDGEMENTS

This work was funded by the Overseas Development Administration, U.K.. The authors are indebted to R. BOID and T. JONES for their help in preparing this paper.

## REFERENCES

1. ABU-SAMRA (M.T.). A study of the ultrastructure and the life cycle of *Dermatophilus congolensis*. *Zentbl. VetMed. B*, 1979, **26** : 110-124.
2. CHODNIK (K.S.). Mycotic dermatitis of cattle in British West Africa. *J. Comp. Path. Ther.*, 1956, **6** : 179-186.

B. Poermadjaja N. Ambrose A. Walker A. Morrow

3. ELLIS (T.M.), ROBERTSON (G.M.), SUTHERLAND (S.S.), GREGORY (A.R.). Cellular responses in the skin of Merino sheep to repeated inoculation with *Dermatophilus congolensis*. *Vet. Microb.*, 1987, **15** : 161-162.
4. ELLIS (T.M.), SUTHERLAND (G.M.), GREGORY (A.R.). Inflammatory cell and immune function in Merino sheep with chronic dermatophilosis. *Vet. Microb.*, 1989, **21** : 79-93.
5. ELLIS (T.M.), SUTHERLAND (S.S.), TURNOR (R.), KREUGER (R.). Relationship between chronic ovine dermatophilosis and levels of T6 lymphocyte antigen staining in peripheral blood mononuclear cells. *Vet. Microb.*, 1992, **30** : 281-287.
6. LLOYD (D.H.). Immunology of dermatophilosis : recent developments and prospects for control. *Prev. Vet. Med.*, 1984, **2** : 93-102.
7. LLOYD (D.H.), JENKINSON (D.M.). Serum and skin surface antibody responses to intradermal vaccination of cattle with *Dermatophilus congolensis*. *Br. Vet. J.*, 1981, **137** : 601-607.
8. ODUYE (O.O.). Histopathological changes in natural and experimental *Dermatophilus congolensis* infection of the bovine skin. In : *Dermatophilosis infection in animals and man*. London, Academic Press, 1976.
9. ROBERTS (D.S.). The histopathology of epidermal infection with the Actinomycete *Dermatophilus congolensis*. *J. Path. Bacteriol.*, 1965, **90** : 213-216.
10. ROBERTS (D.S.). The phagocytic basis of acquired resistance to infection with *Dermatophilus congolensis*. *Br. J. Exp. Pathol.*, 1966, **47** : 372-382.
11. SUTHERLAND (S.S.), ELLIS (T.M.), ROBERTSON (G.M.), GREGORY (A.R.). Serum and skin surface antibody responses in Merino sheep given three successive inoculations with *Dermatophilus congolensis*. *Vet. Microb.*, 1987, **15** : 209-218.
12. WALKER (A.R.), LLOYD (C.M.). Experiments on the relationship between feeding of the tick *Amblyomma variegatum* (Acari : Ixodidae) and dermatophilosis skin disease in sheep. *J. Med. Ent.*, 1993 (in press).
13. WOODMAN (J.P.). Mononuclear cell response of the rat to experimental infection with *Dermatophilus congolensis* and its effect on epidermal cell kinetics. In : *Advances in Veterinary Dermatology*, Volume 1. London, Baillière Tindall, 1990.
14. WOODMAN (J.P.), MORROW (A.N.), HERON (I.D.). Cellular immune responses of the rat to experimental infection with *Dermatophilus congolensis*. *Vet. Microb.*, 1990, **22** : 283-295.

**POERMADJAJA (B.), AMBROSE (N.), WALKER (A.), MORROW (A.)**. Cellular responses in experimental chronic and acute dermatophilosis infections of sheep. *Revue Élev. Méd. vét. Pays trop.*, 1993, **46** (1-2) : 277-282

The cellular infiltrate into the dermis in dermatophilosis lesions is composed of a range of cell types. The aim of this study was to establish if the composition of the cellular infiltrate in chronic lesions was different from that in healing lesions. Experimental *Dermatophilus congolensis* infections of sheep were used to study the sequential changes in cell types during the course of chronic and acute infections. Infestations of adult *Amblyomma variegatum* ticks were used to produce chronic lesions on infected sheep, infections of tick-free sheep provided acute lesions. Histopathology and immunohistochemistry were used to stain and label cell types in the dermis of infection sites. Neutrophils dominated the early response and were present in larger numbers in chronic lesions. Plasma cells were present in both types of lesion, however they persisted in chronic lesions but disappeared from the skin at acute lesion sites after the lesions had resolved. There were 2-3 times as many mononuclear cells in chronic than acute lesions from as early as 4 days post infection and these cells persisted in the chronic lesions. In the chronic lesions the mononuclear cell population was composed of T-helper and T-cytotoxic/suppressor lymphocytes in equal proportions whereas in acute lesions at 14 days post infection, when lesion resolution is underway, there were greater numbers of T-helper cells than T-cytotoxic/suppressor cells.

**Key words** : Sheep - Dermatophilosis - *Dermatophilus congolensis* - Lesion - Tick - *Amblyomma variegatum* - Immunology - Cell - Lymphocyte.

**POERMADJAJA (B.), AMBROSE (N.), WALKER (A.), MORROW (A.)**. Respuesta celular de la dermatofilia experimental crónica y aguda en ovejas. *Revue Élev. Méd. vét. Pays trop.*, 1993, **46** (1-2) : 277-282

El infiltrado celular en la dermis en las lesiones de dermatofilia se compone de una gama variada de tipos celulares. El objetivo de este estudio es el de determinar si la composición del infiltrado celular en las lesiones crónicas es diferente al de las lesiones en proceso de recuperación. Se produjeron infecciones experimentales con *Dermatophilus congolensis* en ovejas, para estudiar los cambios progresivos en los tipos celulares durante el curso de infecciones tanto crónicas como agudas. Se utilizaron infestaciones con especímenes adultos de *A. variegatum* para producir las lesiones crónicas en ovejas; las infecciones de ovejas libres de garrapatas produjeron las lesiones agudas. Se utilizaron técnicas de histopatología e inmunohistoquímica para la tinción y la determinación de los tipos celulares en la dermis de las zonas infectadas. La respuesta temprana presentó una mayoría de neutrófilos, los cuales fueron mas numerosos en las lesiones crónicas. Las células plasmáticas se encontraron en ambos tipos de lesión, cabe notar que se mantuvieron en las lesiones crónicas, pero desaparecieron de la piel en las lesiones agudas después de la cura. El número de mononucleares fue 2 a 3 veces mayor en las lesiones crónicas que en las agudas y esto a partir de 4 días post-infección, observándose también la persistencia en las lesiones crónicas. En éstas, la población de células mononucleares se compuso de linfocitos T de ayuda y T citotóxicos/supresores, en proporciones idénticas; mientras que en las lesiones agudas, 14 días post-infección, durante la resolución de la lesión, se observó un número mayor de células T de ayuda que T citotóxicas/supresoras.

**Palabras claves** : Ovino - Dermatofilia - *Dermatophilus congolensis* - Lesión - Garrapata - *Amblyomma variegatum* - Inmunología - Célula - Linfocito.