

Communication

appropriate method of therapy of SCC in veterinary medicine. Other methods of treatment applicable to human medicine (chemotherapy, immunotherapy, radiotherapy and endocrine gland ablation...) could be attempted in valuable animals or for research purposes.

Solar radiation has been incriminated in the causation of SCC in areas devoid of or sparsely covered by wool and in non pigmented skin. However, other factors may be involved especially with regard to tumours occurring in well protected areas (body sites) or in sites like the rectum (1, 2).

In Saudi Arabia grazing sheep might be highly exposed to solar radiation in areas of little natural shelter or shade especially during the hot dry summer month (June-August). In most of the country, summer temperature may exceed 45 °C and is associated with long sunshine hours (10-13 h) and high solar radiation (500-600 langleys per day) (19). Moreover, reflection of sunlight may be considerable. This could be of significance in the development of SCC in sheep in Saudi Arabia.

RAMADAN (R.O.), GAMEEL (A.A.), EI HASSAN (A.M.). Squamous cell carcinoma in sheep in Saudi Arabia. *Revue Élev. Méd. vét. Pays trop.*, 1991, **44** (1) : 23-26

Squamous cell carcinoma was recorded in 22 Nadji and 3 Maeimi sheep aged 3-6 years, of which 22 were females. Sixteen tumours involved the eyes, 7 occurred in the skin at different body sites, one developed in the ear and another in the rectum. In five cases secondary deposits were seen in the lymph nodes, nasal passages and upper lip. Surgical treatment was successful in the early stages of tumour development, but in advanced cases recurrences were noted. Histologically the tumours were typical for squamous cell carcinoma and most of them were well differentiated. Solar radiation was pointed out as a possible factor in the aetiology of the tumour. *Key words* : Sheep - Squamous cell carcinoma - Surgical treatment - Saudi Arabia.

References

- COTCHIN (E.). Veterinary oncology : a survey. *J. Path.*, 1984, **142** : 101-127.
- DANIELS (P.W.), JOHNSON (R.H.). Ovine squamous cell carcinoma (Review article). *Vet. Bull.*, 1987, **57** : 153-167.
- DAVIS (C.L.), SHORTEN (H.L.). Carcinoma of the eye of sheep. *J. Am. vet. med. Ass.*, 1952, **121** : 20-24.
- FASSI-FEHRI (N.), FASSI-FEHRI (M.). Quelques observations sur les carcinomes vulvaires et palpébraux de la brebis. *Maroc méd.*, 1972, **52** : 700-710.
- HAWKINS (C.D.), SWAN (R.A.), CHAPMAN (H.M.). The epidemiology of squamous cell carcinoma of the perineal region of sheep. *Aust. vet. J.*, 1981, **57** : 455-457.
- JONES (T.C.), HUNT (R.D.). *Veterinary pathology*. 5th ed. Philadelphia, Lea and Febiger, 1983. P. 1109-1111.
- LADDS (P.W.), ENTWISTLE (K.W.). Observation on squamous cell carcinoma of sheep in Queensland, Australia. *Br. J. Cancer*, 1977, **35** : 110-114.
- LAGARDIC (M.), WYERS (M.), MIALOT (J.P.), PARODI (R.L.). Observation d'une enzootie de cancers de la vulve chez la brebis. *Zentbl. VetMed.*, 1982, **29** : 123-135.
- LLOYD (L.C.). Epithelial tumours of the skin of sheep (tumours of areas exposed to solar radiation). *Br. J. Cancer*, 1961, **15** : 780-789.
- LOMBARD (C.), MAGNOL (J.P.). Premier cas d'épithélioma auriculaire chez le mouton en France. *Bull. Acad. vét. Fr.*, 1972, **45** : 349-362.
- MISK (N.A.), NIGAM (J.M.), RIFAT (J.F.). Surgical management of squamous cell carcinoma and papillomatosis in cattle and sheep. *Vet. Med. Rev.*, 1984, **2** : 144-153.
- RAMADAN (R.O.). Squamous cell carcinoma of the perineum of the goat. *Br. vet. J.*, 1975, **113** : 347-350.
- RIET-CORREA (F.), CASSAL (A.B.), SCARSI (R.M.), SCHILD (A.L.), MENDES (M.C.). Carcinomas epidermoides em ovinos em uma estabel ; ecimeto de Rio Grande do Sul. *Pesq. vet. brasil.*, 1981, **1** : 65-68.
- SWAN (B.A.), CHAPMAN (H.M.), HAWKINS (C.D.), HOWELL (J.M.C.), SPALDING (V.T.). The epidemiology of squamous cell carcinoma of the perineal region of sheep : abattoir and flock studies. *Aust. vet. J.*, 1984, **61** : 146-151.
- SWAN (B.A.), WYBURN (R.A.), CHAPMAN (H.M.). Tail lesions in merino lambs. *Aust. vet. J.*, 1980, **56** : 439-441.
- THEILEN (G.H.), MADEWELL (B.R.). *Veterinary cancer medicine*. Philadelphia, Lea and Febiger, 1987. P. 233-266.
- VANDERGRAAFF (R.). Squamous cell carcinoma of the vulva in merino sheep. *Aust. vet. J.*, 1976, **52** : 21-23.
- VANSELOW (B.A.), SPRADBROW (P.B.). Papillomaviruses, papillomas and squamous cell carcinoma in sheep. *Vet. Rec.*, 1982, **110** : 561-562.
- Water Atlas of Saudi Arabia. Ryad, Ministry of Agriculture and Water, 1984.

Pathogenesis of *Aspergillus fumigatus* infection in pigeons in the Sudan

A.K. Elmubarak ¹

A. Fadlelmula ²

ELMUBARAK (A.K.), FADLELMULA (A.). Pathogénèse de l'infection à *Aspergillus fumigatus* sur une race locale de pigeon au Soudan. *Revue Élev. Méd. vét. Pays trop.*, 1991, **44** (1) : 26-28

Les auteurs étudient la pathogénèse d'un isolat d'*Aspergillus fumigatus* sur une race locale de pigeon au Soudan. L'injection intraveineuse de spores a entraîné une affection aiguë avec 100 p. 100 de mortalité dans les six jours suivants. A l'autopsie, des lésions miliaires en pointe d'épingle prédominaient dans le foie, la rate, les poumons et les reins. L'examen histopathologique a révélé des lésions dans le foie, le coeur, les poumons, les reins, la rate et le cerveau. Des hyphes et/ou des spores ont été trouvés dans tous ces organes. La présence d'*Aspergillus fumigatus* a été confirmée par réisolement à partir des lésions du foie, des poumons et des reins. *Mots clés* : Pigeon - *Aspergillus fumigatus* - Infection expérimentale - Pathogénèse - Soudan.

Introduction

A. fumigatus is the commonest cause of avian aspergillosis. The disease is acute in young birds and runs a chronic course in mature ones (1) In pigeons, the natural disease was described as mycotic pneumonia (4), but mycotic granulomas were also encountered (5). It has been shown (1, 3) that this species could be experimentally infected with *A. fumigatus*.

A strain isolated from a natural severe pneumomycosis in pigeons was used to study the pathogenesis of an acute *A. fumigatus* infection.

1. Veterinary Research Laboratories, POB 8067, Alamarat, Khartoum, Sudan.

2. 19 Carton House, Dickens Estate, Marine Street, London SE16 4TA, United Kingdom.

Reçu le 26.7.1990, accepté le 23.10.1990

* May & Baker. ** Pfizer.

Materials and Methods

A total of 30 healthy 3-4 week pigeon squabs were divided into two groups of 15 each and kept in separate wire pens for observation during four weeks for signs of any infection. Each bird was inoculated orally with 0.5 ml of a metronidazole suspension (Flagyl 400)* at 12.5 mg/ml, and then injected with 0.05 ml of Terramycin** for three days.

The strain of *A. fumigatus* was originally isolated from a natural outbreak. Colonies were subcultured on malt extract agar slants (Oxoid) containing chloramphenicol (0.5 mg/ml) (Sigma) and incubated at 26-30 °C for ten days. A spore suspension was prepared in sterile phosphate buffered saline (PBS) and the spore number adjusted to 2×10^9 /ml by a counting chamber. Each pigeon in group I was injected *i.v.* with 0.5 ml of the suspension. Group II was left as control. Standard ante- and post-mortem examinations were performed. Samples for reisolation of *A. fumigatus* were removed from liver, kidneys and lungs. Tissues were fixed in 10 % formalin, processed, embedded in paraffin wax, cut at 6 μ thickness and stained with haematoxylin & eosin and PAS (Periodic Acid Schiff).

Results

Mortality

Out of the 15 inoculated pigeons, seven died within 3-4 days and the rest within 5-6 days post-inoculation. No death among the controls was noted. Most of the infected pigeons were found dead without prior noticeable signs, while only a few were severely depressed some hours before death.

Necropsy

Dead birds were in good condition, but musculature was darkened. Internally there was congestion of visceral organs. Livers were swollen, dark and had rounded edges with tiny focal haemorrhages and pinpoint yellowish-white foci. The spleens were swollen, dark with focal haemorrhages. Lungs and kidneys had pin-head size miliary yellowish-white foci. The pericardial sacs were distended with yellowish fluid. None of these changes were seen in the controls. *A. fumigatus* was reisolated from the liver, lung and kidney of infected pigeons, but not from others.

Histopathology

Lesions were detected only in the liver, spleen, lungs, kidneys, brain and heart. In the liver, an acute purulent hepatitis which would be followed by a necrotizing and/or granulomatous reaction was detected. The lesions started as numerous, tiny and discrete inflammatory foci (photo 1). They consisted of an accumulation of mononuclear and granulocytic cells with scattered fungal hyphae and spores, as confirmed by the PAS stain. Septate hyphae invaded the liver parenchyma and penetrated the blood vessel walls (photo 2). The inflammatory foci later developed into tiny abscesses with central necrotic areas containing cellular debris and fungal elements. Focal dilatation and congestion of sinusoids and blood vessels

were seen. Older lesions were larger with homogeneous eosinophilic material surrounded by multinucleated giant cells and inflammatory cells to form a granulomatous reaction. Bile ducts were proliferated with accumulation of lymphoid cells.

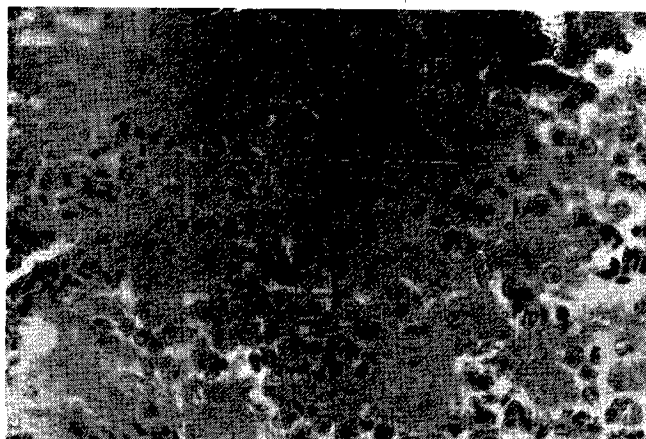


Photo 1 : Foci of mononuclear and granulocytic cells in the liver of a pigeon inoculated with *A. fumigatus* (x 400).

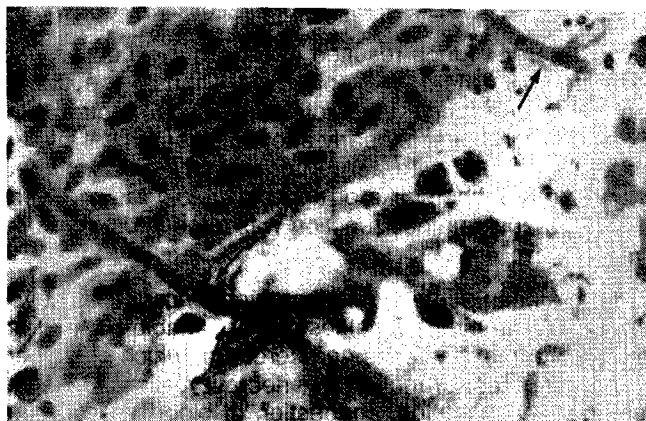


Photo 2 : Two *A. fumigatus* hyphae (arrows) penetrating a blood vessel wall into the liver parenchyma of a pigeon (x 400).

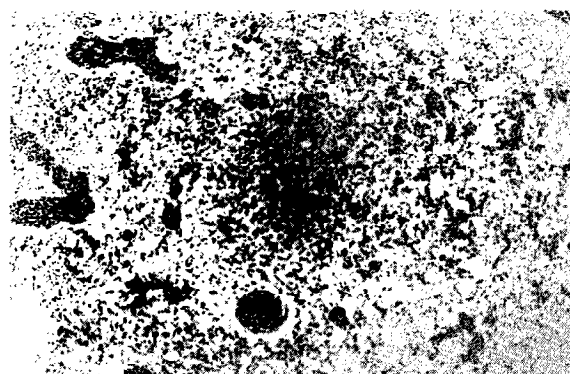


Photo 3 : A focus of inflammatory cells and necrosis in the lung of a pigeon inoculated with *A. fumigatus* spores (x 100).

Communication

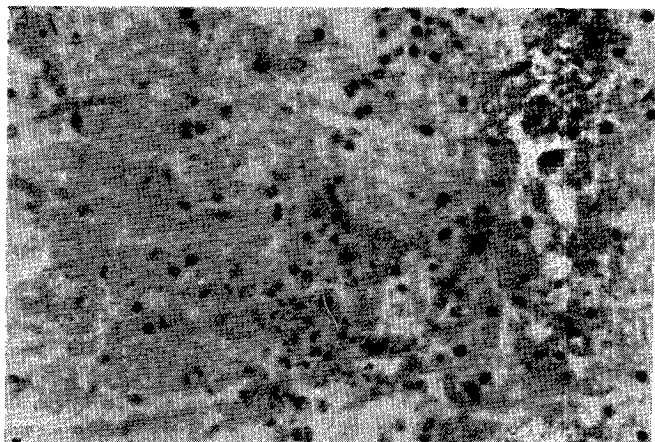


Photo 4 : Foci of inflammatory cells in the cerebrum of a pigeon inoculated with *A. fumigatus* spores (x 400).

An acute splenitis with degeneration and necrosis of parenchymatous cells was seen. Associated with sheathed vessels, foci of granulocytes were mingled with hyphae and surrounded by epithelioid cells and sometimes cellular debris. A few multinucleated giant cells were detected. Depletion of lymphoid cells was observed.

Invasion of the lungs resulted in an acute exudative and focal necrotic pneumonia (photo 3). Diffuse pneumonic foci containing fungal elements mixed with serofibrinous exudates were detected early after infection. Focal inflammatory reactions with aggregates of mycelia arranged radially in a sunburst-like or actinomycetoid fashion were seen. A granulomatous reaction was observed as lesions grew larger.

In the brain, an acute purulent meningoencephalitis developed in some birds. Focal lesions of variable sizes were detected in the meninges and cerebrum which contained hyphae, spores, granulocytes, necrotic cells and debris (photo 4). Vacuolation, congestion of blood vessels and degeneration of Purkinje cells were encountered in the cerebellum.

A few typical granulomatous lesions surrounded by fibroblasts were observed among kidney lesions. Smaller unencapsulated lesions containing giant cells around a homogeneous eosinophilic material were seen. Tubular lumina with exudate and tubular cells were either degenerated or necrotic.

Tiny inflammatory foci in the heart containing granulocytes, epithelioid cells, atypical giant cells and debris with fungal elements were detected.

Discussion and conclusion

This study indicates that pigeons are very susceptible to artificial infection with *A. fumigatus*, confirming earlier work (3, 5). Fungal spores were even able to cross the blood-brain barrier to induce meningoencephalitis. The hundred per cent mortality within six days following the intravenous injection shows the high virulence of this strain in pigeons already demonstrated in chickens (2). However, such a virulence had not been encountered in our previous work with pigeons (3), but the strain used in this experiment was originally isolated from a carrier chicken and up to twice as many spores produced only a chronic infection (2). *A. fumigatus* isolated from a carrier bird may not be highly virulent and chicken isolates generally cause a mild disease in pigeons. Evidence accumulates that considerable variation occurs in the susceptibility of different species of domestic birds to aspergillosis (1). However, a comparison between strains of pigeons and chickens has not been attempted experimentally as far as we are aware. In the light of the present work and from our own observations on natural diseases in these two species, it seems that pigeons may be at least as susceptible as chicken. WALKER (5) produced only hepatic and pulmonary aspergillosis via the intravenous route. This agrees with our earlier experiment (3), but not with the present one. Differences in strains of fungi and experimental design used may result in such discrepancies.

ELMUBARAK (A.K.), FADLELMULA (A.). Pathogenesis of *Aspergillus fumigatus* infection in pigeons in the Sudan. *Revue Élev. Méd. vét. Pays trop.*, 1991, **44** (1) : 26-28

The pathogenesis of a pigeon isolate of *Aspergillus fumigatus* in a local breed of pigeons in the Sudan was tested. The spores inoculated intravenously resulted in an acute disease with 100 % of mortality within six days. At necropsy, pinpoint and milialy lesions were prominent in the liver, spleen, lungs and kidneys. Histopathological examination detected lesions in the liver, heart, lungs, kidneys, spleen and brain. Hyphae and/or spores were encountered in all these organs. The presence of *A. fumigatus* was confirmed by reisolation from the liver, lungs and kidneys. **Key words** : Pigeon - *Aspergillus fumigatus* - Experimental infection - Pathogenesis - The Sudan.

References

1. AINSWORTH (G.C.), AUSTWICK (P.K.C.). Fungal disease of animals. Farnham Royal, Slough, Commonwealth Agric. Bureaux, 1973.
2. FADLELMULA (A.), ABUELGASIM (A.I.), ELMUBARAK (A.K.). Experimental aspergillosis in young chicks. *Revue Élev. méd. vét. Pays trop.*, 1984, **37** (4) : 437-441.
3. FADLELMULA (A.), ELMUBARAK (A.K.). Pathology of experimental aspergillosis in pigeons. *Sudan J. vet. Res.*, 1983, **4** : 77-79.
4. TAYLOR (P.A.). Mycotic pneumonia in pigeons. *Can. vet. J.*, 1966, **7** : 162-263.
5. WALKER (J.). Aspergillosis of the ostrich chick. Union of South Africa, Dept. Agric. Agric. Ann. Rpts, Dir. Vet. Res., 1915, **3-4** : 535-574.