

Communication

Squamous cell carcinoma in sheep in Saudi Arabia

R.O. Ramadan ¹

A.A. Gameel ²

A.M. El Hassan ³

RAMADAN (R.O.), GAMEEL (A.A.), EL HASSAN (A.M.). Carcinome à cellules squameuses chez des moutons d'Arabie Saoudite. *Revue Elev. Méd. vét. Pays trop.*, 1991, 44 (1) : 23-26

Un carcinome à cellules squameuses a été décelé chez 22 moutons Nadji et 3 Maemi, dont 22 femelles, âgés de 3 à 6 ans. Seize de ces tumeurs concernaient l'oeil, sept ont été trouvées dans la peau, en différents endroits du corps, une dans l'oreille et la dernière dans le rectum. Dans cinq cas, des métastases ont été vues dans les ganglions lymphatiques, les fosses nasales et la lèvre supérieure. Une intervention chirurgicale aux premiers stades du développement de la tumeur a été un succès mais, dans les cas les plus avancés, des récurrences ont été notées. Histologiquement, les tumeurs étaient représentatives de ce type de cancer et beaucoup d'entre elles étaient bien différenciées. Les rayons solaires sont un des facteurs étiologiques possibles. *Mots clés* : Ovin - Carcinome - Cellule squameuse - Traitement chirurgical - Arabie Saoudite.

Introduction

Squamous cell carcinoma (SCC) is a frequently recognized form of cancer in domestic animals (16). It has been reported in sheep in different countries particularly Australia where it causes considerable economic losses (14, 15). Various sites for the tumour occurrence in sheep have been described including the ears (7, 10) eyes and peri-orbital tissue (3, 4, 13) ; perineal region (5, 14, 17) and other areas (11, 18). A comprehensive review of the subjects has recently been given by DANIELS and JOHNSON (2).

The present communication describes for the first time, the clinical and pathological aspects and surgical management of SCC in sheep in Saudi Arabia.

Materials and Methods

Twenty-five animals were used in this study. They were presented to the Veterinary Teaching Hospital, King Faisal University, with abnormal outgrowths on the head or other body regions. The general health condition, sex, age, breed, size and location of the outgrowths were recorded, and the presence or absence of metastases noted. The tumors were then removed surgically and the animals kept under observations for 10-14 days. *Post*

mortem examination was conducted in animals that died in the hospital. Tissues for histopathology were collected in 10 % neutral formol saline ; paraffin sections were prepared and stained with haematoxylin and eosin (H & E).

Results

The number, age and breed of sheep investigated and the site of the SCC are indicated in table 1. Twenty-two animals (88 %) were of the Nadji breed and 16 (64 %) had tumours involving the eyes ; 14 were unilateral of which 8 were in an advanced stage of development. A total of 92 % of the affected animals were females and the female/male ratio was 11.5 : 1. The number of animals showing SCC represented about 1.4 % of the surgical cases in the past 3 years.

TABLE 1 Particulars of the sheep affected with squamous cell carcinoma.

Site	No.	Age (years)	Sex	Breed	Remarks
Eyes	16 (64 %)	4-6	F	Najdi	Unilateral (12) Bilateral (2)
Abdomen	2 (8 %)	3-4	F	Naemi	Right caudoventral
Neck	1 (4 %)	5	M	Najdi	Left upper side
Flank	1 (4 %)	5	F	Najdi	Right side
Scapular spine	1 (4 %)	4	F	Najdi	Right side
Chest	2 (8 %)	3	F	Najdi	Right to 7-8 ribs
		3	M	Naemi	Right side
Rectum	1 (4 %)	3	F	Najdi	Grapy and bleeding
Ear	1 (4 %)	4	F	Najdi	Right
Total	25 (100 %)				

Clinical observations

Ocular lesions : the early ocular lesion was observed as an elevated bean shaped outgrowth on the nictitating membrane (photo 1). The eye was clear at first but gradually developed conjunctivitis and corneal opacity (photo 2). Later on corneal ulcers appeared and the peri-orbital tissue was inflamed. In a more advanced stage, the eye was considerably enlarged with subsequent corneal rupture and loss of vision ; peri-orbital structures were greatly involved (photo 3). The lesion had an offensive odour because of secondary infection and infestation with larval stages of flies. Animals at this stage lost their appetite and eventually lost condition.

Four sheep died before operation ; two of them showed ataxia and one had head pushing against the wall.

Tumours at other body sites were noted on the abdomen, neck, ear, flank and chest (photos 4, 5). They varied in shape and size and were covered with dirty scabs the

1. Department of Clinical Studies, King Faisal University, POB 1757, Al-Hasa 31982, Saudi Arabia.

2. Department of Pathology, College of Veterinary Medicine, King Faisal University, Saudi Arabia.

3. Department of Pathology, College of Medicine and Medical Science, King Faisal University, Saudi Arabia.

Reçu le 5.7.1990, accepté le 11.9.1990.

Communication

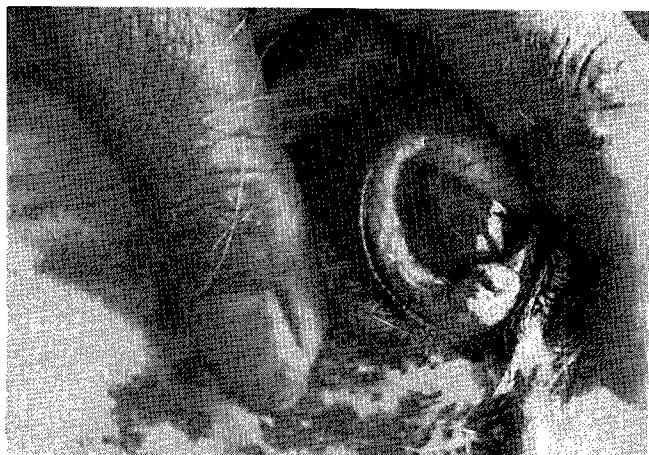

Photo 1 : Early ocular SCC involving the nictitating membrane.



Photo 4 : Keratinized SCC affecting the caudal neck region.

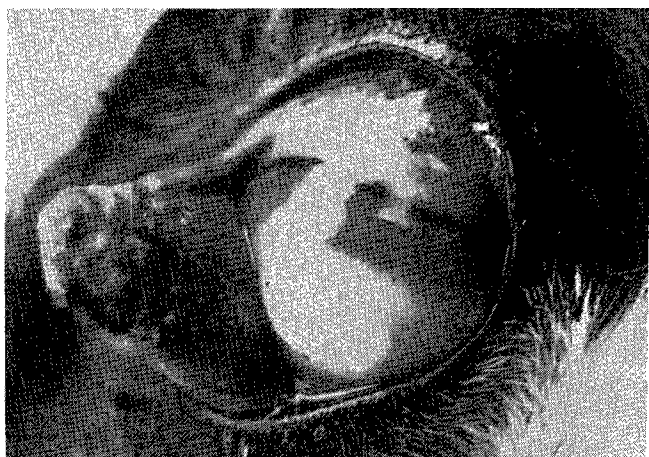

Photo 2 : Early ocular SCC involving the nictitating membrane. Note purulent conjunctivitis and corneal opacity.



Photo 5 : SCC at the flank region. Note enlarged precrural (pre-femoral lymph node) arrow.

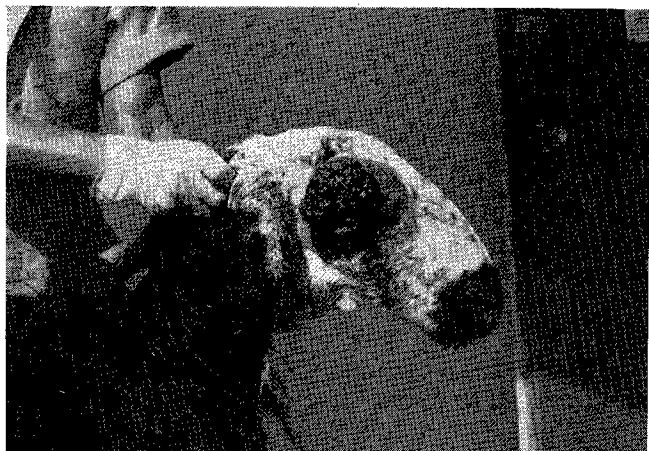

Photo 3 : Advanced stage of ocular SCC replacing the eye and periocular tissue.

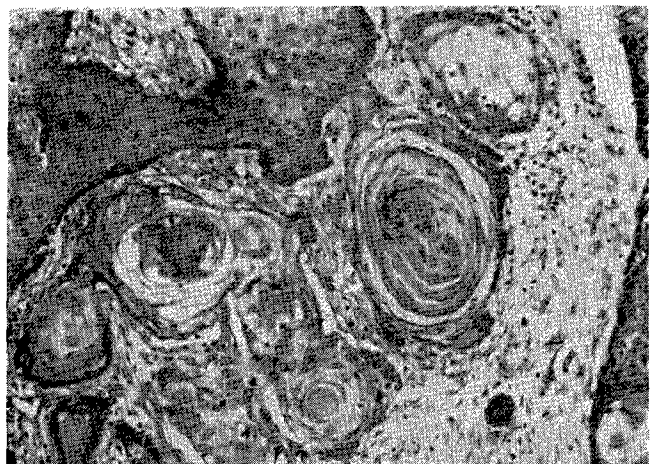

Photo 6 : SCC showing islands of epithelial cells enclosing keratin pearls (H & E x 200).

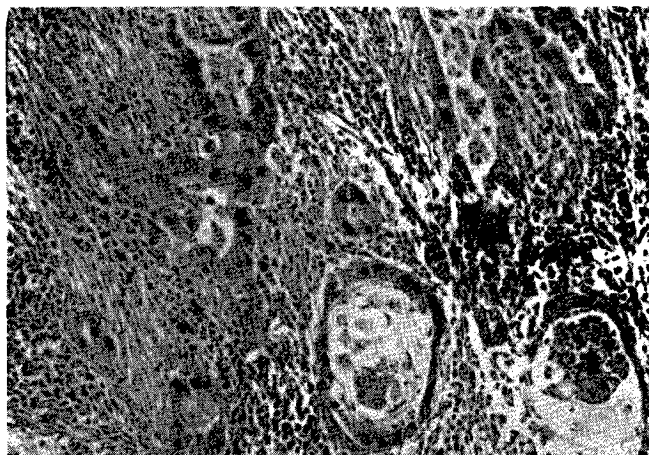


Photo 7 : SCC showing cells arranged in pseudoglandular pattern with stroma showing inflammatory cell infiltration (H & E x 320).

removal of which revealed rough velvety bleeding surfaces. The outgrowth was raised above the skin and was freely movable. The tumor in the rectum was grape-like in shape and was bleeding profusely.

Surgery

The animals were sedated with xylazine (2 % Rompun Bayer) at the rate of 0.2 mg/kg body weight given intravenously. This was followed by a local infiltration analgesia for the body tumours or retrobulbar block for the ocular tumours. The growth affecting the third eye-lid was removed with the nictitating membrane.

Bleeding was controlled with a haemostat or with a single ligature placed around the base of the tumour using an absorbable suture material of fine calibre. In the advanced stage the whole eye was removed together with the peri-orbital tissues and lacrimal gland. Tumours affecting other body regions were easy to remove. An elliptical incision was made around the outgrowth and the tumour was then dissected with a liberal margin of healthy skin. Routine skin closure was made. Each animal was given an antibiotic cover locally and systematically for 5 days. Ophthalmic antibiotic ointment was applied daily following removal of early ocular tumours.

Surgical removal of the tumours was achieved successfully without serious complications. Healing progressively occurred within 14 days and was quicker in animals operated for early tumours. All animals were discharged thereafter.

Three animals were re-admitted within 2-3 months because of local recurrence of the lesions in the eyes (two) and body sites (one) ; these animals died in about 3 weeks.

Pathology

At necropsy the following was observed : carcass condition was poor ; rumen reduced in size ; intestines were empty and showed slight mucosal congestion and the liver was pale and friable. In animals with advanced ocu-

lar tumours the eyeball was completely destroyed with wide involvement of peri-orbital structures. The tumours had an ulcerated keratinized surface with foul odour. Sagittal section of the head in one animal showed a round area of tumour mass about 4 cm in diameter on the nasal passage. Another case had an elevated outgrowth area about 2 cm in diameter to the left of the upper lip.

Histologically, sections showed islands of squamous cells with distinct intercellular bridges and epithelial pearls (photo 6). In many areas the lesions were ulcerated and showed haemorrhages. Squamous cells were sometimes seen infiltrating deep and growing into blood vessels. The stroma exhibited acute and chronic inflammatory reaction cells and in many areas eosinophils appeared in large numbers : small abscesses were occasionally seen. In one section involving the eyelid the tarsal plate was completely destroyed and in another the tumour growth replaced a lymph node. Two poorly differentiated tumours were seen with uniform cells, having large nuclei, arranged in a pseudoglandular pattern. There were many mitotic figures (photo 7).

Discussion

Of the 25 cases investigated here, 16 (64 %) were ocular and most of them were unilateral. Eight (50 %) were in an advanced stage of development associated with impaired or total loss of vision. The progression of the lesion appeared to be similar to that of bovine ocular squamous cell carcinoma (16). Among the remaining 9 cases mainly involving the skin of the body sites, only one occurred in the rectum, one in the ear and none in the perineal region. This suggests that the ocular SCC is frequent in sheep in Saudi Arabia. In other countries, however, the perineal region and the ear seem to be more frequently affected (5, 7, 8, 10, 13).

The gross and histopathological features of the tumours were typical for SCC (6, 12) and most of them were well differentiated. Local spread has been noticed in five different cases ; in nasal passage (one), upper lip (one) parotid (one) and pre-crural lymph node (two) ; the last two had tumour in the abdominal skin. Generally SCC are considered to be low metastasizing tumours, spreading mainly through lymphatics (2, 16).

Twenty three (92 %) of the affected animals were 3-6 year old females. Previous reports indicate that females are mostly affected and that incidence of SCC increases with age, being very low in animals less than 4 years old (4, 7, 9). Our findings suggest that younger animals (3 years old) can be very susceptible. The low incidence in males is probably because they are usually slaughtered at a young age (less than 3 years) before tumour development occurs.

The present study indicates that surgical treatment of the tumour is possible with great success in the early cases. In late cases recurrences may be high, mainly at the initial sites of excision, probably because of deep infiltration of underlying tissues which makes radical excision rather difficult. However, surgery remains to be the most appro-

Communication

appropriate method of therapy of SCC in veterinary medicine. Other methods of treatment applicable to human medicine (chemotherapy, immunotherapy, radiotherapy and endocrine gland ablation...) could be attempted in valuable animals or for research purposes.

Solar radiation has been incriminated in the causation of SCC in areas devoid of or sparsely covered by wool and in non pigmented skin. However, other factors may be involved especially with regard to tumours occurring in well protected areas (body sites) or in sites like the rectum (1, 2).

In Saudi Arabia grazing sheep might be highly exposed to solar radiation in areas of little natural shelter or shade especially during the hot dry summer month (June-August). In most of the country, summer temperature may exceed 45 °C and is associated with long sunshine hours (10-13 h) and high solar radiation (500-600 langleys per day) (19). Moreover, reflection of sunlight may be considerable. This could be of significance in the development of SCC in sheep in Saudi Arabia.

RAMADAN (R.O.), GAMEEL (A.A.), EI HASSAN (A.M.). Squamous cell carcinoma in sheep in Saudi Arabia. *Revue Élev. Méd. vét. Pays trop.*, 1991, **44** (1) : 23-26

Squamous cell carcinoma was recorded in 22 Nadji and 3 Maeimi sheep aged 3-6 years, of which 22 were females. Sixteen tumours involved the eyes, 7 occurred in the skin at different body sites, one developed in the ear and another in the rectum. In five cases secondary deposits were seen in the lymph nodes, nasal passages and upper lip. Surgical treatment was successful in the early stages of tumour development, but in advanced cases recurrences were noted. Histologically the tumours were typical for squamous cell carcinoma and most of them were well differentiated. Solar radiation was pointed out as a possible factor in the aetiology of the tumour. *Key words* : Sheep - Squamous cell carcinoma - Surgical treatment - Saudi Arabia.

References

- COTCHIN (E.). Veterinary oncology : a survey. *J. Path.*, 1984, **142** : 101-127.
- DANIELS (P.W.), JOHNSON (R.H.). Ovine squamous cell carcinoma (Review article). *Vet. Bull.*, 1987, **57** : 153-167.
- DAVIS (C.L.), SHORTEN (H.L.). Carcinoma of the eye of sheep. *J. Am. vet. med. Ass.*, 1952, **121** : 20-24.
- FASSI-FEHRI (N.), FASSI-FEHRI (M.). Quelques observations sur les carcinomes vulvaires et palpébraux de la brebis. *Maroc méd.*, 1972, **52** : 700-710.
- HAWKINS (C.D.), SWAN (R.A.), CHAPMAN (H.M.). The epidemiology of squamous cell carcinoma of the perineal region of sheep. *Aust. vet. J.*, 1981, **57** : 455-457.
- JONES (T.C.), HUNT (R.D.). *Veterinary pathology*. 5th ed. Philadelphia, Lea and Febiger, 1983. P. 1109-1111.
- LADDS (P.W.), ENTWISTLE (K.W.). Observation on squamous cell carcinoma of sheep in Queensland, Australia. *Br. J. Cancer*, 1977, **35** : 110-114.
- LAGARDIC (M.), WYERS (M.), MIALOT (J.P.), PARODI (R.L.). Observation d'une enzootie de cancers de la vulve chez la brebis. *Zentbl. VetMed.*, 1982, **29** : 123-135.
- LLOYD (L.C.). Epithelial tumours of the skin of sheep (tumours of areas exposed to solar radiation). *Br. J. Cancer*, 1961, **15** : 780-789.
- LOMBARD (C.), MAGNOL (J.P.). Premier cas d'épithélioma auriculaire chez le mouton en France. *Bull. Acad. vét. Fr.*, 1972, **45** : 349-362.
- MISK (N.A.), NIGAM (J.M.), RIFAT (J.F.). Surgical management of squamous cell carcinoma and papillomatosis in cattle and sheep. *Vet. Med. Rev.*, 1984, **2** : 144-153.
- RAMADAN (R.O.). Squamous cell carcinoma of the perineum of the goat. *Br. vet. J.*, 1975, **113** : 347-350.
- RIET-CORREA (F.), CASSAL (A.B.), SCARSI (R.M.), SCHILD (A.L.), MENDES (M.C.). Carcinomas epidermoides em ovinos em uma estabel ; ecimeto de Rio Grande do Sul. *Pesq. vet. brasil.*, 1981, **1** : 65-68.
- SWAN (B.A.), CHAPMAN (H.M.), HAWKINS (C.D.), HOWELL (J.M.C.), SPALDING (V.T.). The epidemiology of squamous cell carcinoma of the perineal region of sheep : abattoir and flock studies. *Aust. vet. J.*, 1984, **61** : 146-151.
- SWAN (B.A.), WYBURN (R.A.), CHAPMAN (H.M.). Tail lesions in merino lambs. *Aust. vet. J.*, 1980, **56** : 439-441.
- THEILEN (G.H.), MADEWELL (B.R.). *Veterinary cancer medicine*. Philadelphia, Lea and Febiger, 1987. P. 233-266.
- VANDERGRAAFF (R.). Squamous cell carcinoma of the vulva in merino sheep. *Aust. vet. J.*, 1976, **52** : 21-23.
- VANSELOW (B.A.), SPRADBROW (P.B.). Papillomaviruses, papillomas and squamous cell carcinoma in sheep. *Vet. Rec.*, 1982, **110** : 561-562.
- Water Atlas of Saudi Arabia. Ryad, Ministry of Agriculture and Water, 1984.

Pathogenesis of *Aspergillus fumigatus* infection in pigeons in the Sudan

A.K. Elmubarak ¹

A. Fadlelmula ²

ELMUBARAK (A.K.), FADLELMULA (A.). Pathogénèse de l'infection à *Aspergillus fumigatus* sur une race locale de pigeon au Soudan. *Revue Élev. Méd. vét. Pays trop.*, 1991, **44** (1) : 26-28

Les auteurs étudient la pathogénèse d'un isolat d'*Aspergillus fumigatus* sur une race locale de pigeon au Soudan. L'injection intraveineuse de spores a entraîné une affection aiguë avec 100 p. 100 de mortalité dans les six jours suivants. A l'autopsie, des lésions miliaires en pointe d'épingle prédominaient dans le foie, la rate, les poumons et les reins. L'examen histopathologique a révélé des lésions dans le foie, le coeur, les poumons, les reins, la rate et le cerveau. Des hyphes et/ou des spores ont été trouvés dans tous ces organes. La présence d'*Aspergillus fumigatus* a été confirmée par réisolement à partir des lésions du foie, des poumons et des reins. *Mots clés* : Pigeon - *Aspergillus fumigatus* - Infection expérimentale - Pathogénèse - Soudan.

Introduction

A. fumigatus is the commonest cause of avian aspergillosis. The disease is acute in young birds and runs a chronic course in mature ones (1) In pigeons, the natural disease was described as mycotic pneumonia (4), but mycotic granulomas were also encountered (5). It has been shown (1, 3) that this species could be experimentally infected with *A. fumigatus*.

A strain isolated from a natural severe pneumomycosis in pigeons was used to study the pathogenesis of an acute *A. fumigatus* infection.

1. Veterinary Research Laboratories, POB 8067, Alamarat, Khartoum, Sudan.

2. 19 Carton House, Dickens Estate, Marine Street, London SE16 4TA, United Kingdom.

Reçu le 26.7.1990, accepté le 23.10.1990

* May & Baker. ** Pfizer.