

## Communications

### Clinical use of tissue adhesives in the closure of udder wounds in lactating ewes and goats

A.E. Bolbol<sup>1</sup>

Y.A. Al-Gasnawy<sup>1</sup>

**BOLBOL (A.E.), AL-GASNAWY (Y.A.).** Emploi clinique d'adhésifs tissulaires pour la fermeture des plaies de la mamelle chez les brebis et les chèvres en lactation. *Revue Elev. Méd. vét. Pays trop.*, 1991, **44** (4) : 409-411

Vingt-sept plaies de la mamelle chez des brebis et des chèvres en lactation ont été traitées puis refermées avec un adhésif tissulaire de synthèse. Vingt-quatre ont cicatrisé par première intention (89 p. 100) et 2 à la fois par première et par seconde intentions partielles. Enfin, on a déploré un échec avec formation d'une fistule. D'une manière générale, la fermeture des plaies cutanées sans suture, grâce à cet adhésif tissulaire, s'est révélée un procédé satisfaisant et efficace chez les petits ruminants. *Mots clés* : Brebis - Chèvre - Adhésif tissulaire - Mamelle - Plaie - Arabie Saoudite.

#### Introduction

Some studies have examined the use of tissue adhesives for repair of experimental teat fistulas in non lactating and lactating cows (1, 2). These authors have reported successful healing rates ranging from 41 to 91 %. But until now most of the available literature concerning the use of nonsuture tissue adhesive of closure of such tissues does not exceed the experimental level.

The aim of the present work is to evaluate the efficiency of tissue adhesive\* on closure of various clinical teat and udder wounds in ewes and goats.

#### Materials and Methods

During the academic year 1989-1990, a total of 58 lactating ewes and goats with different forms and shapes of udder and teat wounds were admitted to the Veterinary Teaching Hospital of the King Faisal University, Saudi Arabia. Most of the wounds either occurred on the skin of the udder (photo 1) or involved the udder tissue (photo 2). There were only few cases of teat wounds including the cistern (photo 3). Twenty-four goats and three ewes were treated with the tissue adhesive, while the rest were treated as usual.

The animals were given an intramuscular dose of xylazine HCl (Rompun<sup>®</sup> Bayer, Germany) for anesthesia and myorelaxation at a dose of 0.2 mg/kg of body weight, and then placed in lateral recumbancy with legs secured by rope. After surgical preparation of the udder, the wounds were refreshed using spoon curette and scalpel to remove all the dead tissues with trimming of the edges. The wound lips were then cleaned of blood and tissue debris using a gauze sponge and a digital pressure was applied to control haemorrhage.

If minor bleeding occurred, haemostasis was achieved with a mosquito haemostat. A thin layer of Superglue<sup>®</sup> tissue adhesive was applied to the edges of the incision. The everted edges were then brought into opposition by a flat-tipped forceps. Moderate pressure was applied for 30 sec to initiate polymerization.

Post-operative treatment consisted in applying a tetracycline spray after completion of tissue adhesive polymerization. The udders were examined two weeks after the treatment.

#### Results

The healing process was evaluated on the basis of clinical observation of primary healing, secondary healing with partial or total rupture of the wound, failure of healing with formation of a fistula.

It was observed that most of the cases were presented to the clinic during the winter season (December-March). Thirty-two cases were recorded at that time (55.2 %). Only three ewes (5.2 %) were admitted to the clinic with udder wounds, the majority of cases affecting the goats (94.8 %).

By gross observation, primary healing occurred in 3 ewes (100 %) and in 21 out of 24 goats (87.5 %) there was nearly complete healing of the skin. Two cases out of 27 (7.4 %) partially failed to heal by first intention. The parts that partially did not heal primarily, were refreshed again and tissue adhesive was applied. These were completely healed. The remaining wound partially failed to heal and developed milk fistula. This wound was refreshed again *in situ*, and treated as usual with simple interrupted sutures.

#### Discussion

Udder wounds were greater in goats than in ewes. This may be due to the fact that many goats have either pendulous or big udders which are more subject to trauma from the ground or from the wired fence of the farm. In sheep, the udder is smaller and less developed than in goats. In addition, skin of the udder of the goat is much thinner than that of the sheep, a feature which predisposes the goat's udder to be wounded more easily.

Observations of the healing process revealed healing by primary intention in 24 wounds out of 27 (90 %) GRZYMER *et al.* (2) used the same Superglue<sup>®</sup> from experimentally induced wounds of mammary papilla incisions with primary healing compared with 3 of 8 nonglued incisions. They also recorded that 3 glued incisions had secondary healing and one exhibited a wound dehiscence and development of milk fistula. Inadequate haemostasis and moist incision edge resulted in dehiscence.

1. Department of Clinical Studies, College of Veterinary Medicine and Animal resources, King Faisal University at Al-Hasa, POB 1757 Hofuf 31982, Saudi Arabia.

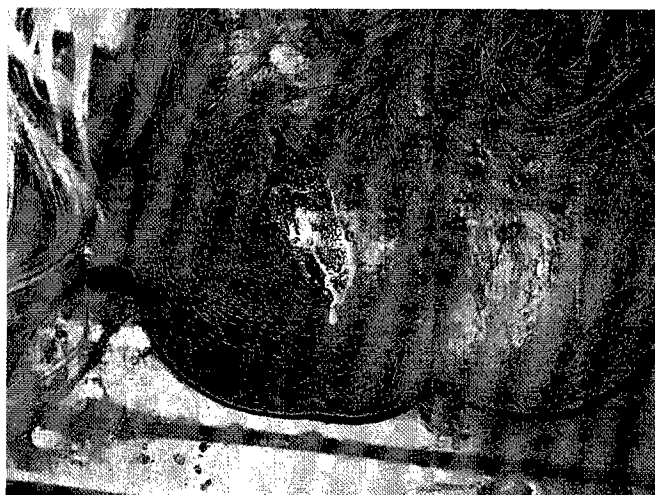Reçu le 20.8.1991, accepté le 6.1.1992.

\* Superglue, Duro Loctite Corp., Cleveland, Ohio, USA.

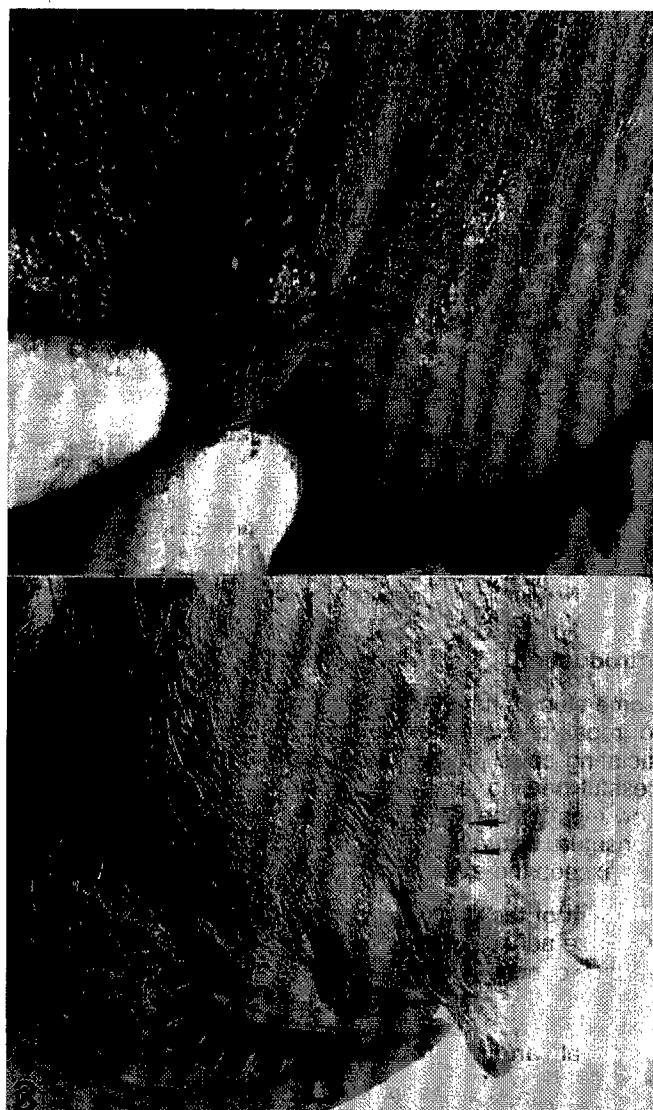
## Communications



*Photo 1 : A) Skin wound in the teat and udder of an ewe ; B) the same wound following use of tissue adhesive.*



*Photo 2 : A wound in a goat involving udder tissue as indicated by leakage of milk.*



*Photo 3 : A) A wound involving teat cistern ; B) primary healing occur in the wound one week following use of the adhesive.*

It should be emphasized that the wound edges and surfaces must be completely dry. If any blood is oozing, the monomer polymerizes with the blood before the surface binding action takes place causing failure of the binding (3). The cyanacrylates are the group of materials that have been used most extensively as tissue adhesive. These adhesives are most successful when used on surface wounds where the material can be sloughed after a period of 5 to 7 days.

### Conclusion

Tissue adhesives used in deep wounds for long periods of time may stimulate a foreign body reaction (4). But the present study concludes that they offer a viable alternative to sutures for repair of udder wounds in ewes and goats. The time required for healing is significantly shorter.

ter. Direct approximation of the wound lips occurs with a minimum amount of tissue adhesive as well as a minimum of complication in 90 % of the cases.

**BOLBOL (A.E.), AL-GASNAWY (Y.A.).** Clinical use of tissue adhesives in the closure of udder wounds in lactating ewes and goats. *Revue Elev. Méd. vét. Pays trop.*, 1991, **44** (4) : 409-411

Twenty-seven udder wounds in lactating goats and ewes were treated and closed with synthetic tissue adhesive. Twenty-four healed by primary intention (89 %), two wounds were partially healed by primary intention and partially by second intention and a wound failed to heal and developed milk fistula. In general, non suture closure of skin wounds using tissue adhesive proved to be satisfactory and highly efficient in small ruminants. *Key words* : Ewe - Goat - Tissue adhesive - Udder - Wound - Saudi Arabia.

#### References

1. AGGER (J.F.). Behandling af kirurgiske pattesar med vaevslim. *Dansk Veterinaertidsskrift*, 1982, **65** : 778-784.
2. GRIMER (J.), WATSON (G.L.), COY (C.H.), PRINDLE (L.V.). Healing of experimentally induced wounds of mammary papilla (teat) of the cow : Comparison of closure with tissue adhesive versus nonsutured wounds. *Am. J. vet. Res.*, 1984, **45** (10) : 1979-1983.
3. SAMY (M.T.), BOLBOL (A.E.), BAYOUMI (A.H.), MOUSTAFA (A.). Nonsuture repair of the urinary bladder in dogs. 2nd Sci. Congr. Faculty of Veterinary Medicine. Assiut Univ., 1986. P. 359-369.
4. SILVER (I.A.). Tissue adhesives. *Vet. Rec.*, 1976, **98** (20) : 405-496.

## First report of an infectious bursal disease outbreak in a vaccinated chicken flock in Anambra State, Nigeria

O. Onunkwo<sup>1</sup>

J.O.A. Okoye<sup>2</sup>

**ONUNKWO (O.), OKOYE (J.O.A.).** Première relation d'un foyer de bursite infectieuse (maladie de Gumboro) dans l'État d'Anambra au Nigeria. *Revue Elev. Méd. vét. Pays trop.*, 1991, **44** (4) : 411-414

La maladie de Gumboro est apparue dans un élevage de poulets déjà vaccinés et âgés de sept semaines. Les signes cliniques et les modifications décelées post-mortem ont été classiques, tout comme la pathologie de la bourse à l'examen microscopique. Des broyats homogénéisés de bourse provenant d'animaux morts, ont réagi positivement à l'antigène viral en cause avec le test d'immunodiffusion en gélose (IDG). Des sérums de convalescents obtenus 14 jours après l'apparition des signes cliniques ont également donné une réaction positive au test IDG. Des animaux sensibles, âgés de sept semaines, infectés par voie intramusculaire avec 0,1 ml d'une préparation de bourse provenant du même foyer, ont développé, dès le 3<sup>e</sup> jour, les signes cliniques de la maladie et sont morts au sixième jour. La réaction du contenu de la bourse était également positive à l'antigène viral en milieu IDG. Ceci constitue la première observation d'un foyer reconnu de maladie de Gumboro au Sud-Nigeria, consécutif à l'injection d'un vaccin produit localement. *Mots clés* : Volaille - Poulet - Maladie de Gumboro - Vaccin - Virus sérotype 1 - Nigeria.

1. National Veterinary Research Institute, Vom, Nigeria.

2. Department of Veterinary, Pathology and Microbiology, University of Nigeria, Nsukka, Nigeria.

Reçu le 14.5.1991, accepté le 29.11.1991.

## Introduction

Infectious bursal disease (IBD) has been reported in Nigeria in chickens as young as 9 days and as old as 20 weeks (5, 6). For protective inoculation, both imported and locally produced live vaccines are available.

Field outbreaks of IBD in vaccinated flocks cause considerable concern and panic in the poultry industry especially in developing economies where the cost of inputs is high. IBD outbreak in chickens has been reported in Northern Nigeria following inoculation with imported and locally produced vaccines (1, 4), but in the Southern part of the country, such confirmed cases had never been previously recorded. This paper reports the first outbreak of IBD in Southern Nigeria in a flock of chickens 35 days after inoculation with a locally produced vaccine.

## Materials and Methods

### Flock history

The affected birds were 7-week-old hybrid layer chicks hatched locally and reared commercially on deep litter. They were vaccinated against Newcastle's disease when day-old and against IBD at 12 days of age.

### Clinical signs

On the 35th day of inoculation against IBD, about 90-95 % of the birds became depressed, lost interest in feed and water and developed a shaggy puffed-up plumage and yellowish watery faeces. Prostration was generally followed by death and mortality was 15.7 %.

### Post mortem and histological changes

A large majority of the dead birds were examined for gross lesions and the Fabricius bursa was processed for histopathology.

### Bacteriology and parasitology

Heart blood and bursal preparations were cultured on blood agar and portions of the intestine examined for helminth ova and protozoa.

### Virus isolation

Bursae of 15 dead birds were prepared in phosphate buffered saline and tested for IBD virus antigen by agar gel diffusion test. A known positive IBD antigen and antiserum were incorporated into the tests.

### Serology

Twenty-five convalescent serum samples, taken from survivors 14 days after the onset of the clinical signs, were inactivated at 56 °C for 30 min and examined for IBD virus antibody in AGDT.