

Communication

First report of heartwater (cowdriosis) in Kafue lechwe (*Kobus leche kafuensis*) in Zambia

G.S. Pandey ¹D. Minyoi ¹F. Hasebe ¹E.T. Mwase ¹

PANDEY (G.S.), MINYOI (D.), HASEBE (F.), MWASE (E.T.). Premiers cas de cowdriose chez des antilopes (*Kobus leche kafuensis*) en Zambie. *Revue Élev. Méd. vét. Pays trop.*, 1992, 45 (1) : 23-25

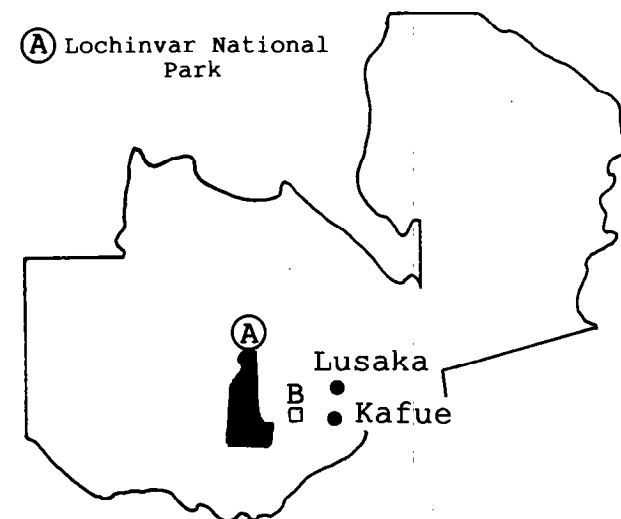
La cowdriose a été diagnostiquée chez des antilopes de Kafue (*Kobus leche kafuensis*) transférées dans leur région, sur la base des symptômes cliniques, d'autopsie et d'examen de laboratoire. La maladie se caractérise par une hyperesthésie, une démarche circulaire, raide et saccadée sur la pointe des onglons, et des cas de mortalité. Les animaux étaient fortement infestés de tiques *Amblyomma*. L'autopsie a révélé la présence d'hydrothorax, d'hydropéricardes, d'ascites et de splénomégalie. Les frottis de broyats de cerveaux colorés au Giemsa ont révélé la présence de rickettsies typiques au sein des cellules endothéliales des capillaires. La maladie semble se disséminer, par l'intermédiaire du vecteur, du bétail infecté aux antilopes nouvellement introduites. Ceci constitue les premiers cas rapportés de cowdriose chez les antilopes. Malheureusement, il apparaît difficile de prendre des mesures préventives chez le gibier. *Mots clés* : Antilope - *Kobus leche kafuensis* - Cowdriose - *Amblyomma* spp. - *Cowdria* - Symptôme - Zambie.

Introduction

The Kafue lechwe (*Kobus leche kafuensis*), a medium size antelope found in large numbers in the Lochinvar National Park of Zambia (map 1) is a great source of tourist attraction. This park has an area of 410 km², a flood plains on the Southern side of the Kafue river and a place of concentration of Kafue lechwe. The park is situated in the Southern Province of Zambia about 168 km South of Lusaka.

The Kafue lechwe is endemic to Zambia and occurs in one large population on the Kafue flats. An aerial census of the Kafue flats in November, 1987 revealed a population estimate of 50 700 ± 17.500 lechwe (7). However, in 1970-1972 the Kafue lechwe population was estimated to be 90-95 000 ± 10-20 000 (2).

Kafue lechwe is an antelope with a rather short and conical muzzle, and the hind quarters noticeably higher than the shoulder. The general colouration is bright



Map 1 : A : map of Zambia showing location of Kafue lechwe in Lochinvar National Park. B : location of translocated Kafue lechwe captured from A.

chesnut. The average weight may range from 85 to 140 kg. Females are similar to males, more lightly built without horns. Being semi-aquatic in nature, they like swamps and wetland. The lechwe feed on grass and water plants.

Heartwater is regarded as one of the most important and often fatal disease of domestic ruminants in Southern Africa (14). The natural host range of heartwater in domesticated and wild ruminants, long known in Africa and more recently recognised in the Caribbean, is ill-defined (11). DILLMANN (5), while studying the diseases of lechwe in Zambia did not record heartwater.

Most reports on the disease in wild animals have been incidental and of a cursory nature (10). Cases of heartwater reported among African ruminants include black wildebeest (*Connochaetes gnu*), blesbok (*Damaliscus dorcas phillipsi*), springbuck (*Antidorcas marsupialis*), bushbuck (*Tragelaphus scriptus*), sitatunga (*Tragelaphus spekei*), eland (*Taurotragus oryx*) and extra African ruminants such as white-tailed deer (*Odocoileus virginianus*), fallow deer (*Dama dama*), rusa deer (*Cervus timorensis*), bison (*Bison* spp.), water buffalo (*Bubalus arnee*), barbary sheep (*Ammotragus lervia*), Himalyan tahr (*Hemitragus jemlahicus*), nilgai (*Boselaphus tragocamelus*), blackbuck (*Antilope cervicapra*).

The recent authoritative reviews by YOUNG (15), CAMUS and BARRÉ (4), UILENBERG (13) and OBEREM and BEZUIDENHOUT (10) do not list lechwe as the host of heartwater. The present paper reports its occurrence for the first time in the translocated Kafue lechwe in Zambia.

1. School of Veterinary Medicine, University of Zambia, POB 32379, Lusaka, Zambia.

Reçu le 24.4.1991, accepté le 24.2.92.

Communication

Materials and Methods

Presentation

With a view to promote game ranching, during September 1988 a total of 170 Kafue lechwe were captured from their original native habitat of Lochinvar National Park and translocated to Kafue flats on the bank of the Kafue river about 30 km South-west of Kafue town (map 1). They were then maintained on a large, electrically fenced uncleared stretch of land. Before release the lechwe were examined and found free of tick infestation or any other observable physical abnormality. After about three months, by the beginning of January 1989, the lechwe started dying. In about two months time, by the end of February, forty-six of them died. These animals formed the basis of the study. The specimens were brought to our laboratory for investigation by the farmer and also the farm was visited several times by us.

Clinical symptoms

The clinical symptoms observed in some of the affected lechwe were hyperaesthesia, circling with stiff and unsteady high and long stepping gait. Close clinical examination was not possible as lechwe were kept almost in a natural wild condition and not in captivity. Sometimes death was reported as sudden.

Results

Post-mortem examination

Post-mortem examination was conducted in six adult lechwe (2 males and 4 females). Three of the females were in advanced pregnancy. Many *Amblyomma variegatum* ticks were present around the anus, penis, vulva, abdomen and ear. At some places, they were in small groups of largely engorged ticks deeply penetrated into the skin and difficult to remove. Necropsy revealed marked general congestion, hydrothorax, hydropericardium, pulmonary oedema, ascites and splenomegaly. Severe congestion and oedema in abomasum and enteritis was noticeable. Large numbers of mature *Amphistomes* in the rumen and *Haemonchus* in the abomasum were present. Hydrothorax containing 1.5-2 l of yellow thick straw-coloured fluid with flakes of fibrin, was observed.

The lungs were excessively oedematous and showed marbling appearance. The mediastinum and associated lymphnodes were oedematous. The trachea and bronchi were congested and some contained sero-fibrinous exudate. The thoracic fluid clotted in half an hour and appeared like yellow gelly. Congestion of brain vessels was noticed as well as oedema and enlargement of the liver. Prescapular, parotid and mesenteric lymphnodes were enlarged and oedematous. Splenomegaly was a constant feature. In two of the cases, kidneys were swollen and congested. In all cases hydropericardium with yellow straw-coloured fluid (150-200 ml) and fibrin flakes were visible.

Laboratory examination

Faecal examination was found positive for nematode ova. Smears of blood, lymphnode and spleen stained with Giemsa did not reveal any haemoparasite. Internal organs and thoracic fluid collected, taking sterile precautions, and subjected to bacteriological culturing, yielded no significant bacteria. Ticks were identified as *Amblyomma variegatum*. Brain crush smears fixed in methanol and stained with Giemsa revealed numerous groups of characteristic colonies resembling *Cowdria ruminantium* which appeared as reddish purple to blue in endothelial cells of the brain capillaries (photo 1).



Photo 1 : Brain crush smear showing rickettsial bodies in the capillary endothelial cells (arrows).

Histopathological examination conducted on different tissues did not reveal any characteristic significant microscopic change except mild focal myocardial necrosis and interstitial and glomerular scanty mononuclear cell infiltration in the kidney. Brain showed moderate congestion and oedema. An alveolar and interstitial oedema and sometimes fibrinous exudate in the alveoli of the lungs, were present.

Discussion

This appears to be the first report of heartwater in lechwe. The clinical symptoms and gross lesions, the presence of the vector *Amblyomma variegatum* as well as the demonstration of the causative agent in the endothelial cells of blood vessels of the brain are indicative of the spontaneous occurrence of the disease in small ruminants (8, 12). In Zambia, cases have been reported in cattle, sheep and goats and mortality among the above domestic ruminants, mostly occurring during the rainy season (3). Zambia is rich in wildlife, however, heartwater has never been recorded in wild ruminants.

In the present case, the lechwe were translocated to an endemic heartwater area and mortality started among the

animals within three months after their arrival. During night time, the lechwe moved along the border of the fence and during day-time cattle closely grazed on the opposite side. Hence the disease might have possibly spread from the infected cattle to the healthy lechwe through the vector. HENNING (6) and NORVAL (9) reported heavy losses due to heartwater in domestic ruminants when animals were newly introduced into an endemic area of the disease. Moreover, the present translocation was done just before the rainy season and this could have contributed to activity of the vector and transmission of the disease.

The possibility that the disease may in fact be due to a relapse caused by the stress of translocation should also be considered, especially as the carrier state has recently been shown to exist (1).

Conclusion

The present report adds another susceptible host of heartwater and clearly indicates that this disease is fatal in this species. Therefore, while considering game ranching or translocation to heartwater endemic areas, preventive measures should be taken before arrival of the game, but unfortunately prevention is not easily feasible.

Acknowledgements

The authors are thankful to Mrs A. FLYNN, farm manager, for cooperation and assistance.

PANDEY (G.S.), MINYOI (D.), HASEBE (F.), MWASE (E.T.). First report of heartwater (cowdriosis) in Kafue lechwe (*Kobus leche kafuensis*) in Zambia. *Revue Élev. Méd. vét. Pays trop.*, 1992, **45** (1) : 23-25

Heartwater was diagnosed among translocated Kafue lechwe (*Kobus leche kafuensis*) based on clinical symptoms, necropsy and laboratory examination. The disease was characterised by hyperaesthesia, circling with stiff and unsteady high stepping gait and mortality. The animals were heavily infested with *Amblyomma* ticks. Autopsy revealed hydrothorax, hydroperi-

cardium, ascites and splenomegaly. Brain crush smears stained with Giemsa revealed characteristic rickettsial bodies in the capillary endothelial cells. The disease is attributed to spreading from infected cattle to newly introduced lechwe through the vector. This is the first published report of occurrence of heartwater in lechwe. Unfortunately prevention is not easily feasible in game animals. **Key words** : Antelope - *Kobus leche kafuensis* - Heartwater - *Amblyomma* spp. - Cowdria - Symptom - Zambia.

References

1. ANDREW (H.R.), NORVAL (R.A.I.). The carrier status of sheep, cattle and African buffalo recovered from heartwater. *Vet. Parasitol.*, 1989, **34** (3) : 2661.
2. BELL (R.H.V.), GRIMSDELL (J.J.R.), VAN LAVIEREN (L.P.), SAYER (J.A.). Census of the Kafue lechwe by aerial stratified sampling. *East Afr. J.*, 1973, **11** : 55-74.
3. Bureau interafricain de la Santé animale. Rickettsiose bovine, 1965 (carte n° 149). Distribution géographique des maladies. *Bull. Épiz. Afr.*, 1966, **14** : 335.
4. CAMUS (E.), BARRÉ (N.). La cowdriose (heartwater). Revue générale des connaissances. Maisons-Alfort, IEMVT, 1982. (Études et Synthèses de l'IEMVT n° 4)
5. DILLMANN (J.S.S.). Final report. Veterinary wildlife research section. Vol. I. Department of Veterinary and Tsetse Control Services. Zambia, 1972.
6. HENNING (M.W.). Animal diseases in South Africa. 3rd ed. South Africa, Central News Agency Ltd., 1956. P. 1115-1179.
7. HOWARD (G.W.), JEFFERY (R.C.V.). Kafue lechwe population census, November 1987. Report to National Parks and Wildlife Service. Chilanga, Lusaka, 1987.
8. ILEMOBADE (A.A.), LEEFLANG (P.). Epidemiology of heartwater in Nigeria. *Revue Élev. Méd. vét. Pays trop.*, 1977, **30** (2) : 149-155.
9. NORVAL (R.A.I.). The epidemiology of heartwater. *The Kenyan Veterinarian*, 1988, **12** (2) : 9-11.
10. OBEREM (P.T.), BEZUIDENHOUT (J.D.). Heartwater in hosts other than domestic ruminants. *Onderstepoort J. vet. Res.*, 1987, **54B** : 271-275.
11. OKOH (A.E.J.), OYETUNDE (I.L.), IBU (J.O.). Fatal heartwater in captive sitatunga. *Vet. Rec.*, 1986, **118** (25) : 696.
12. SMITH (H.A.), JONES (T.C.), HUNT (R.D.). Veterinary pathology. Philadelphia, Lea and Febiger, 1972. P. 540.
13. UILENBERG (G.). Heartwater (*Cowdria ruminantium*) infection. Current status. *Adv. Vet. Sci. Comp. Med.*, 1983, **27B** : 427-480.
14. VAN DE PYPEKAMP (H.), PROZESKY (L.). Heartwater. An overview of the clinical signs, susceptibility and differential diagnosis of the disease in domestic ruminants. *Onderstepoort J. Vet. Res.*, 1987, **54B** : 263-266.
15. YOUNG (E.). Heartwater. In : DAVIS (J.W.), KARSTAD (L.H.), TRAINER (D.D.) Eds. Infectious diseases of wild mammals. 2nd ed. Ames, The Iowa State University Press, 1981. P. 405-406.