

U. Wernery<sup>1</sup>M. Ali<sup>1</sup>R. Wernery<sup>1</sup>H.S.H. Seifert<sup>2</sup>

## Severe heart muscle degeneration caused by *Clostridium perfringens* type A in camel calves (*Camelus dromedarius*)

WERNERY (U.), ALI (M.), WERNERY (R.), SEIFERT (H.S.H.). Dégénérescence sévère du muscle cardiaque provoquée par *Clostridium perfringens* de type A chez des jeunes dromadaires (*Camelus dromedarius*). *Revue Élev. Méd. vét. Pays trop.*, 1992, 45 (3-4) : 255-259

*Clostridium perfringens* de type A a été isolé dans différents organes et dans l'intestin de jeunes chameaux âgés de 3 à 5 semaines, morts de nécrose du muscle cardiaque. Aucun autre agent pathogène bactérien n'a été isolé. L'isolement de virus sur deux lignées cellulaires différentes, dont une culture de cellules cutanées fœtales de chameau, s'est également avéré négatif. Les souris ayant reçu des injections de filtrats dépourvus de bactéries préparés à partir de contenus intestinaux de jeunes chameaux autopsiés sont mortes après 1 à 6 h, révélant la présence de toxines clostridiennes. Nos résultats montrent que la nécrose du muscle cardiaque est provoquée par les toxines de *Clostridium perfringens* de type A. **Mots clés** : Dromadaire - Jeune animal - *Clostridium perfringens* - Analyse microbiologique - Cœur - Nécrose - Émirats arabes unis.

### INTRODUCTION

Clostridial organisms are potent producers of exotoxins upon which their pathogenicity depends. *Clostridium perfringens* toxins are usually absorbed from the intestines after abnormal proliferation of the organisms in the digestive tract. At least 20 different metabolic substances are produced by *C. perfringens* (1) and they possess a wide range of pathogenic effects on the target organs in the body.

Literature on *C. perfringens* infection in camels is scarce. IPATENKO (6) described enterotoxemias caused by *C. perfringens* types C and D in Mongolia and WERNERY *et al* (14) reported outbreaks of enterotoxemias caused by type A in the United Arab Emirates.

This paper describes *C. perfringens* type A infections in camels which died from severe heart muscle degeneration.

### MATERIALS AND METHODS

Outbreaks of *C. perfringens* infections were seen in two different breeding herds. The mothers and their camel calves were housed in pens. In the first herd, seven

camel calves aged 3-5 weeks died and in the second herd 11 camel calves died. The affected camel calves developed constipation for a few days and then a severe diarrhoea. Two days after the onset of the scours the calves died.

Postmortem examinations were performed in all calves. The necropsies were carried out between one to five hours after death. The heart was examined for histopathological lesions.

Fluid contents of the abomasum and duodenum were centrifuged at high speed for 20 min at 4 °C and the supernatant filtered (Sartorius membrane filter, 0.45 µm). The sterile filtrate was then infected into white mice intravenously (0.5-1.0 ml).

Pieces of organs (abomasum, small intestines, duodenum, liver, kidney, heart, mesenteric and prescapular lymph nodes were placed into test tubes containing hot (60 °C) Sahidi-Ferguson-Perfringens (SFP) agar and spread onto Zeissler agar containing antibiotic supplement (Oxoid, SR93). The plates were incubated under anaerobic conditions (Gas generating kit, Oxoid) at 37 °C for 24 h. When black colonies and gas production were observed in the SFP agar (the following day) the clostridial organisms were spread on Zeissler agar and incubated anaerobically. *C. perfringens* was identified by Gram stain (directly from organs and the media), by motility test and the appearance on Zeissler agar, which showed typical double zoned haemolysis around the colonies. The strains were then sent for further testing to the Institute for Applied Biotechnology in the Tropics in Goettingen, Germany. All strains were identified as *C. perfringens* type A by means of gas chromatography of metabolically produced short-chain fatty acids and alcohols as well as long-chain fatty acids as cell components.

Organ samples from necropsied camel calves were also tested for aerobic pathogens including *Salmonella* using known routine bacteriological methods.

Sections from tonsils and small intestines were tested for the presence of BVD/MD antigen (bovine virus diarrhoea/mucosal disease) using fluorescein conjugated antiserum\*.

1. Central Veterinary Research Laboratory, POB 597, Dubai, Émirats arabes unis.

2. Institute for Applied Biotechnology in the Tropics at the Georg-August University, Goettingen, Allemagne.

Reçu le 15.6.1992, accepté le 23.3.1993.

\* The authors thank Pr Dr LIESS, Veterinary School, Hannover, Germany for supplying the conjugate.

U. Wernery M. Ali R. Wernery H.S.H. Seifert

Pieces of heart, spleen, mesenteric and prescapular lymph nodes and small intestine were also used for the infection of two different cell cultures. In brief, 2 to 3 g of each tissue were homogenized with sterile sand in 5 ml Eagle's Minimum Essential Medium (MEM), the suspension clarified by centrifugation and the supernatant filtered through a disposable 0.45  $\mu\text{m}$  Millipore filter (Sartorius, Minisart NML). The filtrate was then inoculated onto confluent monolayers of Vero cells (African green monkey kidney) and foetal camel skin (7). The cells were checked every day for six days under an inverted microscope for any cytopathic effect (CPE).

## RESULTS

### Pathological lesions

All 18 camel calves which were necropsied showed very severe heart muscle lesions (photo 1), hydropericardium with fibrin separation, petechial haemorrhages under the pleura of the lung (photo 2) and dark kidneys. The adherent kidney capsule could only be removed with subsequent loss of renal parenchyma (photo 3). In the stomach compartments different quantities of sand were discovered. Histopathological sections from the heart showed an

extensive degree of cardiac muscle necrosis with lysis of nuclei and granular Z-band material. There was a remarkable absence of any inflammatory reaction (photo 4)\*.


\* The authors are indebted to Dr ADNAN AL ASHBALD, Dubai Hospital, for carrying out the histopathology.

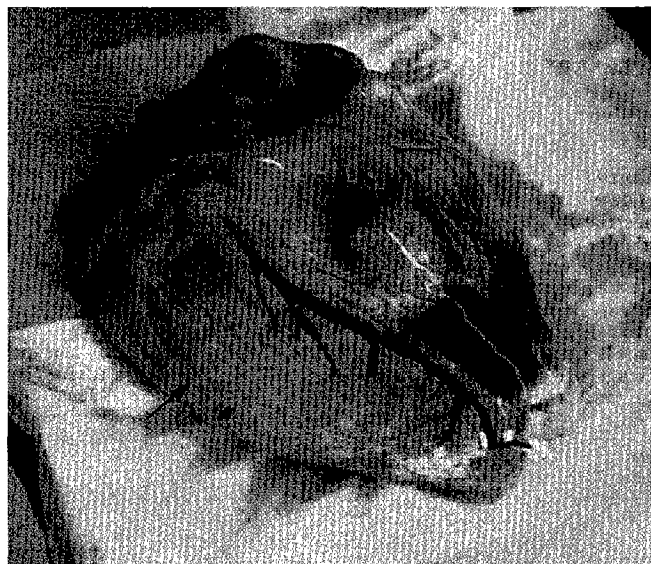
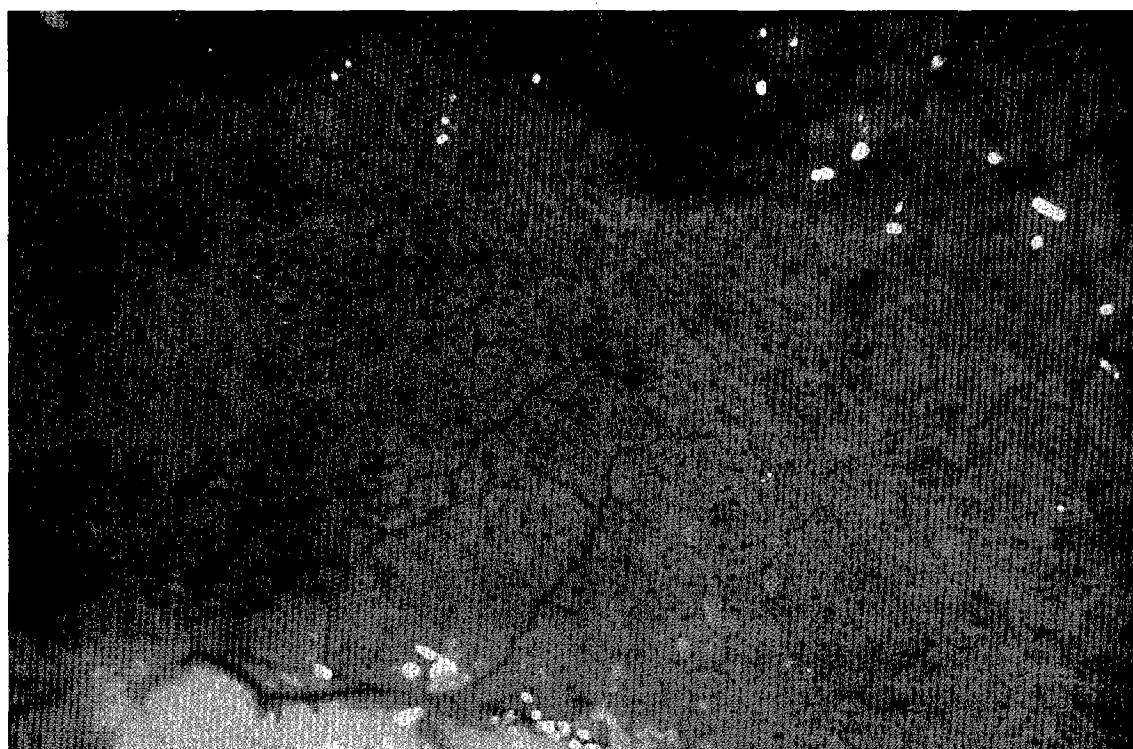
Photo 1 : Severe heart muscle necrosis in a four-week old camel calf suffering from *C. perfringens A enterotoxemia*.

Photo 2 : *C. perfringens A enterotoxemia* in a four-week old camel calf; petechial haemorrhages under the lung pleura.





*Photo 3 : Kidneys of a four-week old camel calf suffering from C. perfringens A enterotoxemia ; kidney capsules could only be removed with loss of parenchyma.*



*Photo 4 : Cardiac muscle necrosis with lysis of nuclei and granular Z-band material in a four week old camel calf.*

*C. perfringens*, type A was isolated from the abomasum, small intestine duodenum, mesenteric lymph nodes, liver and kidney but not from the heart and prescapular lymph nodes. *C. perfringens* rods were also observed in large numbers in direct smears of the intestinal tract with Gram stain. *E. coli* was isolated from the intestinal tract but no *Salmonellae* were cultivated.

Mice which were infected with bacteria-free filtrates prepared from intestinal contents of necropsied camel calves died after 1 to 6 h with the symptoms of opisthotonos. This demonstrated the presence of toxins, most probably clostridial toxins.

U. Wernery M. Ali R. Wernery H.S.H. Seifert

No virus was isolated on Vero cells and foetal camel skin cells and the fluorescence test for BVD/MD was always negative.

## DISCUSSION

Acute and subacute enterotoxemias as well as haemorrhagic enteritis caused by *C. perfringens*, types A, C and D have been described in camels by several scientists (3, 5, 6, 8, 14).

*C. perfringens* A is ubiquitous and is most common in the intestine of healthy animals (1). Infections caused by *C. perfringens* are soil-borne. The spores are resistant to destruction by environmental influences such as extreme drought or frost and they become incorporated into the soil structure (10), particularly where livestock has been kept for long periods and where the soil has become heavily contaminated. Breeding camels which are housed in paddocks in the desert, are in contact with spores and vegetative forms of *C. perfringens*. In contaminated soils more than  $10^5$  *C. perfringens* bacteria per gram were found (11). Despite regular removal of faeces from paddocks *C. perfringens* is continually ingested through food or water contaminated with soil from faeces of carrier animals, but under normal circumstances ingested *C. perfringens* organisms are kept at low numbers by inhibitory factors in the intestine (12). Clostridial enterotoxemias however, appear to be caused by predisposing factors which remain poorly understood (2).

Camel calves aged three to five weeks start to consume fodder in addition to their usual daily milk intake. Due to their enlightened curiosity they also begin to swallow different quantities of sand contaminated with *C. perfringens*. A total of  $10^4$  *C. perfringens* organisms per gram sand were isolated from paddocks where the camel calves had been kept with their mothers. Milk in the camel stomachs and intestines provides optimal conditions for the proliferation of *C. perfringens* (2). Furthermore, the digestive tract previously used only for milk intake suddenly faces different kinds of feedstuffs which not only changed the microbiological flora but also induces the enlargement of stomach compartments. This situation

might have predisposes to outbreaks of *C. perfringens* type A infections. During multiplication of *C. perfringens* organisms in the intestine, toxins were released. They apparently increases the permeability of the intestine, which in turn facilitates the absorption of more toxins (9). The same authors found that epsilon toxin was even activated by proteolytic digestive enzymes and then absorbed into the blood stream. It is unknown why the toxins choose the heart muscle as the primary target organ.

Another important factor in the development of clostridial infections is the serum protein level in young camels especially of the globuline fractions. All newborn farm animals are more susceptible to infection than their adult counterparts. The camel calf, bovine calf, lamb, piglet and foal are born without significant levels of gammaglobulins. They possess therefore almost no resistance to infections until after they have ingested colostrum and absorbed sufficient quantities of lactoglobulins. UNGARWARON *et al* (13), however, showed in newborn camel calves that there was a decline in concentration of IgG after the seventh day of life with its lowest level between 20-30 days. Similar findings were reported by FOWLER (4). He found that the globulin level was naturally low at birth ( $< 5.2$  mg/kg) in South American camelids, but it rises with the intake of colostrum to 5.5-6.2 mg/kg within four to five days. Since the young camel calf is not yet immunologically competent the globulin fraction begins to decrease and not sufficient immunoglobulins are produced. The lowest level of globulins occurs between two and three weeks of age in South American camelids which also corresponds to the age of highest death losses from type A enterotoxemias (4). A similar situation is seen in dromedary camel calves with heavy losses between three to five weeks of age.

## ACKNOWLEDGEMENTS

These studies were carried out with the support of H.H. Sh. Mohammad Bin Rashid Al MAKTOUM, Dubai, United Arab Emirates.

WERNERY (U.), ALI (M.), WERNERY (R.), SEIFERT (H.S.H.). Severe heart muscle degeneration caused by *Clostridium perfringens* type A in camel calves (*Camelus dromedarius*). *Revue Élev. Méd. vét. Pays trop.*, 1992, **45** (3-4) : 255-259

*Clostridium perfringens* type A was isolated from different organs and intestines from three to five weeks old camel calves which have died from heart muscle necrosis. No other bacterial pathogens were isolated. Virus isolation on two different cell lines including a fetal camel skin were also negative. Mice which were injected with bacteria free filtrates prepared from intestinal contents of necropsied camel calves died after one to six hours demonstrating the presence of clostridial toxins. Our findings suggest that the cardiac muscle necrosis is caused by *Clostridium perfringens* type A toxins. *Key words* : Dromedary - Camel calf - *Clostridium perfringens* - Microbiological analysis - Heart - Necrosis - United Arab Emirates.

WERNERY (U.), ALI (M.), WERNERY (R.), SEIFERT (H.S.H.). Degeneración severa del músculo cardíaco provocada por *Clostridium perfringens* tipo A en jóvenes camellos (*Camelus dromedarius*). *Revue Élev. Méd. vét. Pays trop.*, 1992, **45** (3-4) : 255-259

*Clostridium perfringens* tipo A fue aislado en intestinos y otros órganos de camellos de 3 a 5 semanas de edad, muertos por necrosis muscular cardíaca. Ningún otro agente patógeno fue aislado. Igualmente negativos fueron, los resultados de aislamientos virales, en dos líneas celulares diferentes (incluyendo piel fetal de camello). La inyección de ratones con filtrados libres de bacterias (provenientes de contenido intestinal obtenido durante la necropsia de los camellos), provocó la muerte en uno a seis horas, demostrando la presencia de toxinas clostridiales. Nuestros resultados sugieren que la necrosis del músculo cardíaco es provocada por toxinas de *C. perfringens* tipo A. *Palabras claves* : Dromedario - Joven animal - *Clostridium perfringens* - Analisis microbiológico - Corazón - Necrosis - Emiratos Arabes Unidos.

## REFERENCES

1. BISPING (W.), AMTSBERG (G.). Colour atlas for the diagnosis of bacterial pathogens in animals. Berlin, Hamburg, Verlag Paul Parey, 1988.
2. BLOOD (D.C.), RADOSTIS (D.M.). Veterinary medicine. 7th ed. London, Bailliere et Tindall, 1989.
3. CHAUHAN (R.S.), KULSHRESHTHA (R.C.), KAUSHIK (R.M.). A report of enterotoxaemia in camels in India. *Indian Vet. J.*, 1985, **62** (10) : 825-827.
4. FOWLER (M.E.). Medicine and surgery of South American camelids. Ames, Iowa State University Press, 1989.
5. GAMEEL (A.A.), EL SANOUSI (S.M.), MUSA (B.), EL OWNI (E.E.). Association of some pathogenic bacteria with haemorrhagic enteritis in camels. Camel research paper. Camel Research Unit University of Khartoum, Sudan. 1986. Pp. 50-55 (No SRC 12)
6. IPATENKO (J.G.). Abstract. *In* : Infectious enterotoxaemia of camels. *Vet. Bull.*, 1974, **44** (4) : 1481.
7. KAADEN (O.R.), KLOPRIES (M.), WERNERY (U.), DROMMET (W.). Establishment and characterization of a camel skin cell line. *In* : ALLEN (W.R.), HIGGINS (A.J.), MAYHEW (I.G.), SNOW (D.H.), WADE (J.F.). First international camel conference Proceedings, Dubai, 1992. P. 402.
8. MOEBUU, AYUURZANA, DASHDAVA, IPATENKO (N.G.). Infectious enterotoxaemia of camels in Mongolia caused by *C. perfringens* type C. *Veterinariya, Moscow*, 1966, **43** (11) : 32-35.
9. NILO (L.), RUTH (E.), MOFFATT, AVERY (R.J.). Bovine enterotoxaemia. II. Experimental reproduction of the disease. *Can. Vet. J.*, 1963, **4** (11) : 288-298.
10. SEIFERT (H.S.H.). Hygiene management on extensive and intensive cattle units in the tropics. *Anim. Res. Dev.*, 1978, **7** (4) : 49-102.
11. SEIFERT (H.S.H.). Tropentierhygiene. Jena, Verlag Gustav Fischer. 1992.
12. SINKOVICS (G.). Quantitative changes of Clostridia in the intestine of early weaned pigs diseased in Coli-enterotoxaemia. *Acta Vet. Hung.*, 1972, **22** (2) : 133-139.
13. UNGAR-WARON (H.), ELIAS (E.), GLUCKMAN (A.), TRAININ (Z.). Dromedary IgG : purification, characterization and quantitation in sera of dams and newborns. *Isr. J. Vet. Med.*, 1987, **43** (3) : 198-203.
14. WERNERY (U.), SEIFERT (H.S.H.), BILLAH (A.M.), ALI (M.). Predisposing factors in enterotoxemias of camels (*Camelus dromedarius*) caused by *Clostridium perfringens* type A. *Revue Élev. Méd. vét. Pays trop.*, 1991, **44** (2) : 147-152.