

A.M.A. Ali¹S.M. El-Sanousi¹M.A. Al-EknaH¹A.A. Gameel¹E.A. Dafalla¹A.M. Homeida¹Y.M. Radwan¹

Studies on the infundibular cysts of the uterine tube in camel (*Camelus dromedarius*)

ALI (A.M.A.), EL-SANOUSI (S.M.), AL-EKNAH (M.A.), GAMEEL (A.A.), DAFALLA (E.A.), HOMEIDA (A.M.), RADWAN (Y.M.). Étude de kystes infundibulaires de l'appareil génital de la chamelle (*Camelus dromedarius*). *Revue Elev. Méd. vét. Pays trop.* 1992, 45 (3-4) : 243-253

Deux cent dix-huit appareils génitaux de chammelles ont été examinés après prélèvement à l'abattoir. Des kystes infundibulaires ont été trouvés dans 16 p. 100 des cas (35) ; ces kystes étaient unilatéraux dans 22 cas et bilatéraux dans 13 autres. Tous contenaient un liquide de consistance variable. Leurs structures morphologique et histologique ont été décrites. La recherche bactériologique et l'analyse physicochimique de leur contenu a été réalisée. *Aeromonas hydrophila* a été isolé dans 68,5 p. 100 des cas. En matière de diagnostic, les auteurs ont comparé les résultats de la palpation rectale avec ceux de la technique des ultra-sons. *Mots clés* : Chamelle - *Camelus dromedarius* - Kyste - Système génital femelle - Pathologie - *Aeromonas hydrophila* - Arabie Saoudite.

INTRODUCTION

Saudi Arabia is considered to have the fourth highest camel population in the Arabian world, with an estimated population of one million. Camels play a very important role in Saudi culture. At present, modern methods of camel production have been developed. As regards the dromedary camel, the morphology of its genitalia has been studied (1, 2, 32, 33). However, the presence of a cyst enclosed into the infundibulum of the camel's uterine tube has not been mentioned. Only little information is available on the incidence of *Aeromonas hydrophila* in mammals, except in man (19). However, ANNAPURNA and SANYAL (3) isolated the organism from faeces of some domestic animals : cow, buffalo, goat and chickens.

The only single report in the literature concerning the isolation of *A. hydrophila* from camels is that of GAMEEL *et al* (18). The organism was isolated in association with *Clostridium perfringens* type A and *Clostridium sordellii*, the properties of which were studied by EL-SANOUSI *et al* (15).

DE and CHATTERJE (11) found that the exotoxin of *A. hydrophila* caused fluid accumulation in ligated rabbit ileal loops. ASAO *et al* (6) found it to cause fluid accumulation in infant mouse intestine.

The present study describes the morphological, histopathological, physicochemical and bacteriological features of infundibular cysts observed in female camels. In addition, the ultrasound scanner coupled with rectal palpation was used to detect such infundibular cysts antemortem.

MATERIALS AND METHODS

Collection of specimens

Two hundred eighteen genital tracts of female camels (*Camelus dromedarius*) were collected from abattoirs of Al-Asha (eastern province of Saudi Arabia) and Riyadh cities between September, 1989 to February, 1990. Out of these, genital tracts showing cyst-like formations were recorded and thoroughly examined. The estimated age of the camels ranged between 10-18 years. The morphological features of the cysts were studied and recorded. The specimens were collected within 30 min from slaughtering of animals, kept on ice and immediately transferred to the laboratory. These specimens were stored at 0 °C overnight. Next morning they were thawed and treated further for bacteriological examination.

Gynaecological investigation

Seventeen female camels were randomly selected from animals brought to Al-Ahsa abattoir. After routine preparation of the camels for rectal examination, different parts of the reproductive tract were palpated rectally. When an infundibular cyst was suspected due to unusual position of the ovary, with empty horns, the ultrasound probe scanner (WIC 50, with 5mHz scan head, USA*) was introduced rectally and guided by the operator's hand. The probe was initially placed over the uterine body, horns and later the oviduct and ovarian region. The probe was then introduced cranially into the abdominal cavity and moved toward the left and right. After slaughter, the genitalia of the same animals examined were collected and inspected, and the findings of antemortem and post mortem examinations were compared.

1. Camel Research Centre, College of Veterinary Medicine and Animal Resources, King Faisal University, POB 1757, Al-Ahsa 31982, Saudi Arabia.

Reçu le 15.10.1990, accepté le 18.9.1992.

* Wesmed Veterinary Ultrasound, 78500 68th Avenue NE, Box 3001, Bothell, WA 98041-3001.

Bacteriological investigations

The surfaces of 30 cysts were carefully cleaned using 70 % alcohol and allowed to dry. The surface was seared using a red hot spatula. Disposable 10 ml plastic syringes were used to withdraw 10 ml of the fluid content aseptically. A few drops were plated directly onto 10 % sheep blood agar, MacConkey's agar and into alkaline peptone water (APW) and heart infusion broth (HIB) (31). The rest of the samples were transferred to sterile centrifuge bottles and centrifuged at 5,000 rpm for 15 min at 4 °C. The supernatant was decanted and the deposits cultured in similar media as mentioned above. At the beginning of the study, incubation was carried out aerobically at 37 °C for 24 h, later incubation was carried out at 30 °C for 24 h. When growth was obtained only in APW and HIB, subcultures were made on solid media. Plates showing no growth were reincubated for 7 days before they were regarded as negative.

The isolates were identified according to COWAN (9), CARTER (8) and KRIEG and HOLT (23). Sensitivity tests were performed with Oxoid discs. The toxin was prepared from HIB. The medium used was incubated in a water bath for 10 h with vigorous shaking.

Assay of the haemolytic activity

The haemolytic activity was detected in 2 % rabbit erythrocytes according to CUMBERBATCH (10).

Enterotoxin assay

- Rabbit loop test : enterotoxigenicity of isolates was assayed in ligated rabbit ileal loop according to DE and CHATTERJE (11) using cell-free toxin, cystic fluid and PPS as controls. The rabbits were euthanized 10 h post-operation and the fluids collected and measured.

- Infant mouse test : the test was conducted and evaluated according to DEAN (12) and ASAO *et al* (6).

- Assay of cytotoxic activity on Vero cells : the method of DONTA and HADDOW (13) was used.

Pathogenicity for mice

To inoculate five mice intravenously as well as five mice intraperitoneally, 0.3 ml of an 18-h whole culture of the isolates was used. Deaths were recorded and post-mortem examination performed.

Delayed permeability factor (DPF) in rabbit skin

The technique of JIWA (21) was used. Only one strain of *A. hydrophila* was tried.

Physicochemical investigation

The fluid collected from cysts was tested for their total protein content using the Biuret method. Activities of aspartate amino-transferase (AIAT) and alanine amino-transferase (ASAT) were determined colorometrically (30). The glucose content was estimated by the method of DUBOWSKI (14).

Histopathological investigations

Samples for histopathology were taken 30 minutes after slaughter from different parts of the wall of the cyst, infundibulum and cranial part of the uterine tube. Tissues were fixed in Bouin's fluid as well as in 10 % formalin, processed in paraffin and sections were stained with haematoxylin and eosin and Van Gieson's stain. Three to five rounded to oval bodies were observed only in fluid content of four cases of the studied infundibular cysts. They were fixed in 10 % formalin and their structures were studied.

RESULTS

Morphological descriptions

Out of the 218 female camel genital tracts examined, 183 (83.9 %) showed no gross abnormalities and were considered as normal. The normal uterine tube followed a tortuous course to the uterine horn and was enclosed in a peritoneal fold (the mesosalpinx) which arises from the lateral surface of the mesovarian. The length of the tube ranged between 22.5 and 30 cm. The ovarian end formed a funnel-shaped infundibulum 7-10 cm in width. The latter had a longitudinally folded mucous membrane which converged towards the abdominal opening of the tube and its free margin was indented to form the fimbriae. The ampullary region was soft and flabby, with a relatively wider lumen while the isthmus was less tortuous and hard with comparatively narrower lumen. The ovarian bursae were found to be formed between the mesosalpinx laterally and the proper ligament of the ovary, mesovarium and ovary medially. The ovary was situated within the ovarian bursa.

In most cases with cysts, the ovarian bursa had a depth of 5-12 cm. In ten cases it was crossed with fibrous tissues. Thirty five (16 %) were found to have either unilateral or bilateral cysts which appeared to be cranial dilations of the infundibulum. These were designated "infundibular cysts". They extended to the abdominal cavity, cranial to the pelvic region between the loops of intestines. The incidence and site of the cysts in the animals examined are shown in table I. In unilateral cases, 9 cysts

TABLE I The number and distribution of the infundibular cysts in female camels.

Area	Number of slaughtered female camels	Number and percentage of infundibular cysts		
		Total	Unilateral	Bilateral
Al-Ahsa	179	30 (16.8 %)	19 (10.6 %)	11 (6.1 %)
Al-Riyadh	39	5 (12.8 %)	3 (7.7 %)	2 (5.1 %)
Total number and percentage	218	35 (16 %)	22 (10.1 %)	13 (6 %)

(4.1 %) were found on the right side and 12 (5.5 %) on the left side. The infundibular cysts had different sizes, shapes and fluid consistencies. They were oval, round or kidney shaped and their walls were thin and membranous (photos 1-8) except one which had a very thick wall (photo 9). The cysts measured 18-50 cm in length and 10-28 cm in width. The content was fluid and had different colours (clear, yellowish, light or dark brown). The amount of fluid collected from each cyst ranged between 300 and 3,800 ml. In five cases some of the fluid retracted back to the cranial third of the uterine tube.

Gynaecological investigations

On rectal palpation, the reproductive tracts of 15 non-pregnant camels were easily retracted to the pelvic cavity. In one female the left ovary was not palpable and was pulled down by something which could not be reached by the operator's hand. When the probe of the ultra-sound scanner was introduced deep into the abdominal cavity, a dark area showed up on the screen (see photo 13). This was not confused with follicular cysts, whereas in another female a tennis ball-like cyst was palpated on the right side (see photo 14). The presence of the infundibular and follicular cysts was confirmed later. At post-mortem examination the former was found to be an infundibular cyst, whereas the latter was as a follicular cyst.

Bacteriological findings

Twenty four out of 30 cyst-fluids (80 %) gave pure growth of a single type of colonies. The colonies were greyish white, translucent, moist, circular and flat with either α or β -haemolysis. The sizes of colonies increased through further incubation at room temperature, reaching 6 mm in diameter. The colonies turned into light green with age. The organisms were identified as *Aeromonas hydrophila* according to their biochemical properties (table II).

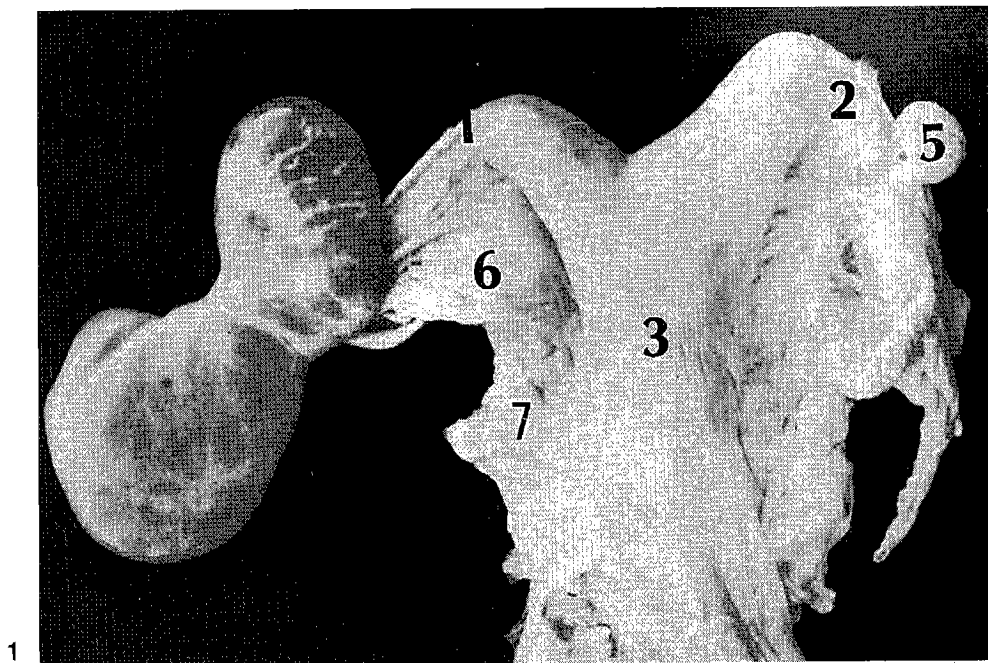
The strains of *A. hydrophila* tested were found to be sensitive to the following antibiotics : oxytetracycline (30 mcg), chlortetracycline (30 mcg), kanamycin (30 μ g), chloramphenicol (30 μ g), nalidixic acid (30 μ g), erythromycin

TABLE II The biochemical properties of 24 strains of *A. hydrophila* isolated from uterine infundibulum cysts of she-camel.

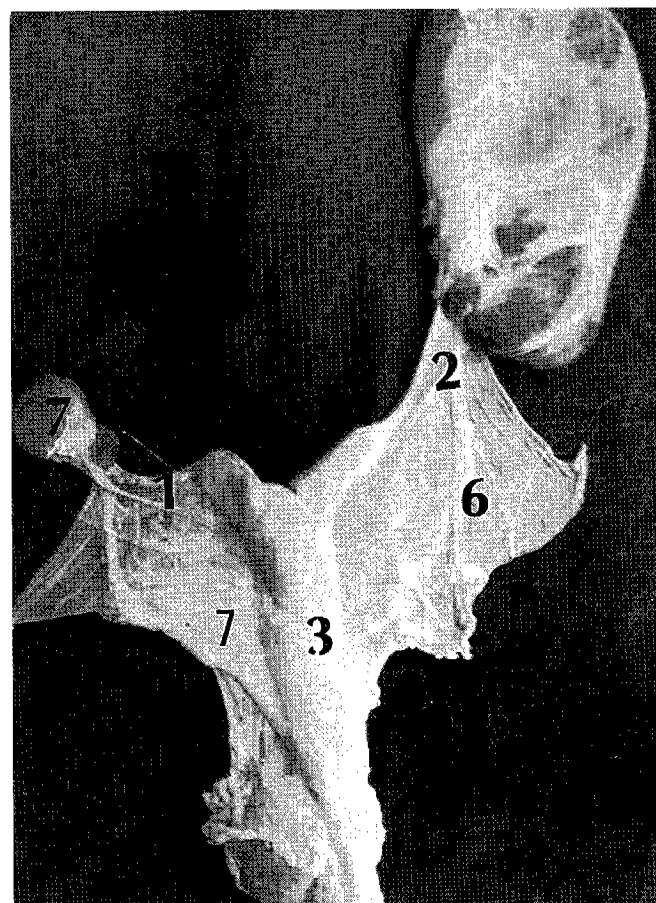
Tests	<i>Aeromonas</i>	
	<i>hydrophila</i> (A) 18	<i>hydrophila</i> (B) 6
Motility	18	6
Catalase	18	6
Oxidase	18	6
Glucose (acid)	18	6
Glucose (gas)	18	6
Growth on MacConkeys agar	18	6
Arabinose	13	4
Sucrose	18	5
Lactose	0	0
Mannitol	17 (G)	5
Salicin	2	4
Arabinose utilization	10	0
Arginine and lysine utilization	15	6
Histidine utilization	18	6 (4)
TSI (H ₂ S)	6	1
H ₂ S in P.W. with cysteine HCl	18	6
Citrate	18	0
Indole	18	6
KCN	12	1
MR	1	6
VP	18	0
Lysine	0	0
Ornithine	1	0
Arginine	18	6
Esculin hydrolysis	13	3

A = *Aeromonas hydrophila* with α -haemolysis ; B = *Aeromonas hydrophila* with β -haemolysis.

Arabic numbers indicate positive results ;
() indicate late results ; G : gas.

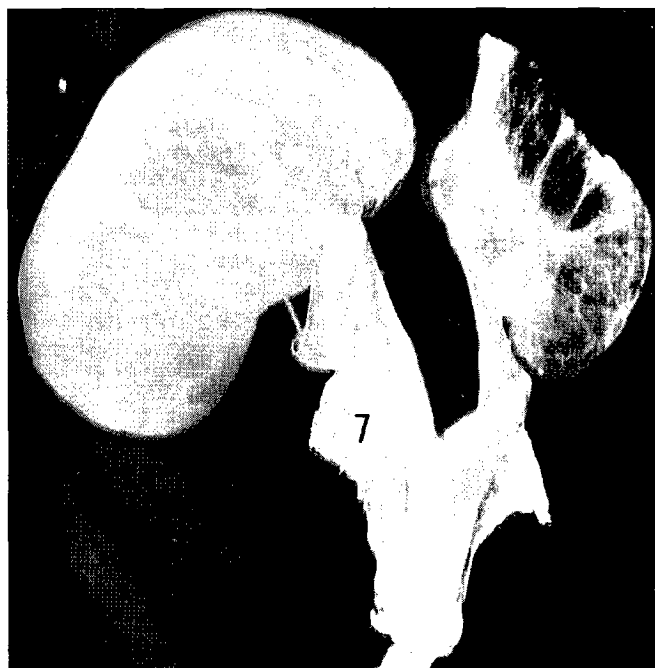


1



2

Photo 1, 2 : Female genital tract with unilateral cysts ; 1, left uterine tube ; 2, mesosalpinx ; 3, body of the uterus , 5, right uterine horn ; 6, right ovary ; 7, broad ligament.



3
Photo 3. 4 : Female camel genital tract with bilateral infundibular cysts.

(30 µg), gentamycin (10 µg), tetracycline (30 µg), cevacler (30 µg). They were partially sensitive to neomycin but resistant to polymixin B (300 units), trisulpha (300 mcg), ampicillin (10 µg), streptomycin (10 mcg), rifampicin (5 mcg), clindamycin (2 µg), cloxacillin (1 µg), nystatin (100 units), penicillin (10 i.u.), methicillin (5 µg), lincomycin (10 µg), vancomycin (30 mcg) and fucidicacid (10 µg).

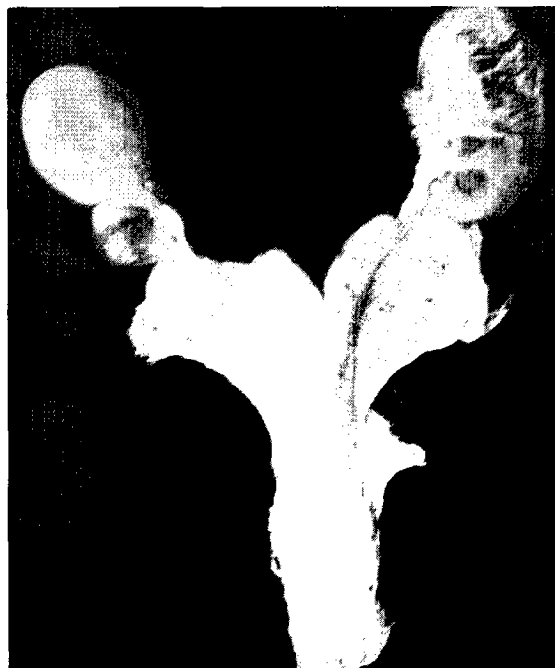
A representative strain from *A. hydrophila* group (A) gave a haemolytic unit of 1024 while that from group (B) gave only 64 units.

Enterotoxin assay

The results of rabbit ileal loop and infant mouse test are presented in table III.

Delayed permeability factor (DPF) in rabbit skin

Blueing was observed after six hours post inoculation (2 cm in diameter). Induration appeared after 12 h (3.2 cm in diameter) followed by necrosis and sloughing of the skin.



4

TABLE III Fluid accumulation in the rabbit ileal loop and infant mouse tests.

	Rabbit ileal loop (ml of fluid/cm intestinal loop*)	Infant mouse test weight of intestine/remaining body weight**
Control	0.28	0.09
<i>A. hydrophila</i> (A)	1.30	0.11
<i>A. hydrophila</i> (B)	1.10	0.10
Fluid from cyst	0.70	0.11

* 1. positive ; ** > 0.09. positive.
A : *A. hydrophila* α haemolytic ; B : *A. hydrophila* β haemolytic.

Pathogenicity for mice

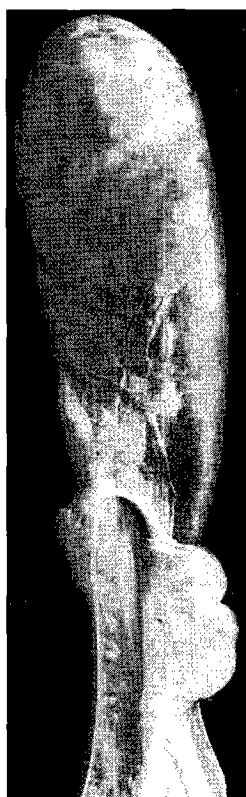
Deaths occurred between 18-24 h with signs of septicaemia. Blindness was observed in mice inoculated intravenously.

Assay for toxicity in Vero cells

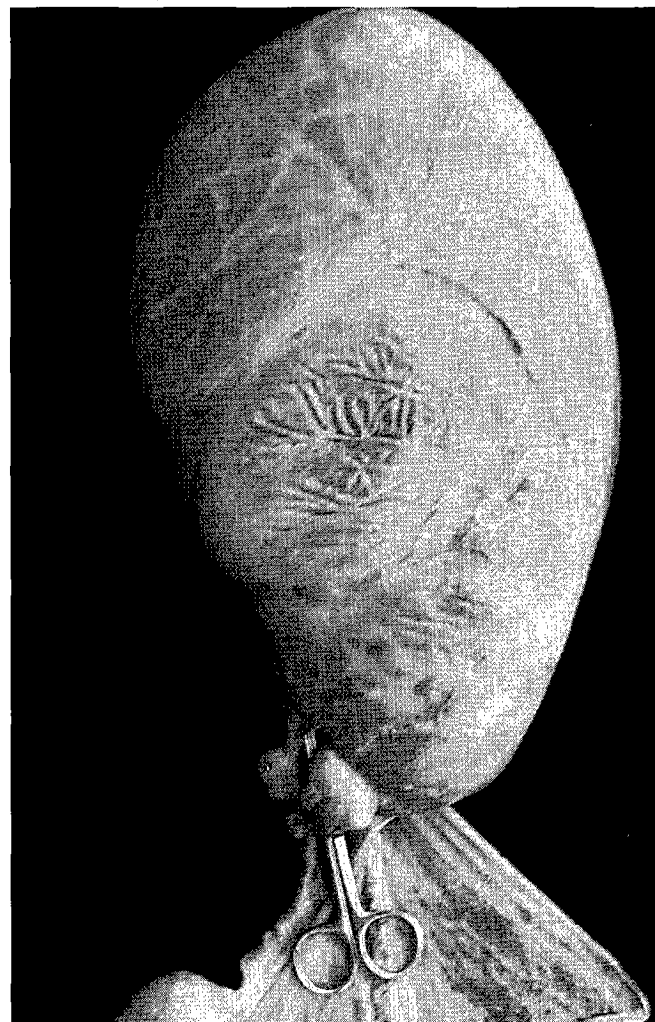
Loss of adherence and rounding were the common features in the cells tested.



5



6



7

Photo 5, 6, 7 : Various forms of infundibular cysts, elliptical, oval and kidney shaped.

Histology

The cyst wall, examined at different places was composed mainly of fibrous connective tissue and smooth muscle and lined at one side by low columnar epithelium. The latter had a vacuolated appearance and an apparently striated border with surface globules. In close association with the epithelium was a homogenous pink area which represented the cyst contents (photo 10). At the level of the infundibulum the cyst wall was either composed of fibrous connective tissue or smooth muscle (photo 10). The lining columnar epithelium had a similar striated border and bleb-like luminal projections. It was thrown into folds which were cut out at places into acinar-like structures containing pinkish material (photo 11). The mucosa of the cranial part of the uterine tube (ampula) was distinctly folded and formed cyst-like structures lined by similar columnar epithelium with centrally placed nuclei. The contents of the cysts showed many free pinkish globules. The subepithelial layer was infiltrated by

monocular cells of predominantly lymphocytes. The inner circular and outer longitudinal smooth muscle layers of the tunica muscularis were separated by loose connective tissue containing thick walled blood vessels. Some of the bodies found within the content of the infundibular cyst had fibrous wall and the others were lined with low columnar epithelium (photo 12). The wall of these bodies enclosed within it, was a homogenous eosinophilic material containing aggregates of bacilli.

Physicochemical findings

The infundibular cyst fluid had a specific gravity of 1.15 and a pH of 8.87. The protein content was 7.2 g/dl while the glucose level was 35 mg/dl. The AIAT and ASAT values were 51 and 2.8 μ /ml, respectively.

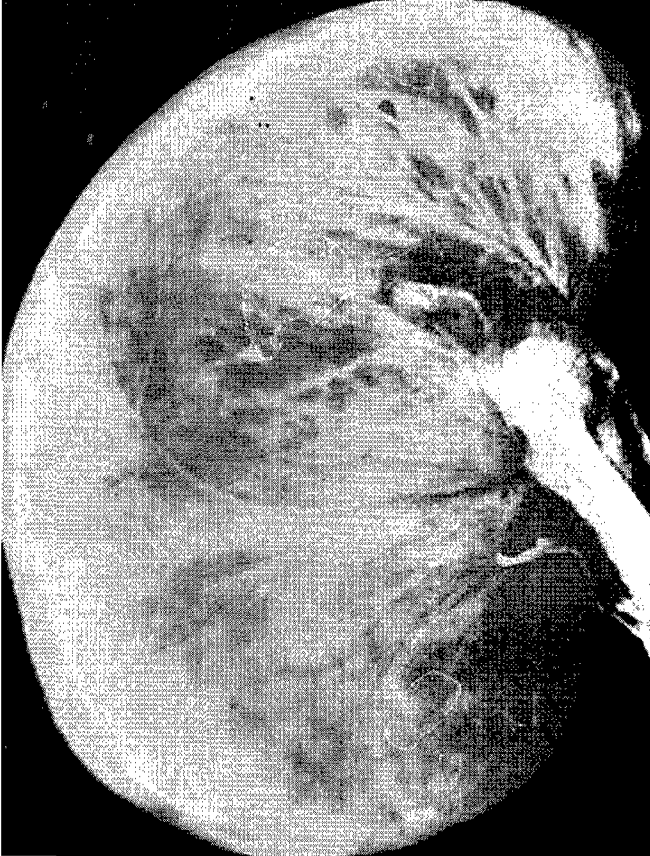


Photo 8 : Membraneous kidney-shaped infundibular cyst.

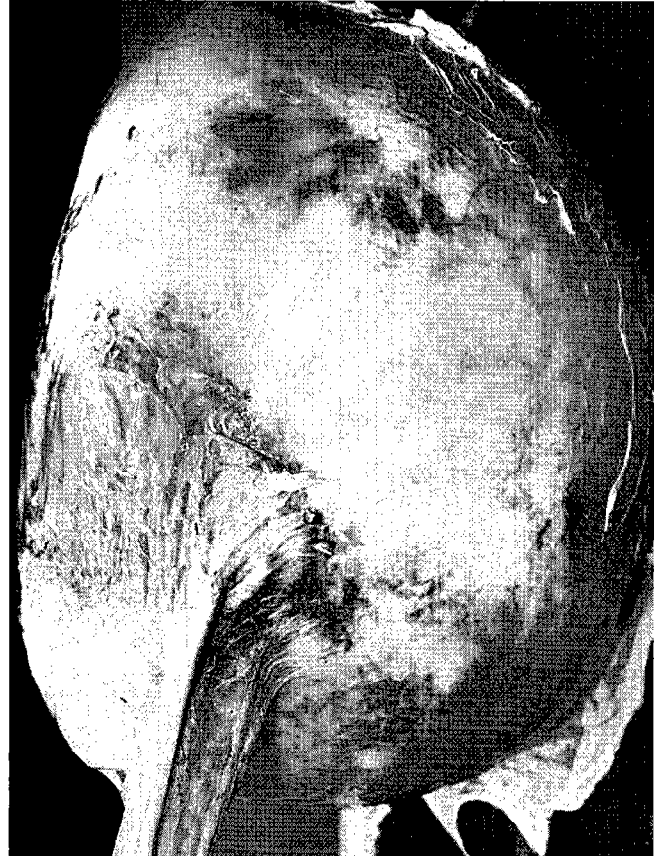


Photo 9 : Rounded thick walled cyst.

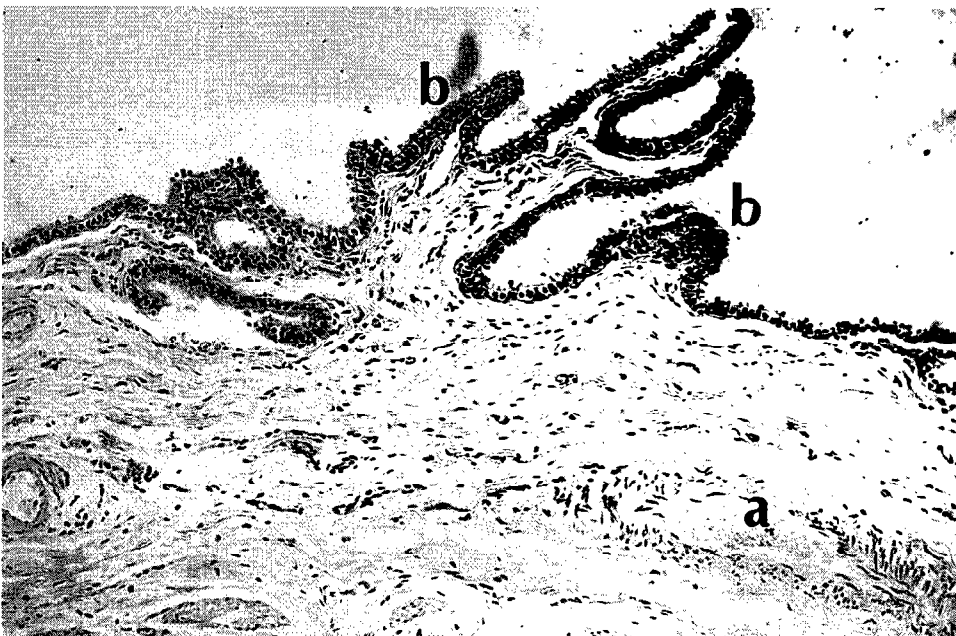


Photo 10 : Cyst wall composed of fibrous connective tissue and smooth muscles and lined by low columnar epithelium with vacuolated cytoplasm. Note thick walled blood vessels (a) and epithelial folds (b) (HE x 104).

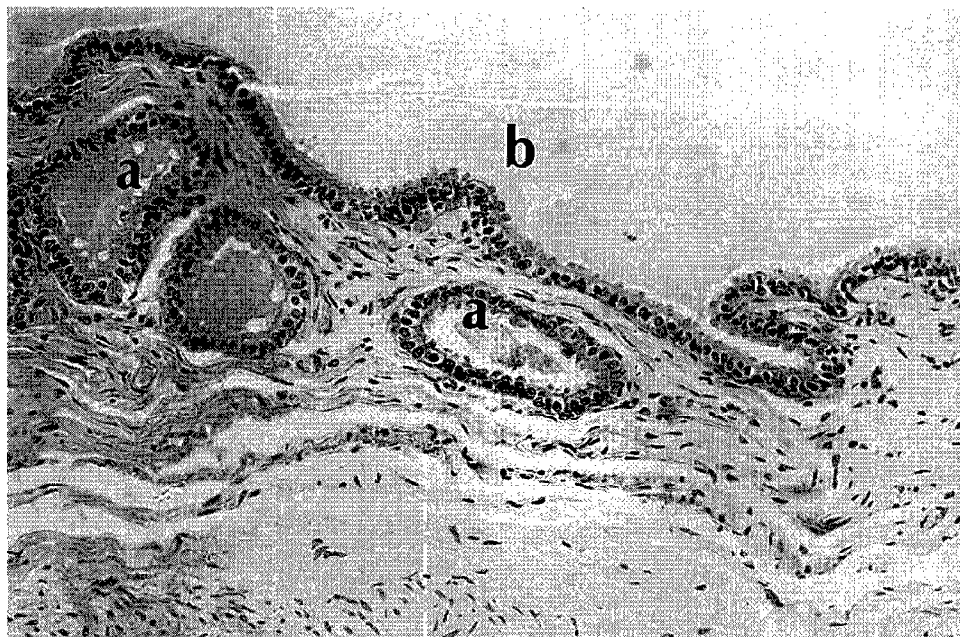


Photo 11 : Cyst wall lined by low columnar epithelium showing luminal globules. Note subepithelial acinar structures (a) and cysts contents (b) (HE x 162.5).

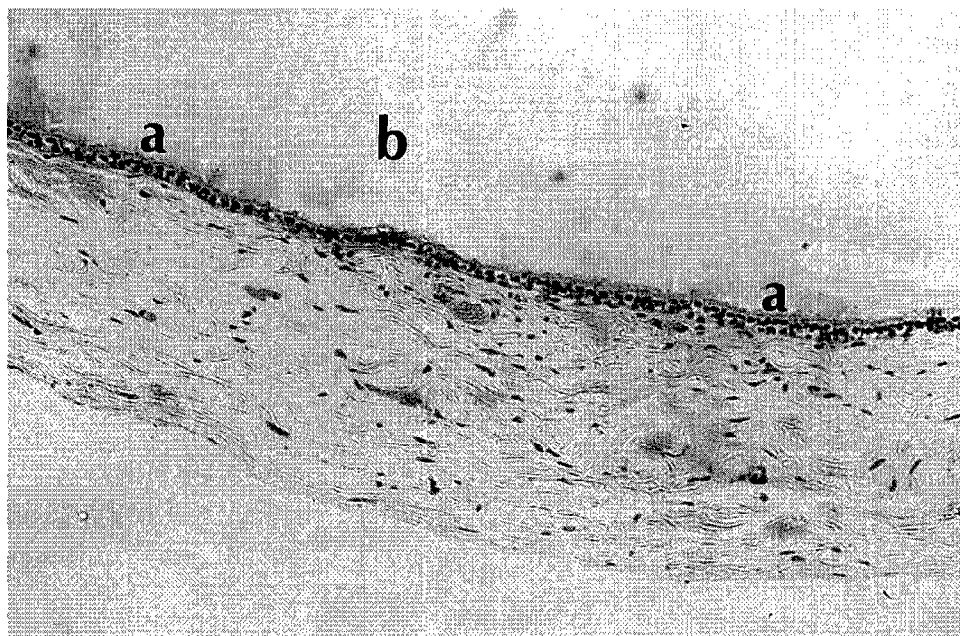


Photo 12 : Cyst wall lined by low columnar epithelium and composed of fibrous connective tissue containing many blood capillaries. Note dark nuclei and vacuolated cytoplasm cells (a) and homogenous cyst contents (b) (HE x 104).

DISCUSSION

The described histological and morphological structures of the cysts prove that they were dilatations of the cranial part of the infundibular wall, hence designated as "infundibular cysts". The prevalence of such cysts was fairly high in the camels examined and coincided with the increased incidence of infertility observed in camels brought to the

Veterinary Teaching Hospital in Saudi Arabia (4). Concerning abnormalities of the female genital tract, specially those of the urogenital ducts and other paraovarian cysts of the domestic animals (24, 29), there was no mention of similar cyst formation.

The ultrasound scanner applied to detect infundibular cyst(s) in the living animals paves the way for future screening of female camels. The ultrasound technique proved thus to be helpful in the detection of ovarian cysts in

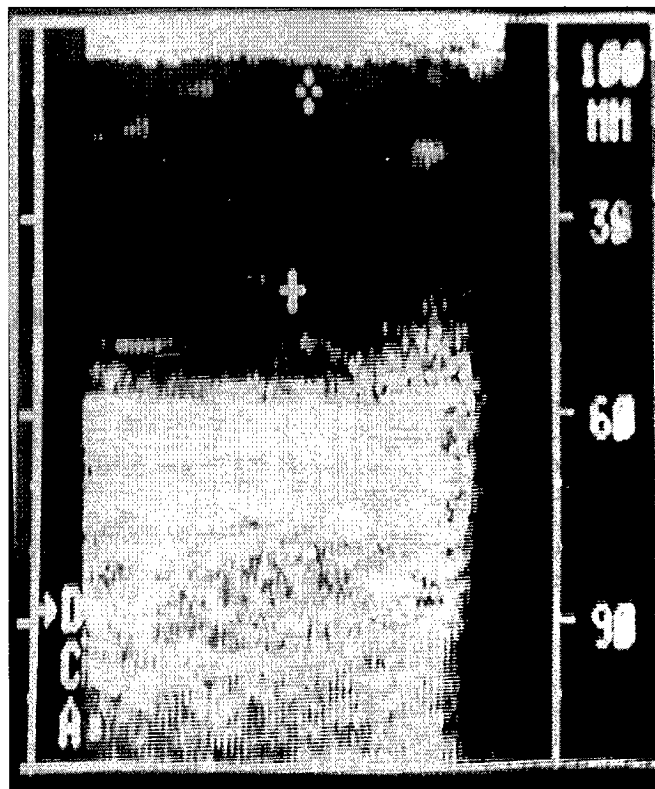


Photo 13 : A photomicrograph of an infundibular cyst detected by the ultrasound scanner.

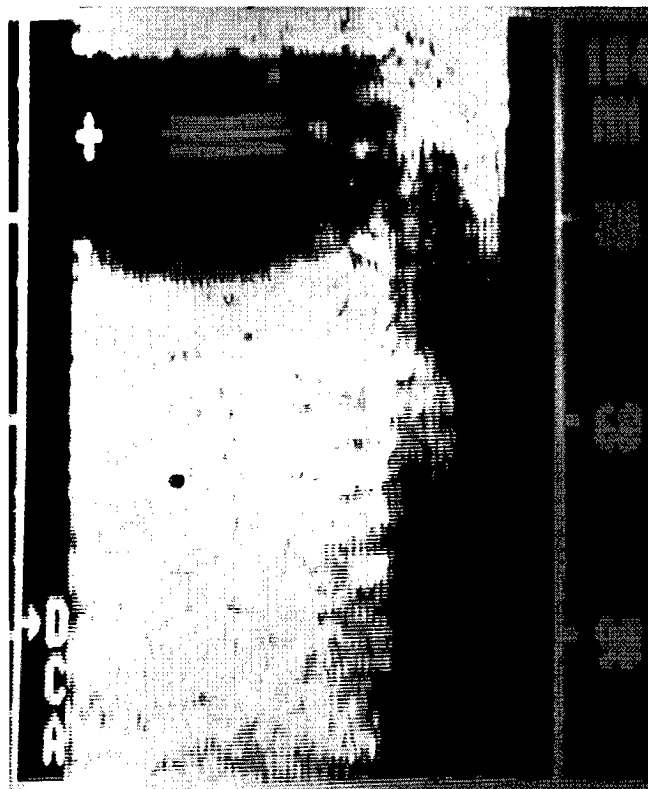

Photo 14 : A photomicrograph of a follicular cyst detected by the ultrasound scanner.

female camels (25, 26). The long gestation period and the short breeding season in the dromedary camel impose restrictions concerning the maximum fertility rate. In addition, the high rate of eggs and the early embryonic mortality require further limitations (27, 28, 35). The results of the present investigation add a new factor which can affect pregnancy and fertility rates. The morphological findings of the infundibular cyst clearly showed that the passage of the ovum to the site of fertilization in the uterine tube is prevented especially in bilateral cases where the two entrances to the abdominal opening of the tube are occluded. However, the possibility of pregnancy in unilateral cases cannot be excluded. Most of the ovaries in the unaffected side showed signs of follicular activity and pregnancy may occur, though infection with *A. hydrophila* may lead to abortion. Moreover, pregnancy is considered as a stress factor in general (36) and this in turn is predisposing to *A. hydrophila* infection, the latter acting as a secondary invader according to various workers (19, 36).

In general, fertility rates have been reported to be poor in *Camelus dromedarius* in studies conducted in Tunisia and Kenya (7, 16). In contrast to that, ARTHUR *et al* (5) considered the fertility to be high in Saudi Arabia, a finding which is not substantiated by the present study taking into consideration the rate of infection with *A.*

hydrophila (68 %). This coupled with other factors, that contribute normally to infertility, might boost the percentage upwards. Consequently, this will be an obstacle in camel reproduction in Saudi Arabia.

Species of the genus *Aeromonas* have long been recognized as pathogen in amphibians (7) and fish (20) and have been found to be widely distributed in the aquatic environment (22). Apart from scarce reports in the literature, *A. hydrophila* is associated mainly with enteric infections. The present report is considered as the second one concerning its isolation from the camel (18) and the first record of its isolation from the genital tract. The isolation of *A. hydrophila* from 68.6 % of infundibular cysts suggests its role in the formation of such cysts, although other unknown factors should not be completely excluded. The amounts of fluid accumulated in the cysts are due to the toxins released by *A. hydrophila*. Such toxins have been proved to cause accumulation of fluids by various authors (6, 34). Such findings were substantiated by the present study using ligated rabbit ileal loops and intestines of infant mice. As far as the lesions are concerned, the organisms isolated may be of low virulence, causing in most cases fluid accumulation rather than eliciting marked inflammatory reactions.

The mode of infection is difficult to determine with great certainty, however, ascending infection might be possible since *A. hydrophila* was found by various authors in faeces of normal animals. On the other hand, the prevalence of *A. hydrophila* in cattle is greater than in other animals (19).

Improvement of the bacteriological techniques, *i.e.* centrifugation of the cyst fluids and enrichment prior to plating on solid media made it possible to isolate *A. hydrophila* routinely from such cysts. It is thus worth trying to study the prevalence of *A. hydrophila* in the intestines of apparently healthy camels as well as in their environments.

CONCLUSION

The present investigation revealed that the cyst described in the female camel was designed as "infundibular cyst" which is a dilation of the cranial part of the infundibular

wall of the uterine tubes. The results add a new factor which can affect pregnancy and fertility rates in camels. The isolation of the *A. hydrophila* from the infundibular cyst might suggest its role in the formulation of such a cyst. Among other factors involved in the cyst formation, the role of the *A. hydrophila* needs further studies.

ACKNOWLEDGEMENTS

The authors are indebted to the staff members of Al-Asha and Riyadh abattoirs for their sincere cooperation. We would like to acknowledge the help of Dr. E.M.E. ABU ELZEIN for conducting toxicity in Vero cells. The technical assistance of A. ABDELBAQI and A. HUSSEIN is highly appreciated. Sincere thanks to Mr. M.A. AL-TINAY for photographing the specimens and Mr. AYAZ AHMAED for typing the manuscript.

ALI (A.M.A.), EL-SANOUSI (S.M.), AL-EKNAH (M.A.), GAMEEL (A.A.), DAFALLA (E.A.), HOMEIDA (A.M.), RADWAN (Y.M.). Studies on the infundibular cysts of the uterine tube in camel (*Camelus dromedarius*). *Revue Elev. Méd. vét. Pays trop.*, 1992, **45** (3-4) : 243-253

Two hundred eighteen genital tracts of slaughtered female camels were collected and examined. Infundibular cysts were observed in 35 tracts (16 %) ; these were either unilateral (22 cases) or bilateral (13 cases) all containing fluids of different consistencies. The morphological and histological structures of the cysts were recorded. The bacteriological investigation and physicochemical analysis of cyst contents were carried out. *Aeromonas hydrophila* was isolated from 68.5 % of cases. Rectal palpation and ultrasound technique were compared for the diagnosis of the cysts *antemortem*. *Key words* : Female camel - *Camelus dromedarius* - Cyst - Female genital system - Pathology - *Aeromonas hydrophila* - Saudi Arabia.

ALI (A.M.A.), EL-SANOUSI (S.M.), AL-EKNAH (M.A.), GAMEEL (A.A.), DAFALLA (E.A.), HOMEIDA (A.M.), RADWAN (Y.M.). Estudio sobre los quistes infundibulares del tubo uterino del dromedario (*Camelus dromedarius*). *Revue Elev. Méd. vét. Pays trop.*, 1992, **45** (3-4) : 243-253

Se examinaron doscientos dieciocho tractos genitales de hembras camello, los cuáles fueron colectados en el matadero. Treinta y cinco (16 p. 100) de estos tractos presentaban quistes infundibulares, unilaterales (22 casos) o bilaterales (13 casos), todos con un contenido líquido de consistencia variable. Se anotó la estructura morfológica y histológica del quiste. También se realizaron análisis bacteriológicos y físico-químicos del contenido quístico. *Aeromonas hydrophila* fue aislada en 68,5 p. 100 de los casos. Para el diagnóstico de los quistes *ante-mortem*, se comparó la palpación rectal con el ultrasonido. *Palabras claves* : Dromedario - *Camelus dromedarius* - Quiste - Tracto genital - Patología - *Aeromonas hydrophila* - Arabia Saudita.

REFERENCES

1. ABDALLA (O.). Anatomical studies of the female genital tract of one-humped camel (*Camelus dromedarius*). *Sudan J. vet. Sci. Anim. Husband.*, 1965, **6** : 41-47.
2. ABDALLA (O.). Anatomical studies of the female genital tract of the one-humped camel. I. Ovaries. *Sudan J. vet. Sci. Anim. Husband.*, 1967, **8** : 67-71.
3. ANNAPURNA (E.), SANYAL (S.C.). Enterotoxicity of *Aeromonas hydrophila*. *J. med. Microbiol.*, 1977, **10** : 317-323.
4. Annual report. Veterinary Teaching Hospital, Saudi Arabia, 1989.
5. ARTHUR (G.H.), ABDEL RAHIM (A.T.). The camel in health and disease. VII. Reproduction and genital diseases of the camel. *Br. Vet. J.*, 1985, **141** : 650-659.
6. ASAO (T.A.), KINOSHITA (Y.), KOZAKI (S.), UEMURA (T.), SAKAGUCHI (G.). Purification and some properties of *Aeromonas hydrophila* haemolysin. *Infec. Immun.*, 1984, **46** (1) : 122-127.
7. BURGEMEISTER (R.). Probleme der Dromedarhaltung und zucht in Südtunesien. Thesis. Giessen, West Germany, Justus Liebig University, 1974.

8. CARTER (G.R.). Diagnostic procedures in veterinary bacteriology and mycology. 4th ed. Springfield, Illinois, USA, Charles C. Thomas Publisher, 1984.
9. COWAN (S.T.). Manual for the identification of medical bacteria. 2nd ed. Cambridge, The University Printing House, 1981.
10. CUMBERBATCH (N.), GURWITH (M.J.), LANGSTON (C.), SACK (R.B.), BRUNTON (J.L.). Cytotoxic enterotoxin produced by *Aeromonas hydrophila* : Relationship of toxigenic isolates to diarrhoeal disease. *Infect. Immun.*, 1979, **23** (3) : 829-837.
11. DE (S.N.), CHATTERJE (D.N.). An experimental study of the mechanism of action of *Vibrio cholerae* on the intestinal mucous membrane. *J. Pathol. Bacteriol.*, 1953, **66** : 559-562.
12. DEAN (A.G.), CHING (C.), WILLIAMS (R.G.), HARDEN (L.B.). Test for *Escherichia coli* enterotoxin using infant mice application in a study of diarrhoea in children in Honolulu. *J. Infect. Dis.*, 1972, **125** : 407-411.
13. DONTA (S.T.), HADDOW (A.D.). Cytotoxic activity of *Aeromonas hydrophila*. *Infect. Immun.*, 1978, **21** : 989-993.
14. DUBOWSKI (K.M.). An outline method for body-fluid glucose determination. *Clin. Chem.*, 1962, **8** : 215-235.
15. EL-SANOUSI (S.M.), GAMEEL (A.A.), MUSA (B.), ABDEL SALAM (I.S.). Properties of *Clostridium perfringens* (A), *Clostridium sordellii* and *Aeromonas hydrophila* isolated from a case of haemorrhagic enteritis in a camel. In : Annual Report of Faculty of Veterinary Science, University of Khartoum, Sudan. 1984. P. 158-167.
16. EL-WISHY (A.B.). A study of the genital organs of the female dromedary (*Camelus dromedarius*). *J. Reprod. Fert.*, 1988, **82** : 587-593.
17. EMERSON (H.), NORRIS (C.). "Red leg" : an infectious disease of frogs. *J. Exp. Med.*, 1905, **7** : 32-60.
18. GAMEEL (A.A.), EL-SANOUSI (S.M.), MUSA (B.), EL-OWANI (E.E.). Association of some pathogenic bacteria with haemorrhagic enteritis in camels. Small Ruminant and Camel Group, 1986. Pp. 50-55 (Group Document No. SRC 12 ILCA)
19. GRAY (S.J.). *Aeromonas hydrophila* in livestock : Incidence, biochemical characteristics and antibiotic susceptibility. *J. Hyg. Cambridge*, 1984, **92** : 365-375.
20. HAZEN (T.C.), FLIERMANS (C.B.), HIRSCH (R.B.), ESCH (G.W.). Prevalence and distribution of *Aeromonas hydrophila* in the United States. *J. Appl. Envir. Microbiol.*, 1978, **36** : 731-738.
21. JIWA (S.F.H.). Enterotoxigenicity, hemagglutination and cell surface hydrophobicity in *Aeromonas hydrophila*, *A. sobria* and *A. salmonicida*. *Vet. Microbiol.*, 1983, **8** : 17-34.
22. KAPER (J.B.), LOCKMAN (H.), COLWELL (R.R.), JOSEPH (S.W.). *Aeromonas hydrophila* : Ecology and toxigenicity of isolates from an estuary. *J. Appl. Bacteriol.*, 1981, **50** : 359-377.
23. KRIEG (N.R.), HOLT (J.G.). Bergey's manual of systematic bacteriology. Vol. I. Baltimore, Williams and Wilkins, 1984.
24. LATSHAW (W.K.). Veterinary developmental anatomy. Toronto, B.C. Decker Inc, 1987.
25. MERKT (H.), KLUG (E.), MERKT (J.C.), RATH (U.D.). Bericht über die Herbstuntersuchung 1985 in der westdeutschen Vollblutzucht. *Vollblut Zucht und Rennen*, 1986, **105** : 13-18.
26. MERKT (H.), RATH (U.D.). The ultrasound, a new approach in veterinary gynaecology. *Sudan J. vet. Sci. Anim. Husband.*, **26** (1) : 13-20.
27. NAWAR (S.M.A.), ABOUL-FADLE (W.S.), MOHAMOUD (S.A.). Studies on the ovarian activity of the dromedary (*Camelus dromedarius*). *Zeitschr Mikrosk. Forsch.*, Leipzig, 1978, **92** : 385-408.
28. NAWITO (M.F.), SHALASH (M.R.), HOPPE (R.), RAKHA (A.M.). Reproduction in the female camel. *Bull. Anim. Sci. Inst., Cairo*, 1976, **2** : 2.
29. NODEN (D.M.), DE LAHUNTA (A.). The embryology of domestic animals developmental mechanisms and malformations. Baltimore, London, Williams and Wilkins, 1985.
30. REITMAN (S.), FRANKEL (S.). A colorimetric method for the determination of serum glutamic oxalacetic and glutamic pyruvic transaminases. *Am. J. clin. Pathol.*, 1957, **28** : 56-63.
31. SHREAD (P.), DONOVAN (T.J.), LEE (J.V.). A survey of the incidence of *Aeromonas* in humans faeces. *Soc. gen. Microbiol. Q.*, 1981, **8** : 184.
32. TAYEB (M.A.F.). Studies on the anatomy of the ovary and corpus luteum of the camel. *Vet. J.*, 1948, **104** : 179-186.
33. TAYEB (M.A.F.). Les organes génitaux de la Chamelle. *Revue Élev. Méd. vét. Pays trop.*, 1953, **6** (1) : 17-21.
34. TURNBULL (P.C.B.), LEE (J.V.), MILIOTIS (M.D.), VAN DE WALLE (S.), KOORNHOF (H.J.), JEFFERY (L.), BRYANT (T.). Enterotoxin production in relation to taxonomic grouping and source of isolation of *Aeromonas* species. *J. clin. Microbiol.*, 1984, **19** : 175-180.
35. WILSON (R.T.). The camel. London, Longman, 1984. 233 p.
36. WOHLGEMUTH (R.), PIERCE (R.L.), KIKRBRIDE (C.A.). Bovine abortion associated with *Aeromonas hydrophila*. *J. Am. vet. Med. Assoc.*, 1972, **60** : 1001-1002.