

Communication

Clinical and pathological features of *Aspergillus fumigatus* infections in poultry in Southern Nigeria

J. O. A. Okoye¹

H. C. Gugnani²

C. N. Okeke²

OKOYE (J. O. A.), GUGNANI (H. C.), OKEKE (C. N.). Aspects cliniques et pathologiques chez des volailles infectées par *Aspergillus fumigatus* dans le Sud du Nigeria. *Revue Elev. Méd. vét. Pays trop.*, 1989, 42 (2) : 153-154.

Cette étude a été entreprise pour obtenir des informations sur l'aspergillose à *Aspergillus fumigatus* des volailles au Nigeria. La maladie se caractérisait chez les poussins de chair par de la suffocation, de la prostration, de l'amaigrissement et une forte mortalité. Chez les poulettes de deuxième âge à l'engraissement on a observé de l'amaigrissement, de la faiblesse, des diarrhées avec 17 p. 100 de mortalité. La maladie était sporadique chez les pondeuses. Des nodules granulomateux ont été observés chez les oiseaux morts à l'apparition de la maladie. Les nodules étaient nombreux et affectaient principalement les poumons et les sacs aériens thoraciques chez les poulets de chair alors que chez les pondeuses seuls quelques gros nodules étaient observés, principalement dans les sacs aériens abdominaux. *Mots clés* : Poussin - Poulet - Aspergillose - Nigeria.

Avian aspergillosis is usually caused by *Aspergillus fumigatus* (6). In Nigeria *A. fumigatus* infection has been described in dogs (4), sheep (3) and humans (2). However published reports on avian mycosis are very few as mycotic infections have not attracted adequate veterinary attention in Nigeria (5). In this paper the clinico-pathological pattern of 3 field outbreaks of *A. fumigatus* infection in chickens is described in Southern Nigeria.

An outbreak that occurred in March 1986 at Ogwashi-Uku, Bendel State of Nigeria affected 2 flocks of 8,000 and 23,000 broiler chicks of 3 weeks old in a broiler breeder farm. Another outbreak was also observed in a group of 3,000 15-week old pullets in a breeder farm at Awka, Anambra State in March 1987. In both farms rearing was by deep litter and feeds were compounded with raw materials bulk-purchased and stored for months. Sporadic deaths due to aspergillosis were observed among laying hens in the Faculty of Agriculture Farm, University of Nigeria, Nsukka, Anambra State on 5 occasions between 1983 and 1987.

1. Department of Veterinary Pathology and Microbiology, University of Nigeria, Nsukka, Nigeria.

2. Department of Microbiology, University of Nigeria, Nsukka, Nigeria.

Reçu le 04.08.88, accepté le 13.09.88.

Sick birds were observed for clinical signs and dead ones were examined for gross lesions. Affected organs were fixed, processed and stained with haematoxylin and eosin (H & E) and periodic acid-Schiff (PAS) or Grocott stains.

Samples of the air sac, lung and abdominal nodules were cultured in Sabouraud's dextrose agar for fungal isolation. Fungal identification was based on microscopic morphology and colony characteristics in Czapek's solution agar. Samples were also cultured in blood agar for bacterial isolation.

Among the broiler chicks at Ogwashi-Uku, the clinical signs of *A. fumigatus* infection were poorly developed and ruffled feathers, severe depression, droopiness, diarrhoea and poor growth. Birds were also observed to show respiratory distress in form of gasping. Mortality was heavy, 76.8 per cent, and those that survived up to 4 weeks after the onset of clinical changes were severely emaciated and had to be destroyed. The clinical changes in the Awka pullets were emaciation, diarrhoea and weakness. Mortality was 17 per cent. The sporadic cases in the Faculty of Agriculture Farm were characterized by death of 1 or 2 birds out of 500-3,000 apparently healthy laying hens.




Fig. 1 : Granulomatous nodules on the lungs (A) and parietal pleura (B) of dead pullets.

The broiler chicks had tiny granulomatous nodules mainly in the thoracic air sacs and lungs which were also consolidated. The abdominal air sac and intestines were often affected. Similar lesions were found in the pullets. But the granulomas were much larger in size up to 0.5 cm in diameter (Fig. 1) and more widespread on the serous surfaces than those of the broiler chicks. Some of the nodules had depressed centres some of which turned green after the carcass had been opened and stored in the refrigerator for a few days. The layers that died in the sporadic cases of aspergillosis showed few but large nodules of up to 2-3 cm in diameter on mainly abdominal air sacs and serous membranes of the abdominal region. The

Communication

lungs and thoracic air sacs were not frequently affected.

Microscopic pathological changes were similar in the 3 groups of chickens studied. The H & E sections of the lungs and air sacs showed severe granulomatous inflammation. The granulomas contained eosinophilic debris, epithelioid cells, giant cells and poorly stained eosinophilic fungal hyphae or remnants of dead hyphae. Areas of fresh infection were characterized by necrosis and massive phagocytic activity. Granulomas on the serous wall of the intestines were associated with necrosis of the villus epithelial cells. Sections of the lungs, thoracic and abdominal air sacs and intestines stained with PAS or Grocott showed well stained septate, dichotomously branching fungal hyphae (Fig. 2).

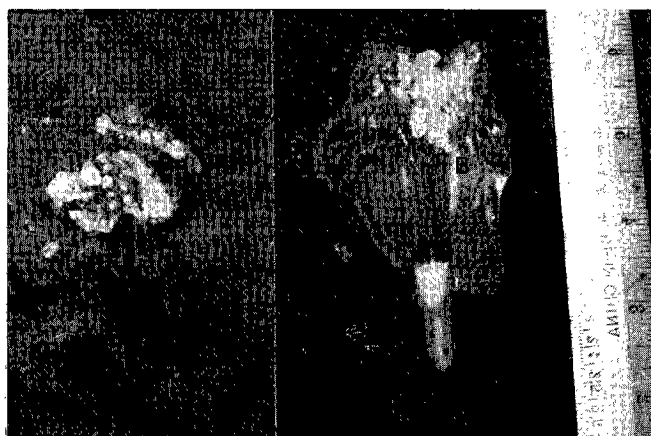

Fig. 2 : Air sac of broiler chicks showing septate *Aspergillus fumigatus* hyphae. (H & E, x 400).

A. fumigatus was isolated from the lungs, air sac and intestinal nodules of the broilers, pullets and layers. The blood cultures yielded no bacterial growth.

The clinical and pathological changes observed in this study are similar to those already described for brooder pneumonia in chicks and sporadic or chronic form of aspergillosis in older birds (1). The necrosis of the epithelium of the villi observed in this study could be due to infarction caused by the granuloma in the serosa of the intestinal wall. The results of this study show that *Aspergillus* granulomas are smaller in size, numerous and affect mainly the lungs and thoracic air sac in young birds leading to severe clinical signs and high mortality. However in the adult the granulomas are few but bigger in size and affect mainly the abdominal air sac without much clinical signs and mortality.

Acknowledgement

The authors are grateful to Mr. E. O. ONUOHA of the Department of Veterinary Pathology and Microbiology for preparing the histopathological sections.

OKOYE (J. O. A.), GUGNANI (H. C.), OKEKE (C. N.). Clinical and pathological features of *Aspergillus fumigatus* infections in poultry in Southern Nigeria. *Revue Élev. Méd. vét. Pays trop.*, 1989, 42 (2) : 153-154.

This study was undertaken to supply information on *Aspergillus fumigatus* infection of poultry in Nigeria. The disease in broiler chicks was characterized by gasping, droopiness, emaciation and heavy mortality while affected grower chickens showed emaciation, weakness, diarrhoea and 17 per cent mortality. The disease was sporadic in laying flocks. Granulomatous nodules were observed in birds that died in each outbreak. The nodules were numerous and affected mainly the lungs and thoracic air sacs in the broiler chicks while only few large nodules were observed mainly in the abdominal air sacs in the layers. *Key words* : Chick - Chicken - Aspergillosis - Nigeria.

References

1. CHUTE (H. L.). Fungal infections. In : Diseases of Poultry. Ames, Iowa State University Press, 1978.
2. GUGNANI (H. C.), GUPTA (S.), TALWAR (R. S.). Role of opportunistic fungi in ocular infections in Nigeria. *Mycopathologia*, 1978, 65 : 155-166.
3. IKEDE (B. O.). The occurrence of deep mycoses in livestock at the University of Ibadan Farm. *Nigerian J. Anim. Prod.*, 1974, 1 : 127-131.
4. ISOUN (T. T.). Disseminated aspergillosis in a dog. *Nigerian vet. J.*, 1975, 4 : 45-48.
5. MOHAN (K.). Nocardiosis and some mycotic infections of livestock in Nigeria. National Workshop on Diseases of Livestock and Poultry, Vom, Nigeria, 1983.
6. WHITEMAN (C. E.), BICKFORD (A. A.). Avian Disease Manual. Pennsylvania, American Association of Avian Pathologists, 1983.