

Studies on the toxicity of *Tacazzea yototacolla* on Ethiopian Rift valley goats

Y. Mekonnen¹
B. Faye²

Toxicité de *Tacazzea yototacolla* chez des chèvres éthiopiennes de la vallée du Rift — Deux essais d'intoxication à base de poudre de feuilles de *Tacazzea yototacolla*, en solution dans l'eau, administré *per os* par pistolet doseur, ont été réalisés sur 16 chèvres de la vallée du Rift éthiopien.

Dans la première expérimentation, 3 lots de 2 chèvres reçoivent respectivement 1 g, 0,8 g et 0,4 g de poudre de feuilles séchées par kg de poids vif. Les 4 chèvres des 2 premiers lots meurent en moins de 4 h 30 min. Les animaux du groupe 3 montrent des signes d'intoxication grave, mais survivent.

Dans la seconde expérimentation, 5 chèvres reçoivent une dose subléthale de *T. yototacolla* (100 mg/kg de poids vif et par jour) selon la même méthode que précédemment). Toutes les chèvres du lot traité montrent une diminution graduelle de leur condition, et 2 d'entre elles meurent respectivement au 6^e et au 16^e jour d'intoxication. Les 5 chèvres du lot témoin ne manifestent aucun signe particulier. Les valeurs du pouls, de la température rectale et du rythme respiratoire sont présentées. Les caractéristiques des symptômes et des résultats d'autopsie obtenus lors des 2 expérimentations sont analysées. *Mots clés* : Caprin - *Tacazzea yototacolla* - Plante toxique - Toxicité - Intoxication - Ethiopie.

and it increases incidence of poisoning. The Afar breeders use the stem as small cord.

T. yototacolla is often refused by animals. This may be due to the irritating juice it has which is described for most of the poisonous plants; it is a latex producing plant. The incidence of animal poisoning with *T. yototacolla* is greater during the dry season when there is scarcity of pasture. Animals also consume this plant by mistake when they are searching for grasses left under trees and leaves of palatable plants and bushes. It is the leafy part of the plant which is consumed. Camels and goats are more often poisoned because they are in the habit of eating the tree leaves. Camels seem to be more sensitive to the poisoning.

No investigation has been done in any part of the world about its being a poisonous plant, and then this report is without reference (2). What urged the investigators to conduct the experiment was the local information, *i.e.* the complaint by the Afar breeders.

The purpose of this work was first and foremost to prove whether *T. yototacolla* is poisonous or not, to determine the approximate lethal dose and then to present the effects of acute and chronic experimental poisoning of goats using water mixed powder of the leaves. This preliminary study was concentrated on the clinical findings and post-mortem changes (gross and microscopic) of organs and tissues following the administration of two levels of doses.

INTRODUCTION

The problem of intoxication of domestic livestock by poisonous plants has a great significance in many parts of the world due to the fact that it has resulted in a prodigious economic loss. The plant *T. yototacolla* (*Asclepiadaceae* F.) which is complained by the Afars as a poisonous plant is present everywhere in Middle Awash Valley and in areas around, of course with variable density. It is a scrambling plant not only poisonous to animals but it also climbs to top of trees preventing them from getting sunlight. What expedites its distribution is the characteristic feature of the seeds to be carried by wind when the pod explodes, and its overgrowing quality. This makes the plant to distribute faster, to invade a considerable part of pasture land,

MATERIAL AND METHODS

Material used

A total of 16 male goats of about 10 months old, bought from the area, divided into two (6 for experiment one and 10 for experiment two) were used for the experiment. All were treated against internal parasites (GIT and

1. Faculty of Veterinary Medicine, PO Box 34, Debre Zeit, Ethiopia.

2. Laboratoire d'éco-pathologie, INRA-Theix, 63122 Ceyrat, France.

lungworms) one week before the experiment, physical examination had been done and all were apparently normal. *Tacazzea* leaves were dried, ground and prepared in powder form to be given *per os* mixed with water by drenching. Instruments such as those used to detect the physiological deviation in respiration, pulse and temperature, autopsy instruments, and all instruments necessary for histopathologic processing and examination were also used.

Experiment procedure

Experiment one

The 6 goats were divided into 3 groups (each containing 2) and intoxicated with *Tacazzea* leaf powder mixed with water given *per os* at a rate of 1 g/kg liveweight for group one, 0.8 g/kg liveweight for group two, and 0.4 g/kg liveweight for group three. Pulse, temperature and respiration were examined before and following administration until death. Other clinical signs were also recorded according to their occurrence. An autopsy had been done one and half hour after death, all gross pathologic changes observed and pictured, and tissue samples of important organs were taken for histopathologic examination; these were also pictured.

Experiment two

The 10 goats were divided into 2 groups (each comprised 5 goats). Goats in group one were controls and those in group two were taking *T. yototacolla* (n^{os} 1, 2, 3, 4, 5). The liveweight of all goats was taken before intoxication. *T. yototacolla* leaf powder mixed with water was given *per os* at a rate of 100 mg/kg liveweight daily for three weeks.

Out of the 5 experimentally intoxicated goats 2 of them died on different occasions, the first one on the 6th day and the second one on the 17th day of intoxication. The remaining 3 stayed alive until the end of the experiment and were then slaughtered.

The controls were given the same volume of distilled water *per os* by drenching. Pulse, temperature and respiration were recorded daily for five days and then every other day until the end at 10.00 am together with the observation of other clinical signs. Samples of some tissues (lung, liver, kidney, heart, intestine, spleen, adrenals and brain) were taken, and microscopic examination carried out.

RESULTS

Clinical observations

Experiment one

Out of the three groups, all goats in group one and two died within several hours after intoxication. The time interval between administration and death varies within a group and between groups. It was 2 h 30 min for goats in group one, and 3 h 30 and 4 h 30 min for goats in group two. Goats in group three were showing signs of poisoning but they didn't die of *T. yototacolla* intoxication. The clinical signs that groups one and two were showing were the same except that the time of death was different.

Several minutes after administration, the 4 goats (group one and two) stopped eating and became alert. A short while later all goats preferred to lie down. Then followed periods of restlessness, lying down and standing up, producing noise of distress, jumping, assuming lateral recumbency, mouth breathing, and finally opisthotonus and gasping until death occurs.

Heartbeat was slightly increased in frequency and the beat was stronger than it was before intoxication. Later on the beat increased in amplitude, reduced in frequency to a stage below normal and was arrhythmic until death. The rate of respiration was little affected, but was dyspnoeic and arrhythmic. Defecation and urination were frequent.

Goats in group three (400 mg/kg) were showing signs of poisoning but survived. All were becoming sleepy after about 1 hour of administration and lie down for long. One of them was vomiting with retching movement of the stomach and the other was becoming diarrhoeic for two days and finally both return to normal.

Experiment two

All goats in group two showed gradual bodyweight loss. During higher temperature of the day they had stopped eating and preferred to be under shadow for longer period than the controls. Gradual decrease in food intake was simultaneously observed. Goats n^{os} 1 and 3 were showing diarrhoea few days before death, and both manifested a decrease in respiratory rate with dyspnoea and increased amplitude, and a considerable increase in pulse. Finally the pulse rate decreased to values below normal, arrhythmia occurred, both assumed recumbent position, opisthotonus gasping and death. The 3 goats didn't die until three weeks but

the gradual body weighloss and intolerance of environmental temperature were continuing. In general, depressed respiration and increased pulse rate were usually found significant (at $P < 0.001$). Recorded values of pulse, temperature and respiration of both intoxicated and control goats are shown in figures 1, 2 and 3.

As compared to the control group (mean = 79.0), the pulse rate of the treated group (mean = 90.2) had shown a significant variation showing that the goats were unable to maintain the pulse rate in a narrow range (Fig. 1). Concerning the respiratory rate it was

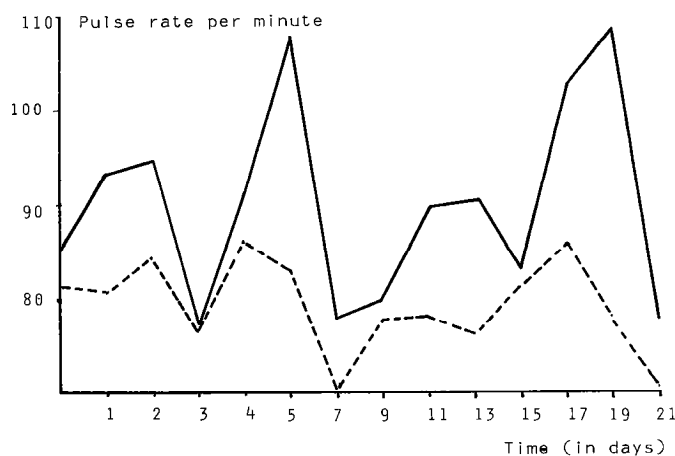


Fig. 1 : Pulse rate per minute in goats during the chronic intoxication with *T. yototacolla* at a rate of 100 mg/kg for three weeks. Control ---- Treated — .

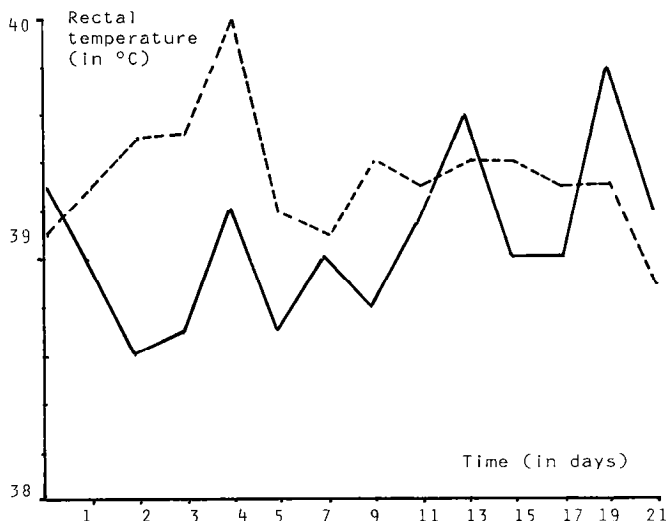


Fig. 2 : Rectal temperature (in °C) in goats during the chronic intoxication with *T. yototacolla* at a rate of 100 mg/kg liveweight daily for three weeks. Control ---- Treated — .

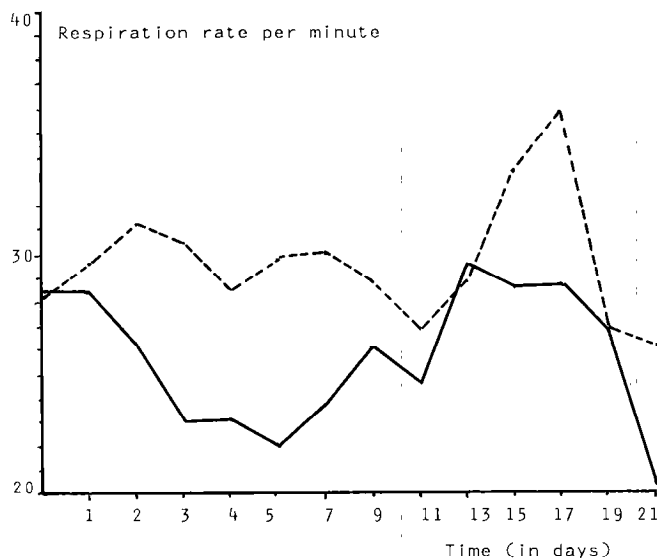


Fig. 3 : Respiration rate per minute in goats during the chronic intoxication with *T. yototacolla* at a rate of 100 mg/kg liveweight daily for three weeks. Control ---- Treated — .

slightly lower for treated ones in most of the days and finally had shown significant lowering (Fig. 2) (mean for treated = $25.5 \pm$ mean for control = 29.5). There is a slightly decrease of rectal temperature for treated ones at the beginning of the experiment (significant at $P < 0.05$) but the difference is not significant after one week (mean of treated = 39.07°C – mean for control = 39.35°C) (Fig. 3).

Post-mortem examinations

Post-mortem results from dying goats

Post-mortem results: externally grossly the visible changes were cyanosis of the visible mucous membranes, moderate bloating in all goats, and serous-like fluid discharge through the mouth. The subcutaneous tissue showed congestion of blood vessels in the 4 goats. All the abdominal organs were congested and rumen and reticulum with gas and frothy content. The livers were cyanotic, enlarged and friable. Mesenteric lymph nodes were swollen, kidneys were cyanotic and congested.

In all the 4 goats the right heart (both atrium and ventricle) was dilated and filled with dark clotted blood. The anterior and posterior venacavas were congested. The left auricles and ventricles were contracted. In all cases the lungs were congested and rubber-like in consistency postero-ventrally and emphysematous

Y. Mekonnen, B. Faye

anterio-dorsally. Pin-point hemorrhage and edema were also observed. Bronchi and bronchioles were filled with foam.

Microscopically, in the lungs, there was destruction of the alveoli and then formation of wide air spaces. Interstitial hemorrhage, congestion and edema were also seen. Hemorrhage was observed in other organs too such as the heart, kidneys, spleen, adrenal gland and liver; considerable in the kidneys and spleen. Congestion was the main finding in the right heart, kidneys, brain, liver and small intestine. In the small intestine, desquamation of the mucosal cells was also observed.

Post-mortem findings from killed goats

Grossly all the lungs were haemorrhagic, rubber-like in consistency (postero-ventrally) and emphysematous dorsally. The lungs of goats n^{os} 1 and 3 were having pinkish red color. The trachea, bronchi and bronchioles of goat n^o 1 were filled with foam. Dilation of the right heart and hypertrophy of the left ventricle were the main findings in all cases except that hypertrophy was not observed in goat n^o 3. All the veins that enter the right heart were congested with dark clotted blood. Approximately 20 ml of fluid was found in the pericardial sac in 3 of them (n^{os} 1, 2 and 4). Blood tinged fluid was also observed in the thoracic cavity. Epicardial hemorrhage and coronary fat degeneration were observed in goats n^{os} 1 and 3.

All abdominal organs were congested and approximately 50 ml of blood tinged abdominal fluid was found in goats n^{os} 1, 2 and 5. The livers of goats n^{os} 4 and 5 were enlarged, yellowish in color and friable, and those of n^{os} 1 and 2 were having white patchy necrotic areas and connected to kidneys and diaphragm showing fibrinous inflammation. Mesenteric fat degeneration was observed in goats n^{os} 2, 4 and 5. All kidneys in all cases were congested and cyanotic. On the cut surface blood oozed out, and the cortex and medulla were indistinguishable.

Microscopically all the lungs were acidophilic, congested edematous and highly hemorrhagic. Alveolar wall destruction also were the main finding. In all the livers, cell swelling and degeneration, infiltration of lymphoid cells and scanty granulocytes, congestion of the central vein and hemorrhage of variable degree were common. In the livers of goats n^{os} 1 and 2, necrotic areas surrounded by connective tissue and inflammatory cells was found. Congestion and edema were also common in the spleens, kidneys and brains.

DISCUSSION

Even though it is a new discovery, and experiments have not been carried out on different species of domestic animals, the outstanding results obtained in both experiments proved *T. yototacolla* a poisonous plant.

Experiment one was carried out to demonstrate the lethal toxicity of the plant, the associated clinical manifestations, and to detect the organs of concern. In this experiment goats that had been given whole ground berries of *T. yototacolla* 1 g/kg and 0.8 g/kg of liveweight had died with acute intoxication. So, in field condition, 2.66 g of fresh matter per kg liveweight can kill the goats with acute intoxication. Had it not been the case and if the extraction of the active principle (s) was made the minimum lethal dose would be lower by many folds.

The clinical signs observed and the post-mortem results obtained had proved that the primary organs affected were the lungs and, to lesser extent, the liver. Signs and post-mortem results other than these were secondary. The main gross post-mortem findings were congestion, pin-point hemorrhage and antero-dorsal emphysema of lungs, right heart failure and general congestion. Microscopically, in the lungs, there was destruction of the alveoli, interstitial hemorrhage and congestion. Congestion and hemorrhage were also observed in the livers, kidneys, intestines, spleens and adrenals. These preliminary observations seem to indicate that the capillary damage produced by the poisonous factor(s) was responsible for the congestion and hemorrhage of lungs; the lungs possess highly anastomosed capillary bed. Emphysema which develops in association with the above lesions was compensatory as though over distention of the residual lung causes alveolar dilation and later on destruction of the alveolar wall.

The right heart was then overburdened by the pressure created in the lungs which resulted in general congestion. Reduction in the vital capacity of the lungs impaired oxygenation of the blood. Oxygenation was further reduced by decreased rate of blood flow through the pulmonary vascular bed (1). Finally anoxia was responsible for the death of the goats.

Experiment two was carried out for three weeks by intoxicating the goats with subclinical doses of *T. yototacolla* (100 mg/kg liveweight per day) to show the chronic effects of the poisonous plant in question. The gradual loss of condition and other manifestations together with the death of 2 goats have substantiated with certainty that the toxin has a cumulative effect.

This indicates that in field condition goats gradually consuming at least 333 mg fresh matter per kg live-weight per day can have chronic poisoning.

The salient gross post-mortem changes of paramount importance observed were hemorrhage, congestion and emphysema of all the lungs. Two of the livers (n^{os} 1 and 2) were having patchy necrotic areas and three others friable and slightly yellowish. Microscopically in the lungs congestion, edema, alveolar destruction and extensive and massive hemorrhage were highly significant. In the livers, cell swelling and degeneration, connective tissue proliferation indicate that the cause of the death in the 2 goats was anoxia due to impaired oxygenation of the blood imposed by the lesions in the lungs. Cell death and degeneration in the livers could be attributed to the direct effect of the poison on cells while connective tissue proliferation is a response to liver tissue damage. Yellowish discoloration of the liver on the other hand seems to be due to impaired bile pigment metabolism that resulted in the accumulation. Hypertrophy of the left ventricles may be related to a compensatory response of the body to hypoxia.

In understanding the pathological physiology of this plant it would be useful to determine whether the congestion and edema are due to direct effect on capillaries, or the backlogue of blood due to right heart failure, or both. At the present stage of the study the active ingredients are not yet identified, and their specific action on different organs and tissues has not been investigated.

MEKONNEN (Y.), FAYE (B.), Studies on the toxicity of *Tacazzea yototacolla* on Ethiopian Rift valley goats. *Rev. Elev. Méd. vét. Pays trop.*, 1986, 39 (2) : 221-226.

Two experiments were performed on 16 goats using a leaf of *T. yototacolla* mixed with water, administered *per os*. In the first experiment 3 groups of 2 goats were involved and given 1 g/kg, 0.8 g/kg and 0.4 g/kg of liveweight for group one, group two and group three respectively. Out of the 3 groups group one and group two died within 4 h 30 min. Those in group three were showing signs of ill-health but survived.

In the second experiment 5 goats were given subclinical doses of *T. yototacolla* at a rate of 100 mg/kg daily in the same method as in experiment one. All showed gradual loss of condition and 2 died at 6th and 16th day of intoxication. The 5 control goats didn't show any sign of ill-health. The characteristics of pulse, temperature and respirations are given. Gross and microscopic post-mortem findings of both experiments are presented. *Key words* : Goat - *Tacazzea yototacolla* - Poisonous plant - Toxicity - Intoxication - Ethiopia.

There are also other unanswered questions such as the effect of *T. yototacolla* on other species of domestic animals, the part of plant where the active principle (s) is (are) concentrated and possible antidotes to serious cases of intoxication.

CONCLUSION

For it was being proved to be a poisonous plant according to this experiment, concerning animal poisoning only, that plant should be controlled. However, since the plant could have any medical or ecological significance, for any control measure that is going to be taken, be it to eliminate the plant completely or to grow it in a controlled environment far from the reach of animals and what have you, further studies and investigations should be made.

ACKNOWLEDGEMENTS

Our special thanks go to all the members of NOMADEP specially Mr Moise LABONNE for his cordial aid financially and materially. We are indebted to Ms Amelework IYADO for her technical assistance in histologic processing of tissues. ■

MEKONNEN (Y.), FAYE (B.), Toxicidad de *Tacazzea yototacolla* en cabras étiope de la valle del Rift. *Rev. Elev. Méd. vét. Pays trop.*, 1986, 39 (2) : 221-226.

Se efectuaron dos ensayos de intoxicación de 16 cabras etíopes de la valle del Rift con polvo de hojas de *Tacazzea yototacolla*, en solución en el agua, administrado *per os* por pistola dosificador.

En la primera experimentación, se dan a 3 grupos de 2 cabras respectivamente 1 g, 0,8 g y 0,4 g de polvo de hojas secadas por kg de peso vivo. En los 2 primeros grupos, las 4 cabras mueren en menos de 4 h 30. Los animales del grupo 3 muestran síntomas de intoxicación grave, pero sobreviven.

En la segunda experimentación, se dan a 5 cabras una dosis subletal de *T. yototacolla* (100 mg/kg de peso vivo y por día) según el mismo método.

Todas las cabras del grupo tratado muestran una disminución gradual de su estado, y 2 de ellas mueren respectivamente al 6° y al 10° día de intoxicación. Las 5 cabras del grupo testigo no manifiestan ningún síntoma particular. Se indican los valores del pulso, de la temperatura rectal y del ritmo respiratorio. Se analizan las características de los síntomas y de los resultados de la autopsia obtenidas durante las 2 experimentaciones. *Palabras claves* : Cabra - *Tacazzea yototacolla* - Planta tóxica - Toxicidad - Intoxicación - Etiopia.

Y. Mekonnen, B. Faye

REFERENCES

1. HENDERSON (R.). Blood text book of veterinary medicine. 5th ed., Philadelphia, USA, 1975.
2. WATT (J. M.), BREYER-BRANDWIJK (M. G.). The medicinal and poisonous plants of Southern and Eastern Africa. 2nd ed., Edinburgh, Livingston Ltd, 1962. pp. 124-127.