

# The histological relationship between « peste des petits ruminants » and kata in West Africa

by A. C. ROWLAND and P. BOURDIN

## SUMMARY

The histopathology of « Peste des Petits Ruminants (P.P.R.) » and Kata was compared. The lesions demonstrated a close similarity, with necrosis of alimentary tract epithelium, degeneration and proliferation in respiratory epithelium and depression of lymphoid tissues. Intranuclear and intracytoplasmic inclusion bodies occurred constantly in epithelial tissues.

## RESUME

L'histopathologie comparée de la Peste des Petits Ruminants (P.P.R.) et de la « Kata » montre que les lésions sont identiques avec en particulier une nécrose de l'épithélium du tractus digestif, une dégénérescence et une prolifération dans l'épithélium du tissu pulmonaire et un appauvrissement du tissu lymphoïde.

La présence d'inclusions intranucléaires et intracytoplasmiques est constante dans les tissus épithéliaux.

## INTRODUCTION

For many years, a disease of the West African dwarf goat, « Peste des Petits Ruminants » (P.P.R.), has been known in West Africa (GARGADENNEC and LALANNE, 1942; MORNET, ORUE, GILBERT, THIERY and SOW MAMADOU, 1956).

The causal agent of P.P.R. is a paramyxovirus similar to, although larger than the paramyxoviruses of measles, distemper and rinderpest. (BOURDIN and LAURENT, 1967; LAURENT, 1968).

A transmissible disease of the West African dwarf goat resembling rinderpest was first described in Nigeria in 1965 (WHITNEY, SCOTT and HILL, 1967; ROWLAND, SCOTT and HILL, 1969) and provisionally named Kata.

The two diseases, P.P.R. and Kata, show clinically an erosive stomatitis with extension

of lesions over the lips, severe diarrhoea and catarrhal inflammation of the respiratory tract. At post-mortem examination, erosions may be observed in the mouth, pharynx and oesophagus. In the intestine, congestion of the ileo-caecal valve and longitudinal folds of the large bowel is a common feature and in addition to respiratory tract inflammation, the lungs may show consolidation of individual lobules.

This paper compares the histopathological changes observed in these two diseases. The study was carried out at the Laboratoire National de l'Elevage et de Recherches Vétérinaires in Dakar-Hann, Dakar, Sénégal.

## MATERIAL AND METHODS

The P.P.R. sections were provided by courtesy of the Director, M. ORUE. The Kata sections were prepared at the University of Ibadan, Nigeria. Both the P.P.R. and the Kata

material had been obtained from acute experimental infections.

The tissues examined were from the alimentary and respiratory systems and from the muco-cutaneous junctions. These had been fixed in 10 per cent formol saline or Bouin's fluid, embedded in paraffin wax and stained by haematoxylin and eosin.

## RESULTS

Histologically, the two diseases, P.P.R. and Kata, presented a similar pattern of patholo-

gical change. Essentially, the most prominent cellular changes were degenerative and necrotising, sometimes overlaid by a marked proliferation from the surviving epithelial cells.

### Alimentary tract

Lesions of the upper alimentary tract developed within the stratum spinosum and granulosum. Affected cells showed changes varying from vacuolation to coagulation with nuclear pyknosis and karyorrhexis. Syncytial aggregations occurred from time to time (Fig. 1). Inclusion bodies were observed, both intranuclear and intracytoplasmic in situation



Fig. 1. — Mucosa tongue. Early lesions showing a syncytium (A), foci of necrosis (B) and vacuolation of the mucosal epithelium. Haematoxylin and Eosin. ( $\times 200$ ).

Fig. 1. — Muqueuse de la langue. Lésions précoces montrant un syncytium (A), des foyers de nécrose (B) et une vacuolisation de la muqueuse épithéliale. Hématoxyline-Eosine ( $\times 200$ ).

(Figs. 2 and 3). These were usually brightly eosinophilic or occasionally slightly amphiphilic, round or oval in the nucleus and often fragmented in the cytoplasm. The degenerate epithelium was rapidly eroded leaving only a scanty debris above the surviving stratum germinativum.

The stomach and intestines showed necrosis of the epithelium, both superficially and in the deep glands with loss of villi in the small intestine. Accumulations of cell debris were present in the lumen of many intestinal glands

but haemorrhage was not observed. Intracytoplasmic and intranuclear inclusion bodies, similar in form to those in the oral cavity, were distributed throughout the mucosal epithelium (Figs. 4 and 5) in variable numbers. Occasionally, they were numerous.

### Respiratory system

The respiratory tract showed mucosal necrosis and hyperplasia. Again vacuolation and coagulation of cell cytoplasm were present, together with pyknosis and karyorrhexis. In

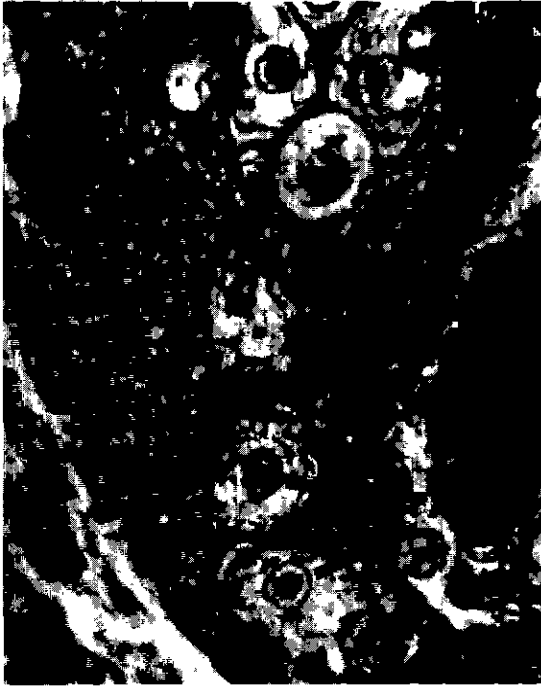

Fig. 2. — Mucosa cheek. Intranuclear inclusion bodies in epithelium (A). H. & E. ( $\times 800$ ).

Fig. 2. — Muqueuse buccale. Inclusions intranucléaires dans l'épithélium. H. & E. ( $\times 800$ ).



Fig. 3. — Mucosa tongue. Intracytoplasmic inclusion body (A) and vacuolated epithelium. H. & E. ( $\times 500$ ).

Fig. 3. — Muqueuse linguale Inclusions intracytoplasmiques (A) et épithélium vacuolé. H. & E. ( $\times 500$ ).



Fig. 4. — Ileum. Destruction of villi and accumulation of debris in lumen of glands. H. & E. ( $\times 125$ ).

Fig. 4 — Ileon Destruction des villosités et accumulation des débris dans la lumière de la glande. H. & E. ( $\times 125$ ).

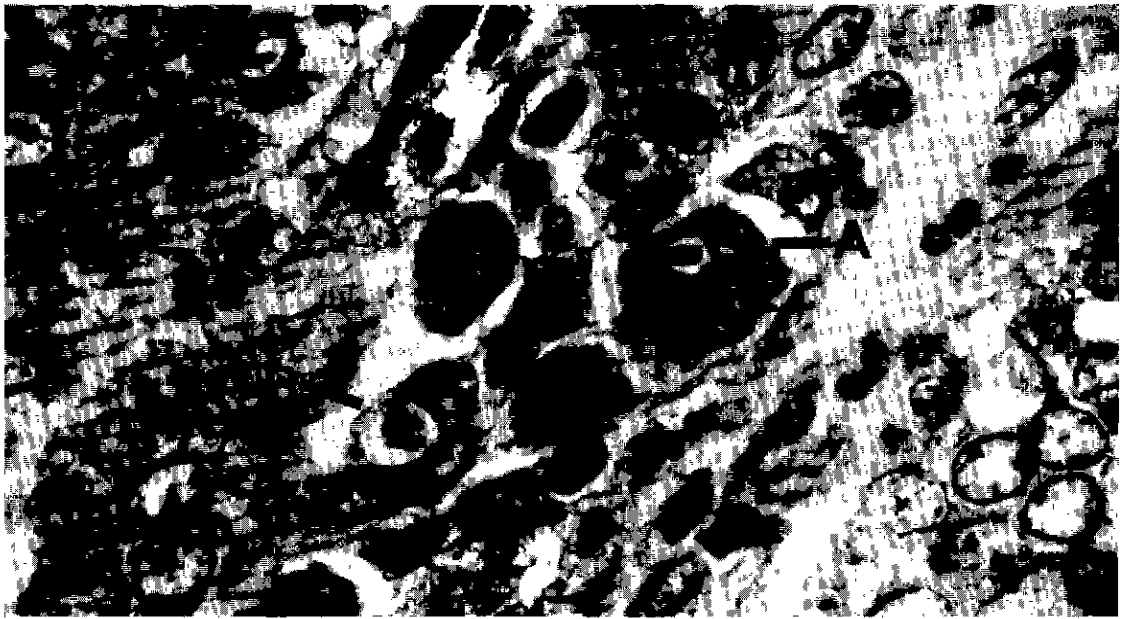

Fig. 5. — Ileum. Intranuclear (A) and intracytoplasmic (B) inclusion bodies in epithelial cells. H. & E. ( $\times 1250$ ).

Fig. 5. — Ileon. Inclusions intranucléaires (A) et intracytoplasmiques (B) dans les cellules épithéliales. H. & E. ( $\times 1250$ ).

affected areas, the epithelial lining consisted of irregular cellular masses, four to five cells deep (Figs. 6 and 7). Eosinophilic intranuclear

and intracytoplasmic inclusion bodies were occasionally present.

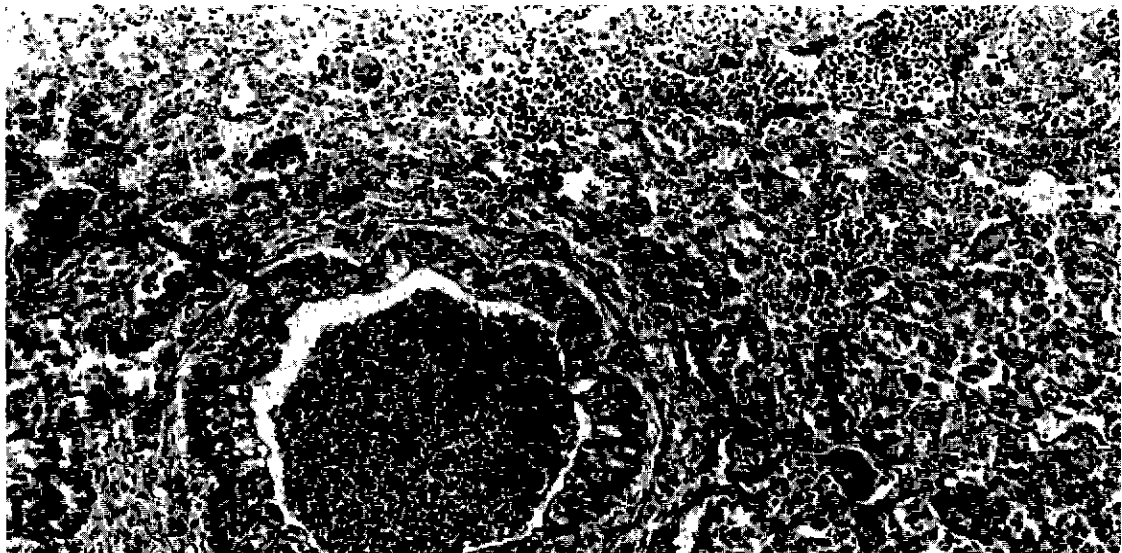


Fig. 6. — Lung. Bronchiolitis and pneumonia. Degeneration and proliferation of bronchiolar mucosa (A). Giant cells in lung parenchyma (B). H. & E. ( $\times 100$ ).

Fig. 6. — Poumon. Bronchite et pneumonie. Dégénérescence et prolifération de la muqueuse bronchiale (A). Cellules géantes dans le parenchyme pulmonaire (B). H. & E. ( $\times 100$ ).




Fig. 7. — Bronchial mucosa. Intracytoplasmic inclusion bodies in epithelium (A). H. & E. (× 500).

Fig. 7. — Muqueuse bronchique. Inclusions intracytoplasmiques dans l'épithélium (A). H. & E. (× 500).

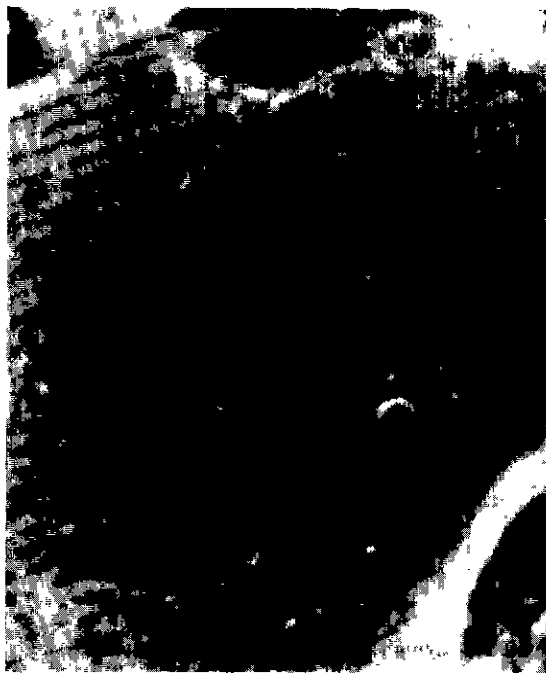

Fig. 8. — Lung. Alveolar giant cell. Intranuclear inclusion bodies. H. & E. (× 2000)

Fig. 8. — Poumon. Cellule géante alvéolaire. Inclusions intranucléaires. H. & E. (× 2000).

The lung parenchyma adjacent to affected bronchioles showed cellular infiltration. There was proliferation from the alveolar walls and the presence in many alveoli of large multinucleate giant cells. Some of these cells were degenerate with pyknotic nuclei. In others, the cytoplasm was dense and amorphous and their nuclei round or oval in shape containing large eosinophilic inclusion bodies (Fig. 8).

#### Lympho-reticular tissues

The lymphoid tissues examined showed some loss of architecture. Follicles were indistinct and perifollicular lymphocytes absent (Figs. 9 and 10). Reticulo-endothelial cells were often numerous in the sinuses and a number of the lymph nodes examined showed a scattering of pyknotic cells throughout the cortex with occasional areas of necrosis (Fig. 11).

#### Muco-cutaneous junctions

The muco-cutaneous junctions of the lips, eyelids and vulva showed a necrotising reac-

tion initially similar to that present in the oral cavity but followed by a moderately intense infiltration of the cutaneous epithelium by neutrophil polymorphs and lymphocytes. Again intranuclear and intracytoplasmic inclusions were observed of similar form to those present in other epithelial tissues.

#### DISCUSSION

This comparative study reveals a close similarity in histopathological changes produced by the two diseases of P.P.R. and Kata. The consistency, in terms of distribution and character, of necrosis in the alimentary tract is notable as are the degenerative and proliferative changes present in the respiratory mucosa and lung substance.

Furthermore, the occurrence of eosinophilic intranuclear and intracytoplasmic inclusion bodies in the alimentary and respiratory tract epithelium proved to be a common feature of the two conditions.






Fig. 9. — Lymph node. Oedema of subcapsular sinus. Loss of lymphoid follicles. H. & E. ( $\times 80$ ).

Fig. 9. — Ganglion lymphatique. Œdème des sinus sous-capsulaires. Disparition des follicules lymphatiques. H. & E. ( $\times 80$ ).

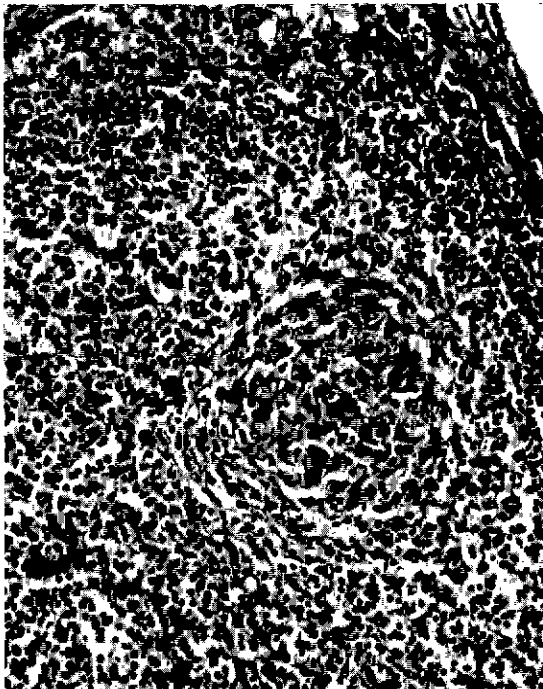


Fig. 10. — Lymph node cortex. Involved lymphoid follicle with prominent mass of reticulum cells. H. & E. ( $\times 500$ ).

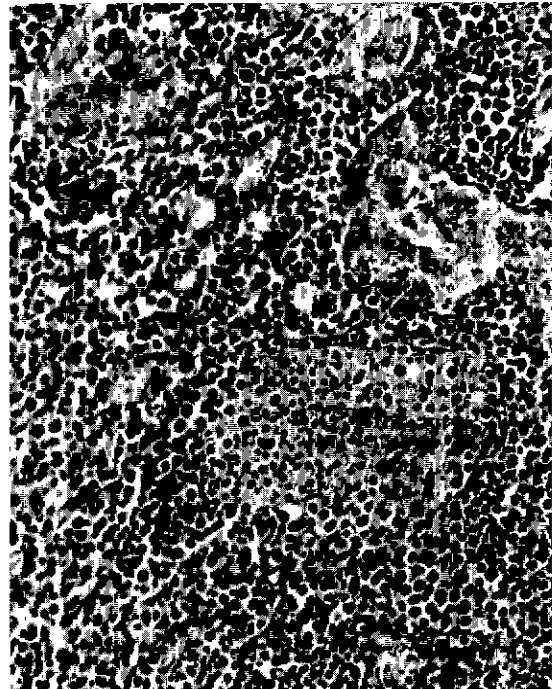


Fig. 11. — Lymph node cortex. Necrosis of lymphocytes in the deep cortex. H. & E. ( $\times 200$ ).

Fig. 10. — Cortex ganglionnaire. Régression des follicules lymphoïdes et prolifération de cellules réticulaires. H. & E. ( $\times 500$ ).

Fig. 11. — Cortex ganglionnaire. Nécrose des lymphocytes du cortex profond. H. & E. ( $\times 200$ ).

These findings, together with the evidence of earlier studies (MORNET et al. 1956; WHITNEY et al. 1967), strongly suggest a closely similar aetiological agent. It is interesting also to observe that lesions of this type have been described in diseases produced by other members of the paramyxovirus group - measles, distemper and rinderpest. The two former demonstrate a giant cell pneumonia (PINKERTON, SMILEY and ANDERSON, 1945) with intranuclear and intracytoplasmic inclusions but without necrosis of the alimentary tract mucosa. Rinderpest is marked by alimentary tract and lymphoid tissue necrosis (THIERY, 1956) but pneumonic lesions have not been reported.

### ACKNOWLEDGEMENTS

The authors wish to thank Monsieur ORUE, Directeur of the Laboratoire National de l'Elevage et de Recherches Vétérinaires at Dakar-Hann, Sénégal for his encouragement in this study and for his permission to publish. We are indebted to Mr. R.C. JAMES of the Department of Veterinary Pathology, University of Edinburgh for the photography and to Miss M. MITCHELL for her help in preparing the manuscript.

This work as supported in part by a grant from the Ministry of Overseas Development, and also by the "Fond d'aide et de Coopération".

Department of Veterinary Pathology,  
Royal (DICK) School of Veterinary  
Studies, Veterinary Field Station,  
Easter Bush, Roslin, Midlothian,  
Scotland.

Institut d'Elevage et de Médecine  
vétérinaire des Pays tropicaux.  
Laboratoire national de l'Elevage et  
de Recherches vétérinaires,  
Dakar-Hann, Sénégal.

### RESUMEN

#### Relación histológica entre la peste de los pequeños rumiantes y la « Kata » en Africa del oeste

La histopatología comparada de la peste de los pequeños rumiantes y de la « Kata » muestra que las lesiones son idénticas particularmente con una necrosis del epitelio del tracto digestivo, una degeneración y una proliferación en el epitelio del tejido pulmonar y un empobrecimiento del tejido linfóide.

Es constante la presencia de inclusiones intranucleares e intracitoplasmicas en los tejidos epiteliales.

### REFERENCES

- BOURDIN (P.), LAURENT (A.), « Note sur la structure du virus de la peste des petits ruminants », *Rev. Elev. Méd. vét. Pays trop.*, 1967, **20**, 3, 383-386.
- GARGADENNEC (L.), LALANNE (A.), « La peste des petits ruminants », *Bull. Serv. zootech. Epiz. A.O.F.*, 1942, **5**, 1, 16-21.
- LAURENT (A.), « Aspects biologiques de la multiplication du virus de la peste des petits ruminants ou P.P.R. sur les cultures cellulaires », *Rev. Elev. Méd. vét. Pays trop.*, 1968, **21**, 3, 297-308.
- MORNET (P.), ORUE (J.), GILBERT (Y.), THIERY (G.) and SOW MAMADOU, « La peste des petits ruminants en Afrique occidentale française. Ses rapports avec la peste bovine », *Rev. Elev. Méd. vét. Pays trop.*, 1956, **9**, 313-342.
- PINKERTON (H.), SMILEY (W.L.) and ANDERSON (W.A.D.), « Giant cell pneumonia with inclusions: a lesion common to Hechts disease, distemper and measles », *Amer. J. Pathol.*, 1945, **21**, 1, 1-24.
- ROWLAND (A.C.), SCOTT (G.R.) and HILL (D.H.), « The pathology of an erosive stomatitis and enteritis in West African dwarf goats », *J. Pathol.*, 1969, **98**, 1, 83-87.
- THIERY (G.), « Hematologie, histopathologie et histochimie de la peste bovine », *Rev. Elev. Méd. vét. Pays trop.*, 1956, **9**, 117-141.
- WHITNEY (J.C.), SCOTT (G.R.) and HILL (D.H.), « Preliminary observations on a stomatitis and enteritis of goats in southern Nigeria », *Bull. epizoot. Dis. Afr.*, 1967, **15**, 31-41.